NEUROPATOLOGÍA DE LA ESCLEROSIS LATERAL AMIOTRÓFICA: CUESTIONES PRÁCTICAS Y CRITERIOS DE CLASIFICACIÓN

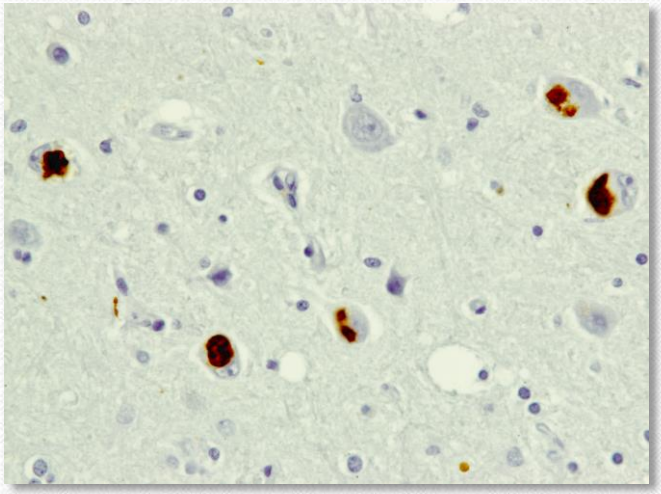

Alberto Rábano
Banco de Tejidos CIEN
Fundación CIEN, ISCIII

TODOS PODEMOS SER DONANTES DE TEJIDO CEREBRAL PARA INVESTIGACIÓN.

btcien

Banco de Tejidos de la Fundación Cien



TODOS PODEMOS SER DONANTES
DE TEJIDO CEREBRAL PARA INVESTIGACIÓN.

Banco de Tejidos CIEN
Unidad de Investigación Proyecto Alzheimer Fundación CIEN
Instituto de Salud Carlos III
C/ Valderrebollo 5. 28031 Madrid.
Tel: 91 385 22 00 Tel: 24H: 689037844 Fax: 91 385 21 18
www.bt.fundacioncien.es • e-mail: biobanco@fundacioncien.es

Donaciones: diagnósticos neuropatológicos

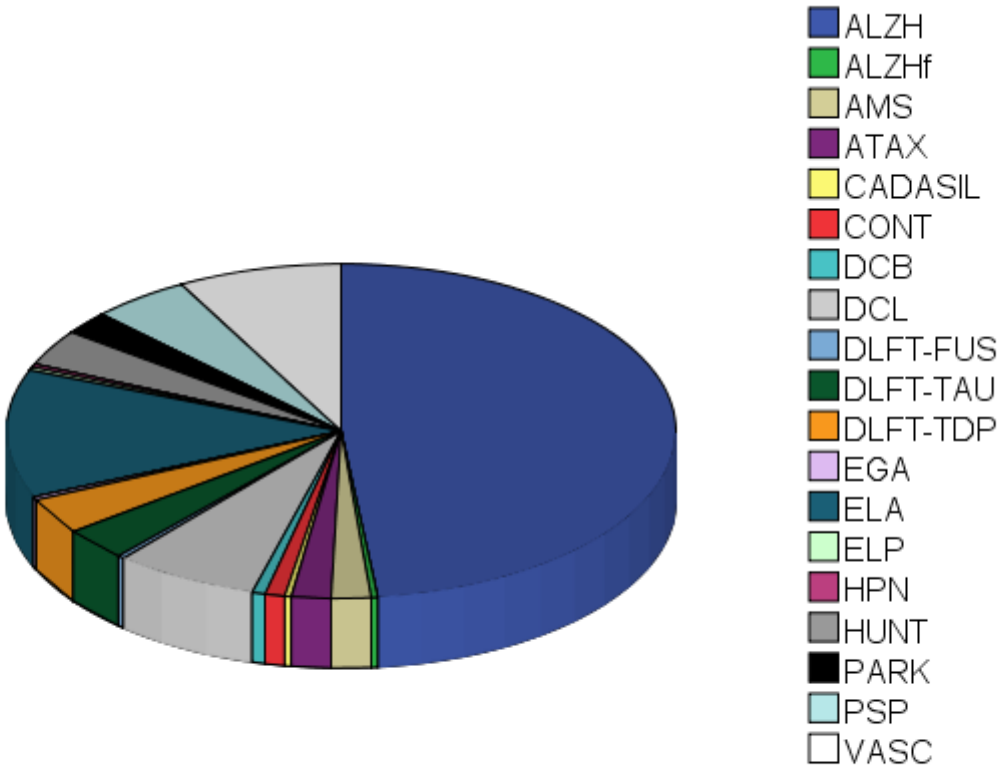

* Alzheimer
* D. cuerpos de Lewy
* Demencia fronto-temporal
* Esclerosis lateral amiotrófica
* Huntington
* Parkinson

Distribución anual de donaciones de tejido cerebral al BT-CIEN (2007 – 2016)

Donaciones internas (CAFRS)
Donaciones externas

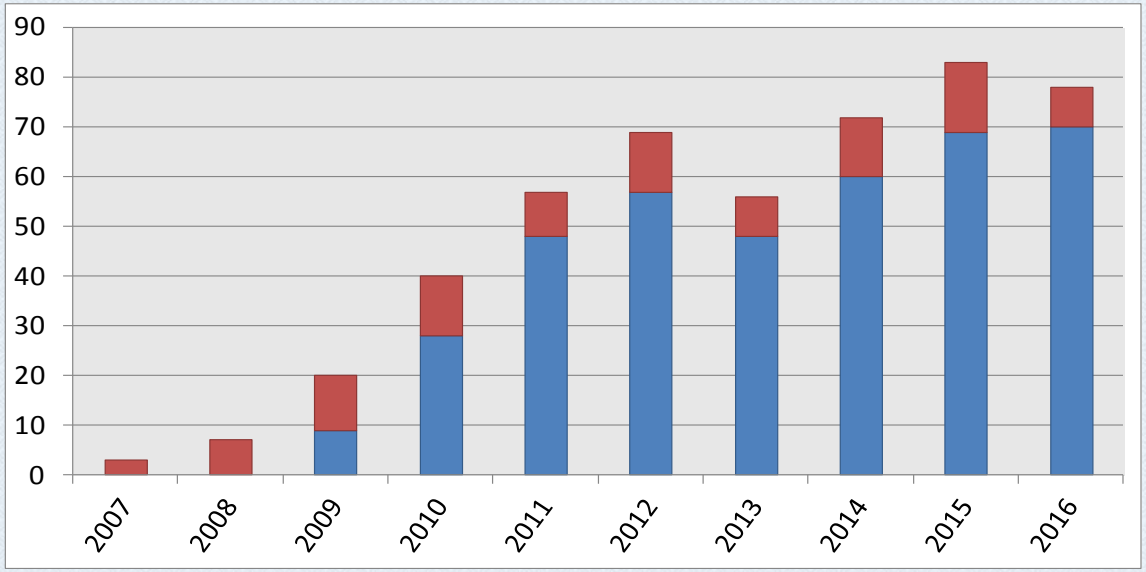

Donaciones de pacientes con ELA (2007 – 2016)

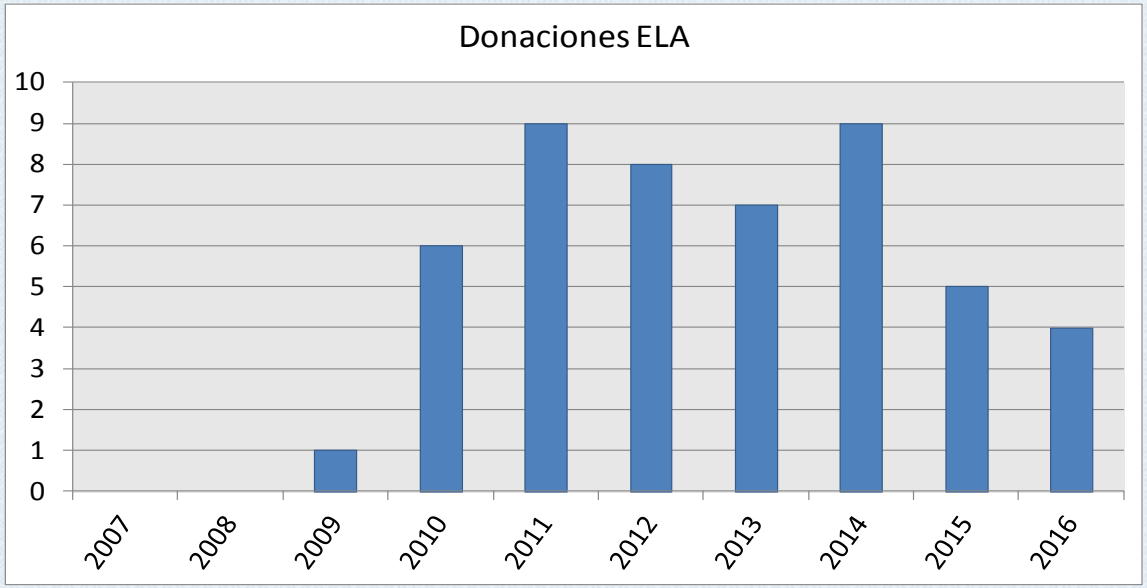

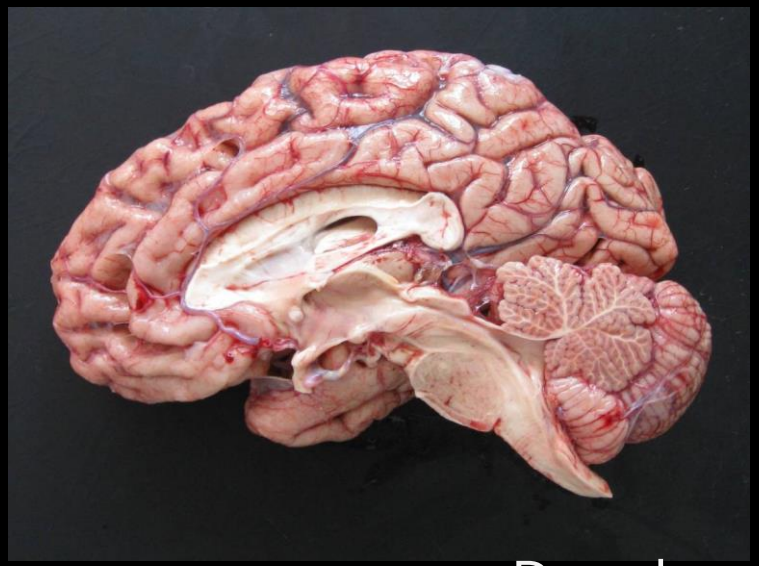

Derecho → Congelación

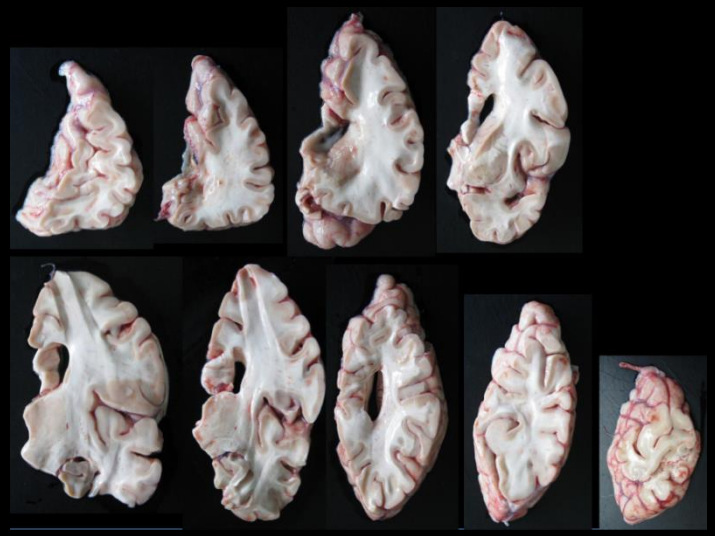

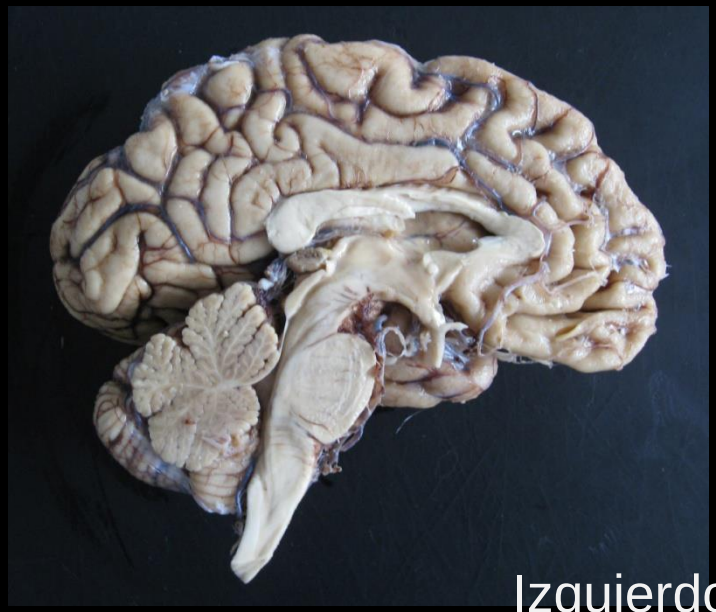

Izquierdo → Neuropatología

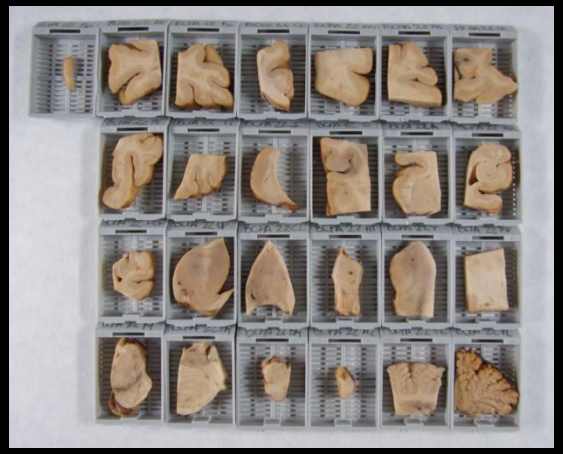

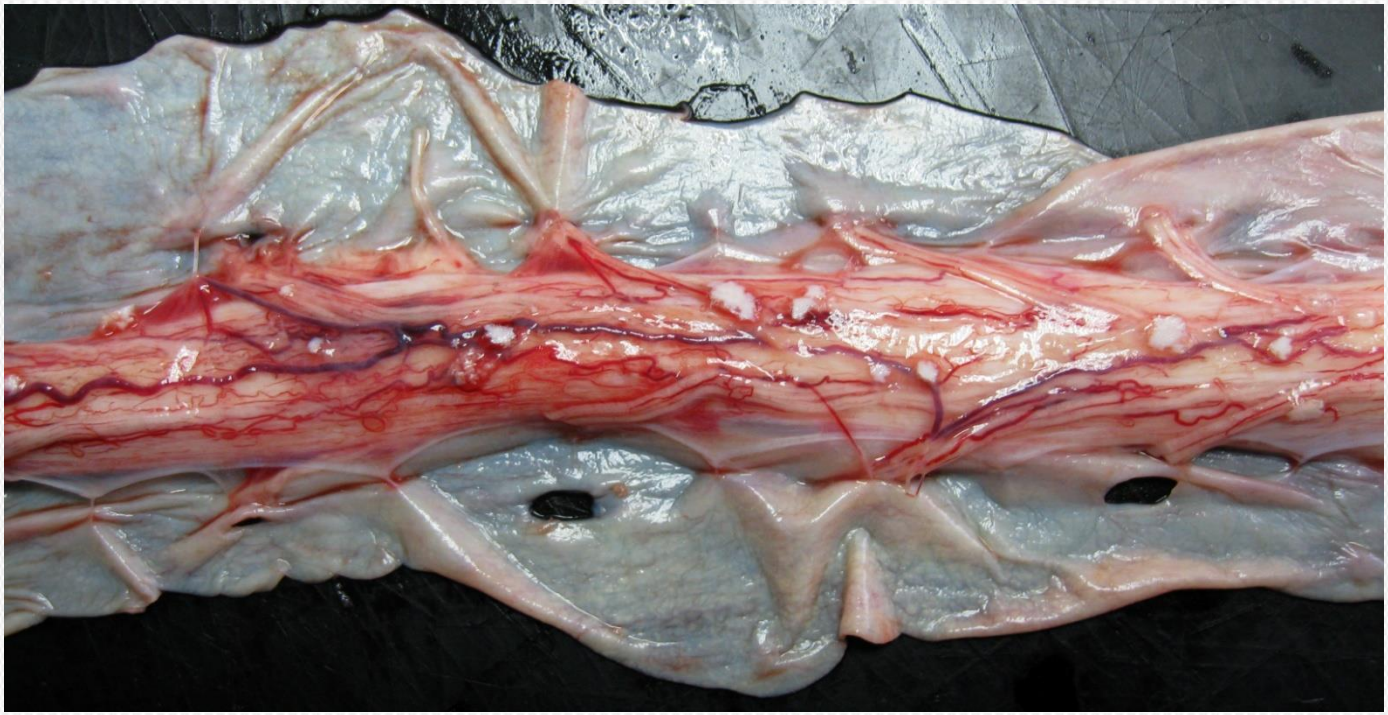

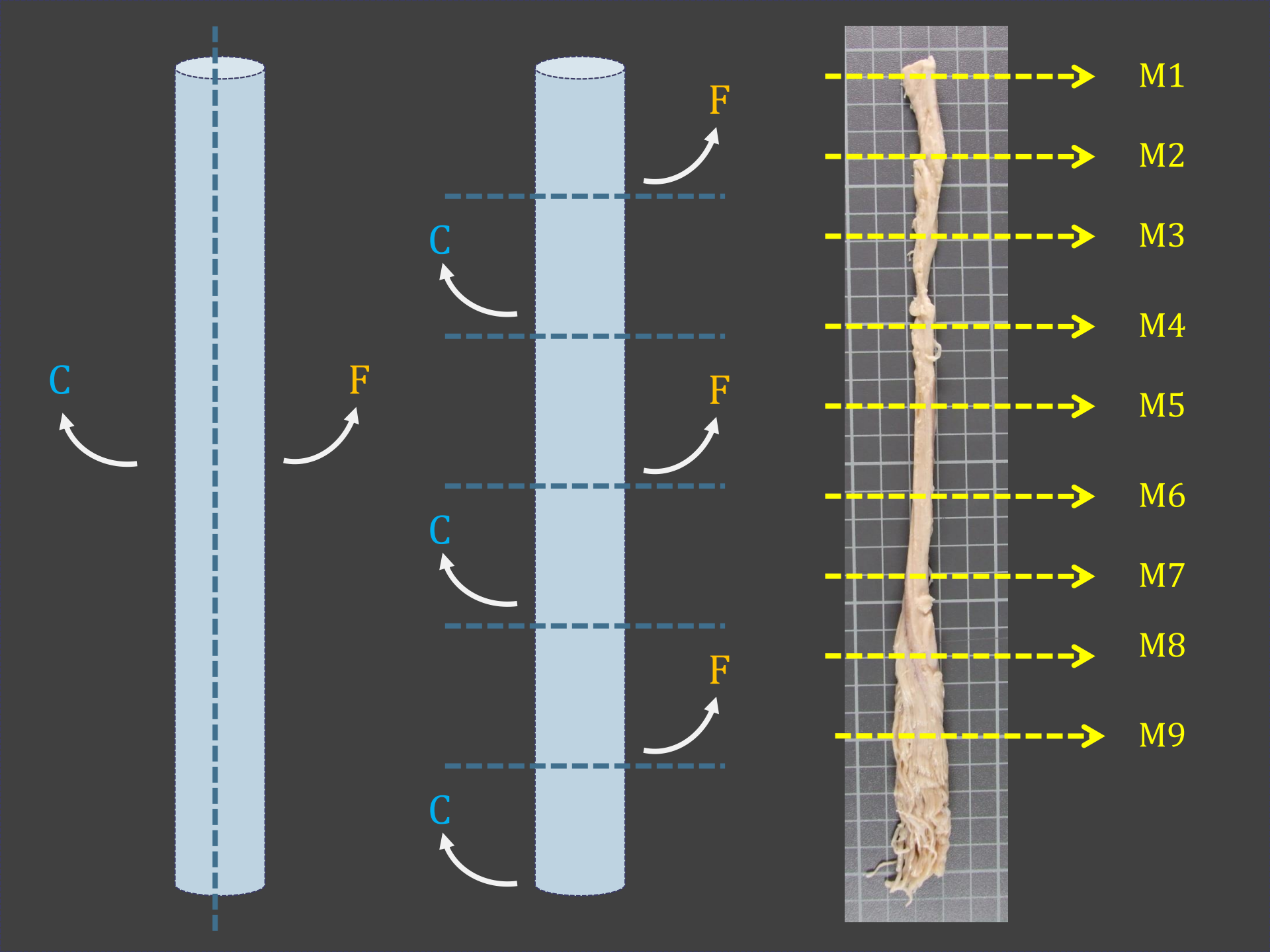
C
F
C
F
C
F
C
M1
M2
M3
M4
M5
M6
M7
M8
M9


Aβ
Tau
Aβ
Tau
A-sin
Ubiq
TDP-43
p62
Aβ
Tau
Tau
A-sin
Ubiq
TDP-43
p62
Ubiq
TDP-43
p62
Aβ
Aβ
Ubiq
A-sin
TDP-43
p62
Ubiq
TDP-43
p62
Aβ
p62

Hallazgos patológicos en enfermedades neurodegenerativas

	Positivos	Negativos	Reactivos
Específicos			
Inespecíficos			

Enfermedad esporádica

Enfermedad genética / familiar

Fenotipo NP

Genotipo

ELA

DLFT

GENETIC FORMS OF MOTOR NEURON DISEASE

A summary of the main genetic forms of MND is presented below.

Type of MND	Linkage	Gene
ALS1 AD adult	21q22	Cu/Zn SOD1 10–120% AD cases
ALS2 AR Juvenile	2q33	Alsin
ALS3 AD adult	18q21	Unknown – possibly commonest form of AD ALS
ALS4 AD Juvenile	9q34	*SETX* Senataxin
ALS5 AR Juvenile	15q15	*SPG11* Spatacsin
ALS6 AD Adult	16p11.2	*FUS* Fused in sarcoma
ALS7 AD Adult	20p13	Unknown
ALS8 AD Adult	20q13.33	*APB* VAMP-associated protein B
ALS9 AD Adult	14q11	*ANG* Angiogenin
ALS10 AD Adult	1q36	*TARDBP* TAR DNA-binding protein
ALS11 AD Adult	6q21	FIG4 PI(3,5)P(2)5-phosphatase
ALS12 AR/AD Adult	10p15-p14	*OPTN* Optineurin
ALS 15	p11.23-p11.1	*UBQLN2* gene
FTDALS	9p21	C9orf72 (GGGGCC)n expansion

AD, autosomal dominant; AR, autosomal recessive.

nature COMMUNICATIONS

ARTICLE

Received 10 Aug 2015 | Accepted 7 Mar 2016 | Published 15 Apr 2016

DOI: 10.1038/ncomms11253 OPEN

CCNF mutations in amyotrophic lateral sclerosis and frontotemporal dementia

Kelly L. Williams[1,2,3], Simon Topp[4], Shu Yang[1,2], Bradley Smith[4], Jennifer A. Fifita[1,2], Sadaf T. Warraich[1], Katharine Y. Zhang[1], Natalie Farrawell[5], Caroline Vance[4], Xun Hu[4], Alessandra Chesi[6], Claire S. Leblond[7,8], Albert Lee[1,9], Stephanie L. Rayner[1], Vinod Sundaramoorthy[1,10], Carol Dobson-Stone[11,12], Mark P. Molloy[1,9], Marka van Blitterswijk[13], Dennis W. Dickson[13], Ronald C. Petersen[14], Neill R. Graff-Radford[15], Bradley F. Boeve[14], Melissa E. Murray[13], Cyril Pottier[13], Emily Don[1], Claire Winnick[1], Emily P. McCann[1], Alison Hogan[1], Hussein Daoud[7,8], Annie Levert[7,8], Patrick A. Dion[7,8], Jun Mitsui[16], Hiroyuki Ishiura[16], Yuji Takahashi[16], Jun Goto[16], Jason Kost[17,18], Cinzia Gellera[19], Athina Soragia Gkazi[4], Jack Miller[4], Joanne Stockton[20], William S. Brooks[11], Karyn Boundy[21], Meraida Polak[22], José Luis Muñoz-Blanco[23], Jesús Esteban-Pérez[24,25], Alberto Rábano[26], Orla Hardiman[27], Karen E. Morrison[20,28,29], Nicola Ticozzi[30,31], Vincenzo Silani[30,31], Jacqueline de Belleroche[32], Jonathan D. Glass[22], John B.J. Kwok[11,12], Gilles J. Guillemin[1], Roger S. Chung[1], Shoji Tsuji[16,33], Robert H. Brown Jr[18], Alberto García-Redondo[24,25], Rosa Rademakers[13], John E. Landers[18], Aaron D. Gitler[6], Guy A. Rouleau[7,8], Nicholas J. Cole[1,3], Justin J. Yerbury[5], Julie D. Atkin[1,10], Christopher E. Shaw[4], Garth A. Nicholson[1,2,3,34] & Ian P. Blair[1,2]

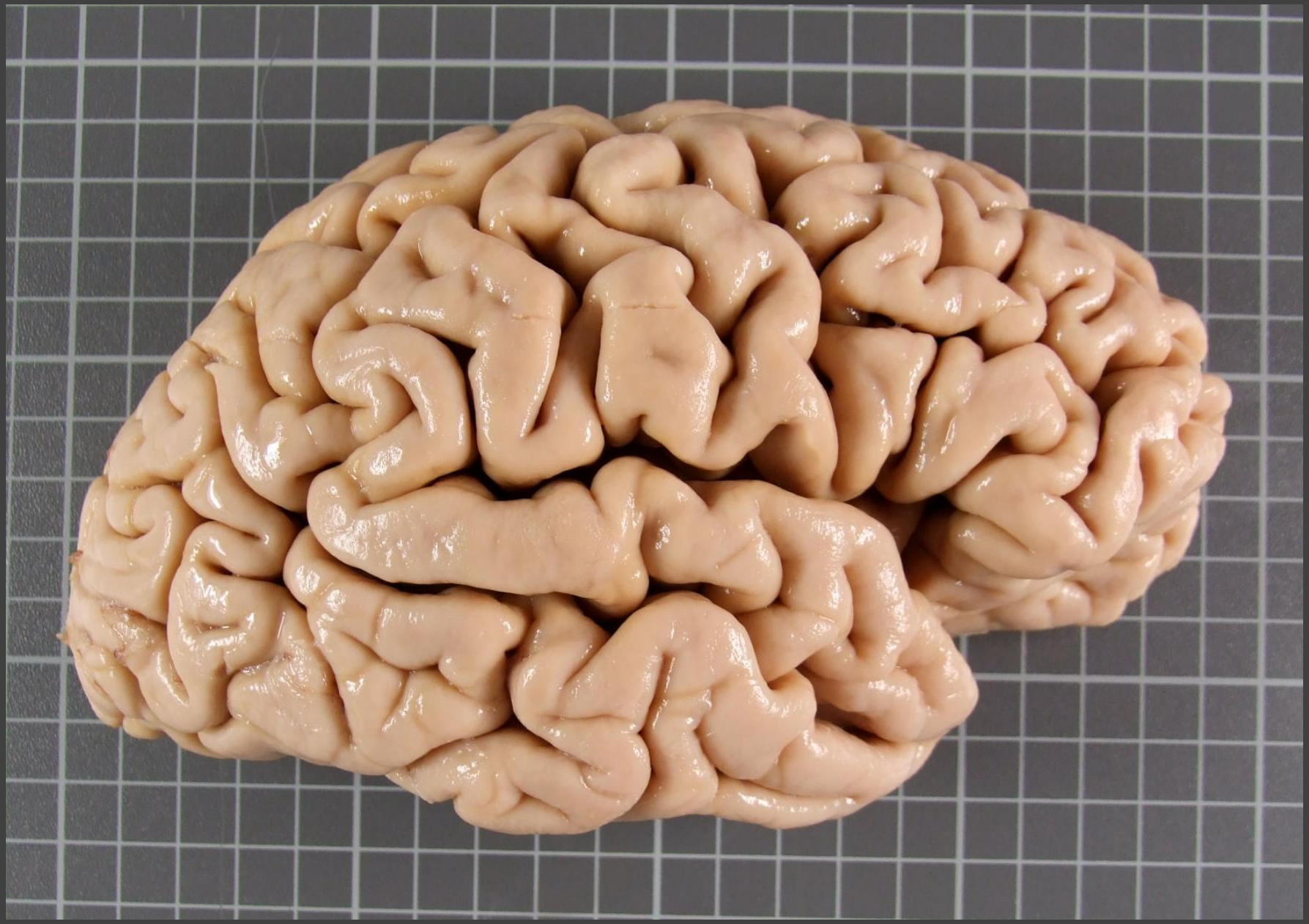

Bulbo
H/E

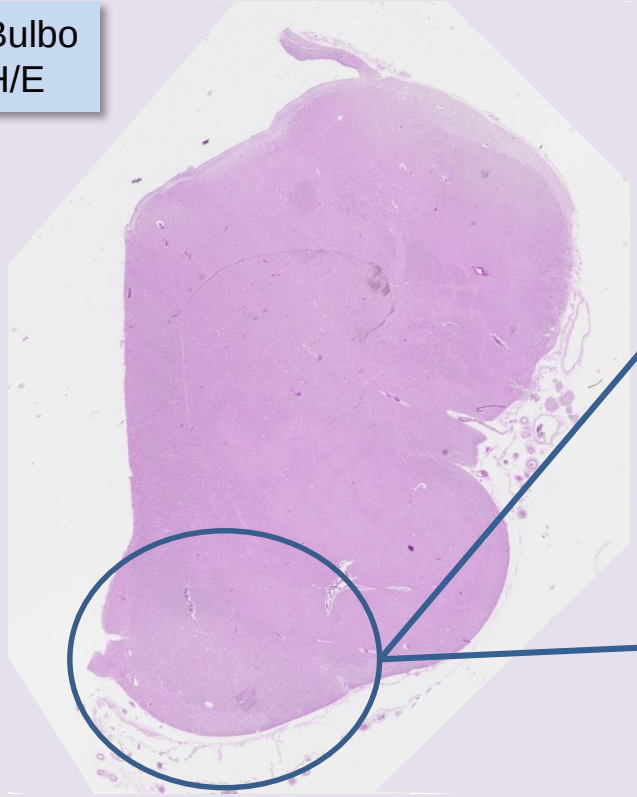

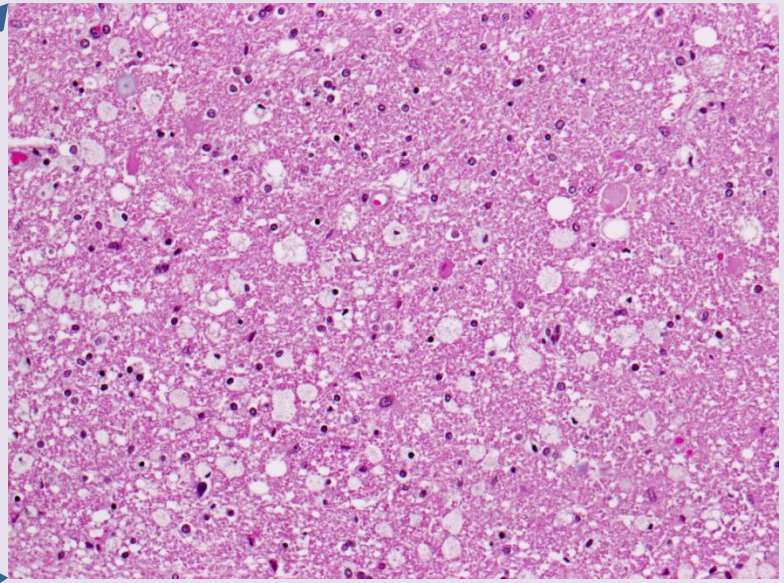

Médula
H/E

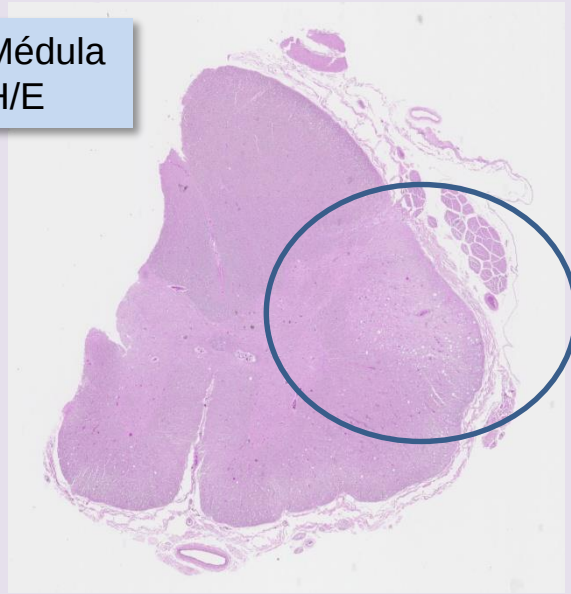

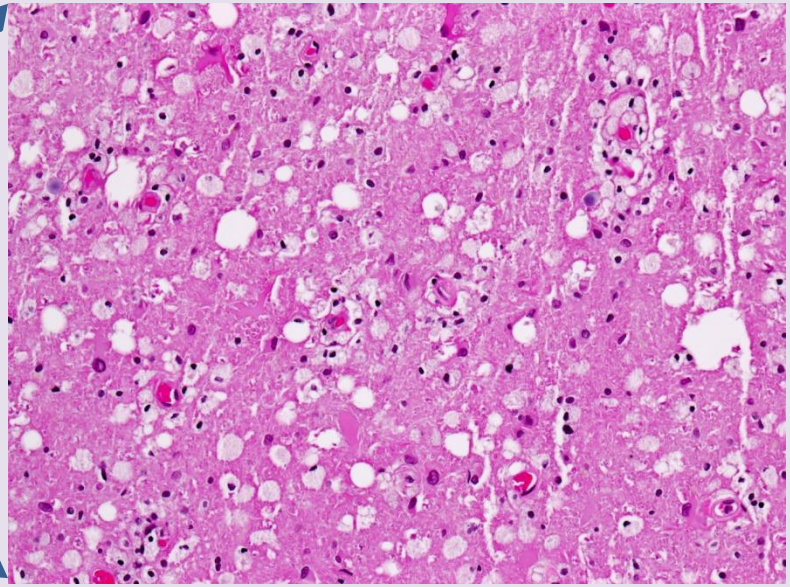

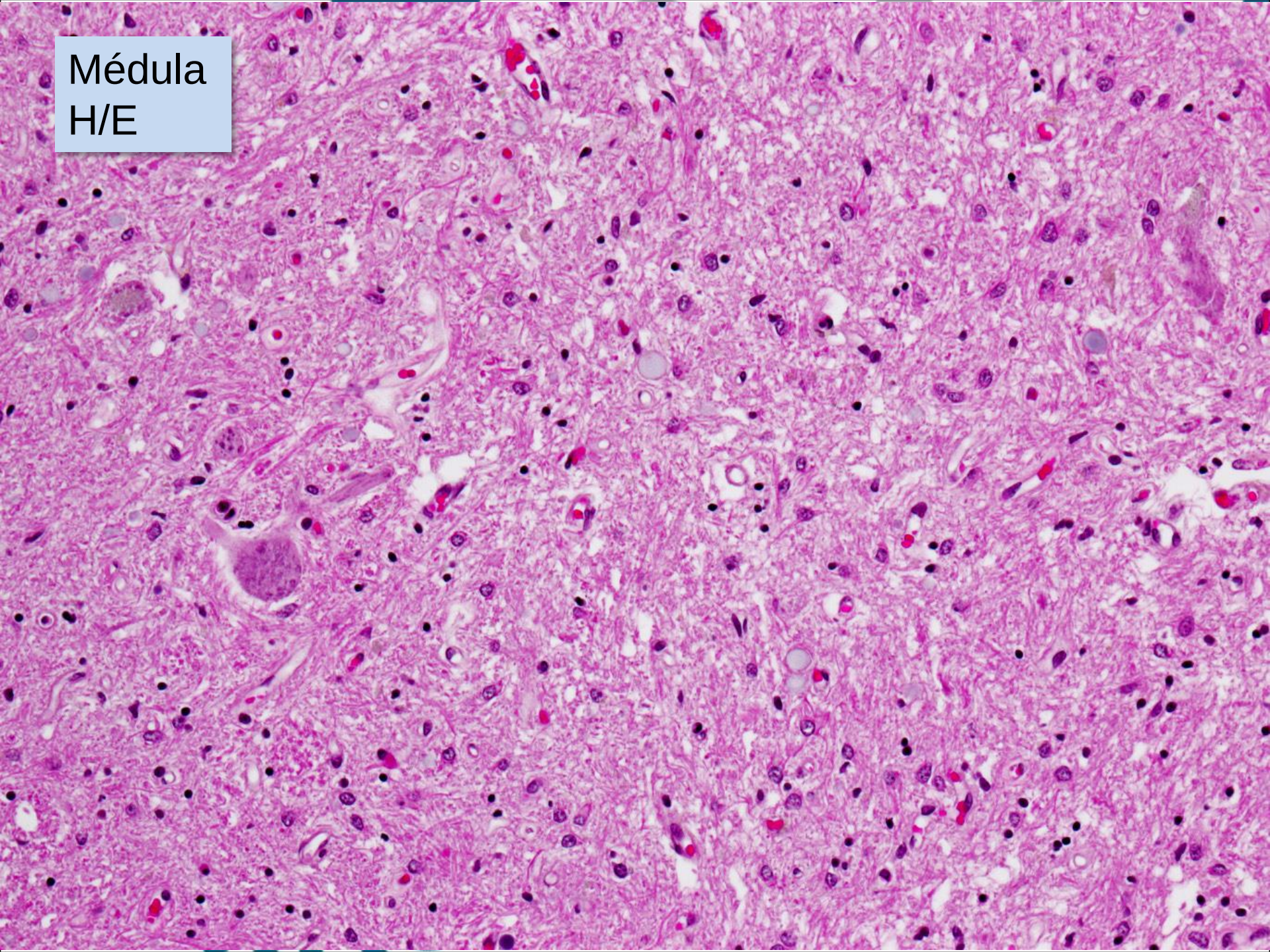
Médula
H/E

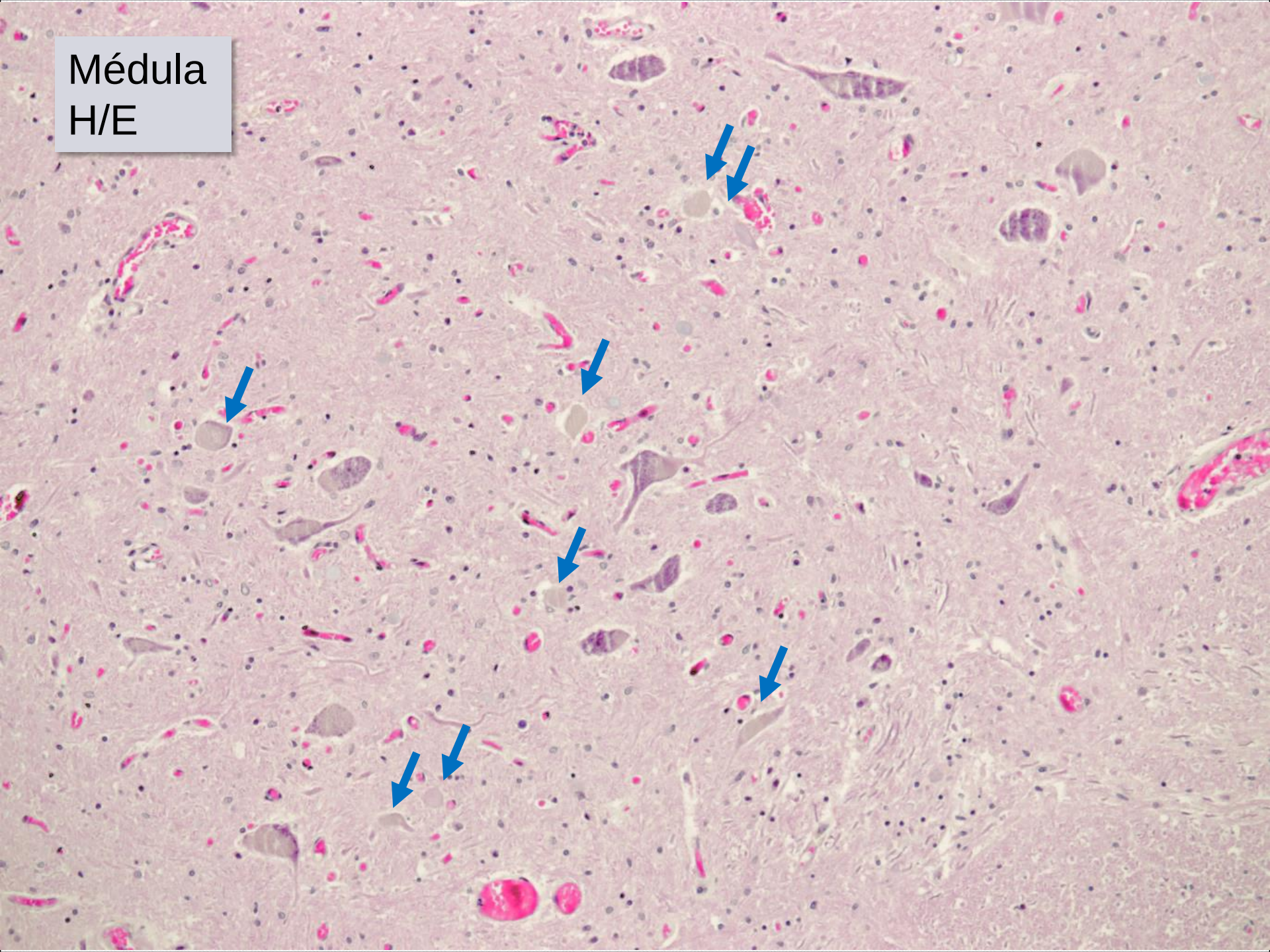
Médula
H/E

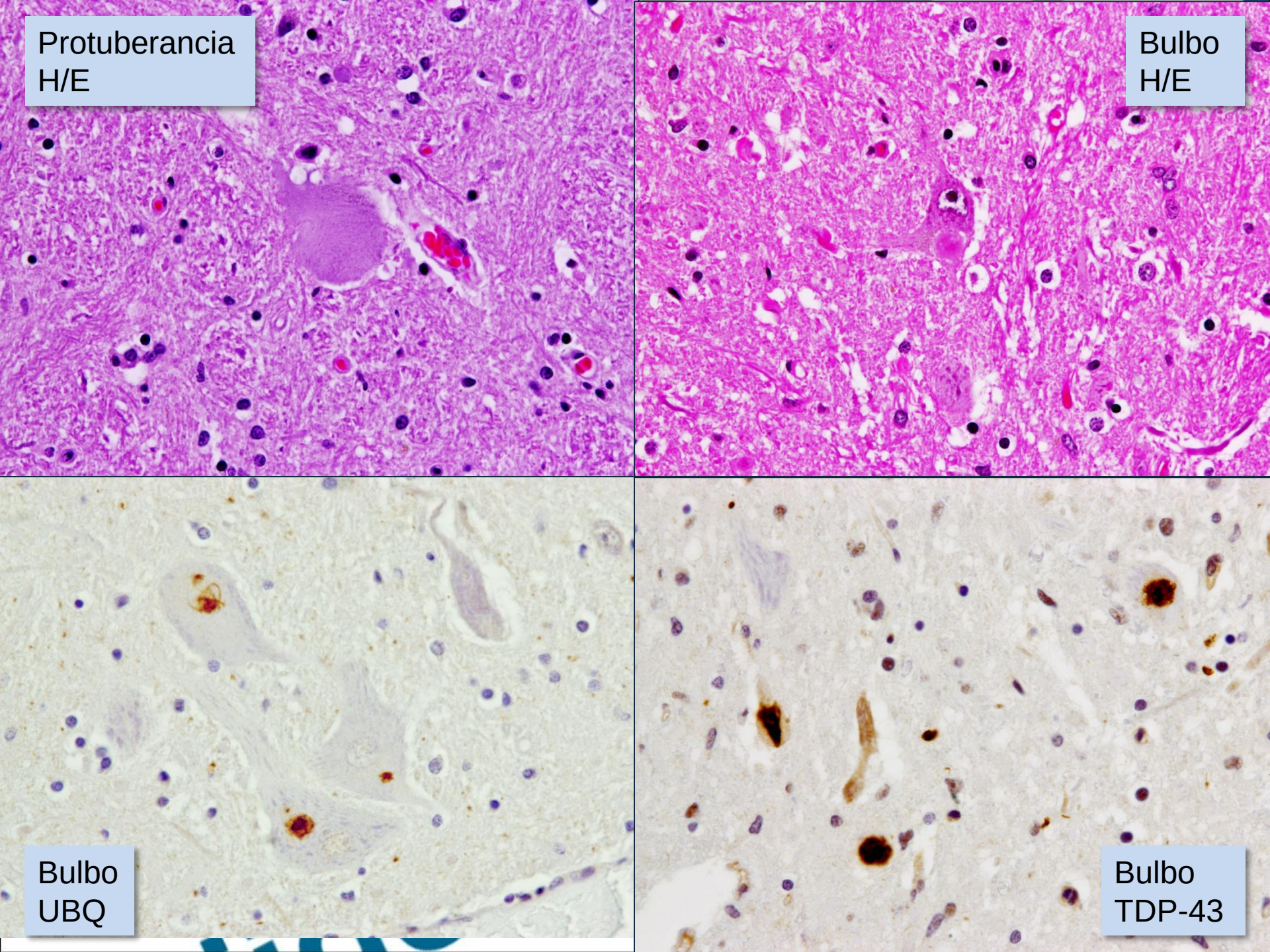
Protuberancia
H/E
Bulbo
H/E
Bulbo
UBQ
Bulbo
TDP-43

Inmunohx TDP-43

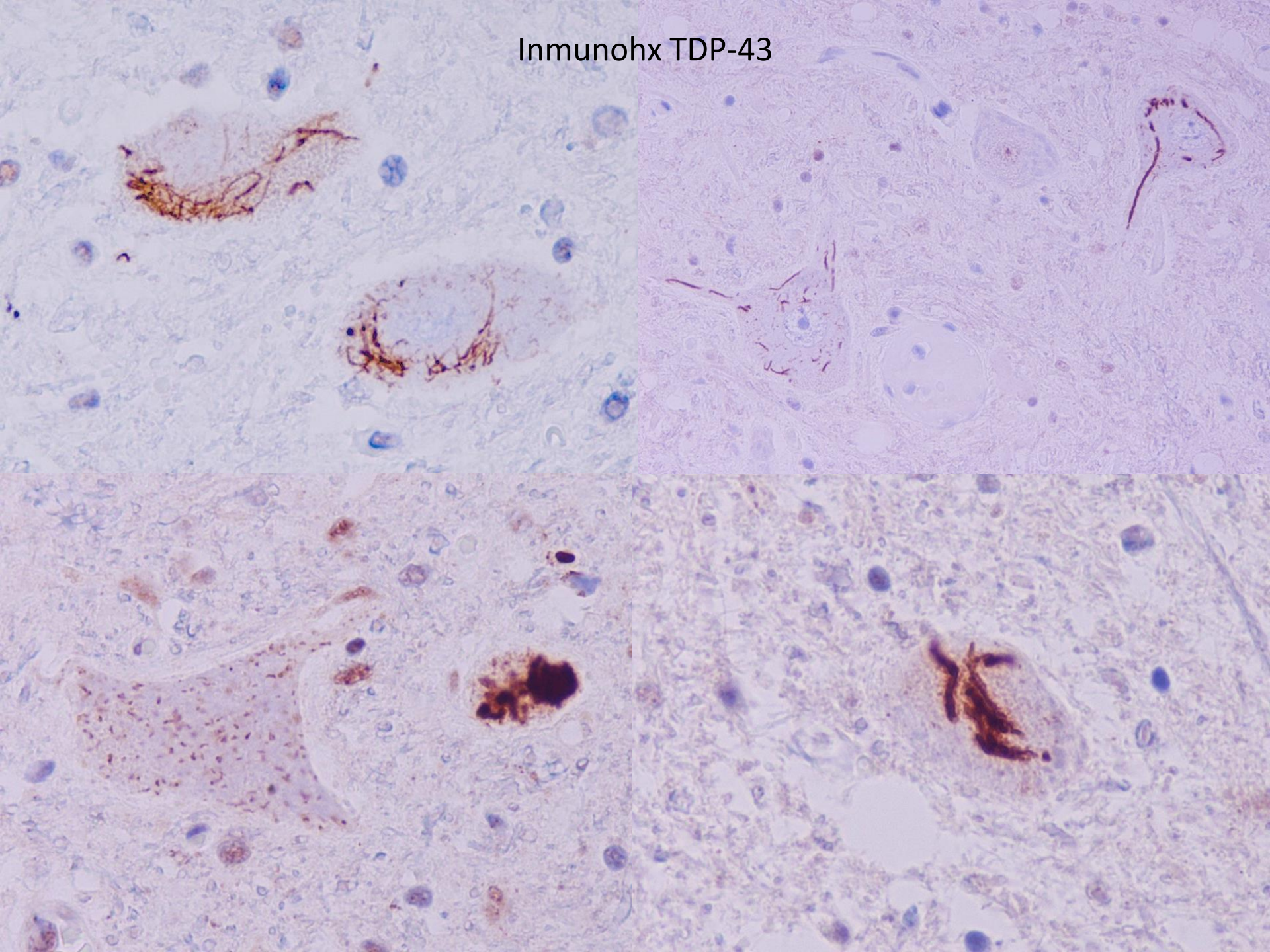

Córtex motor primario
Inmunohx TDP-43

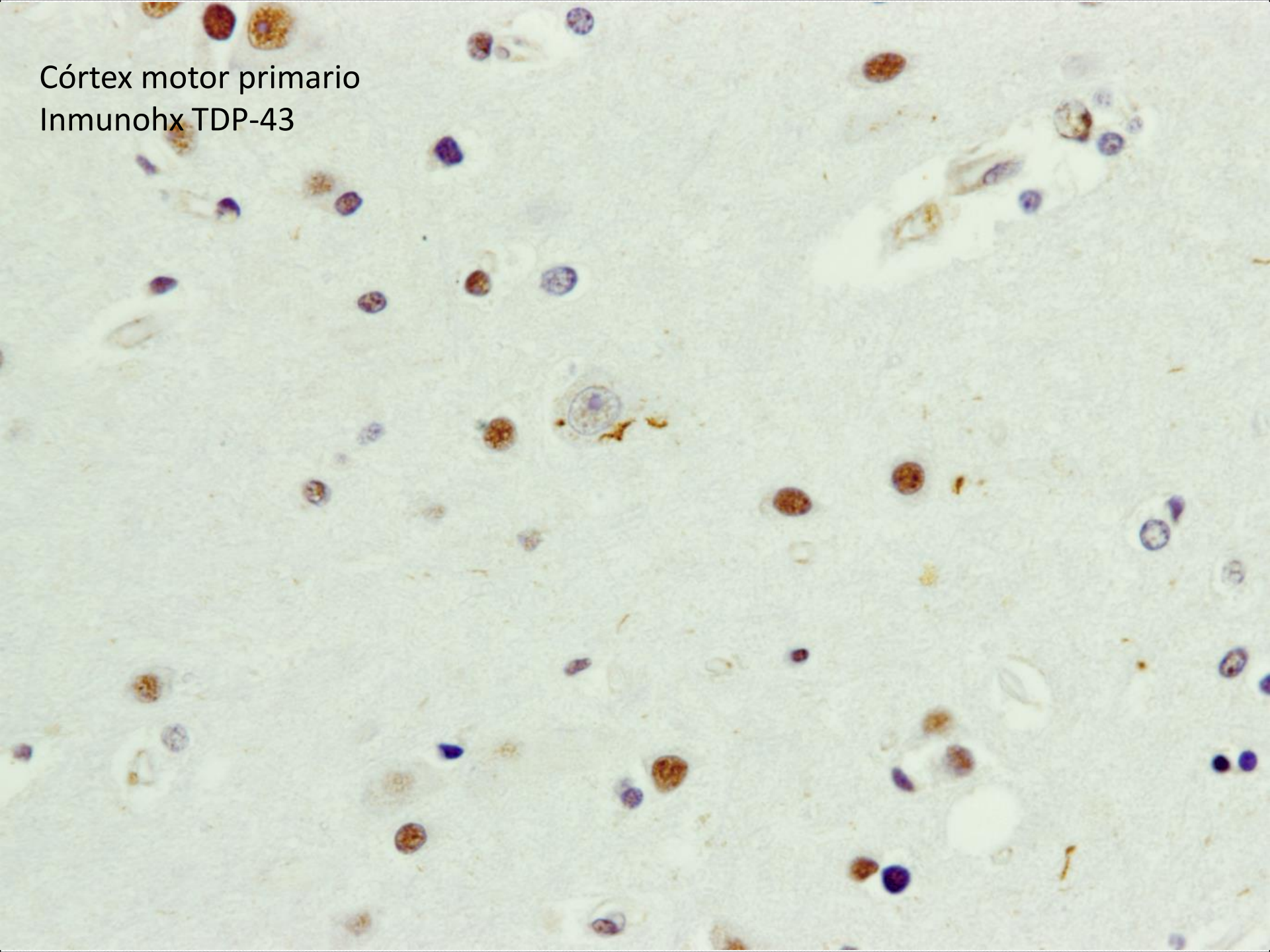

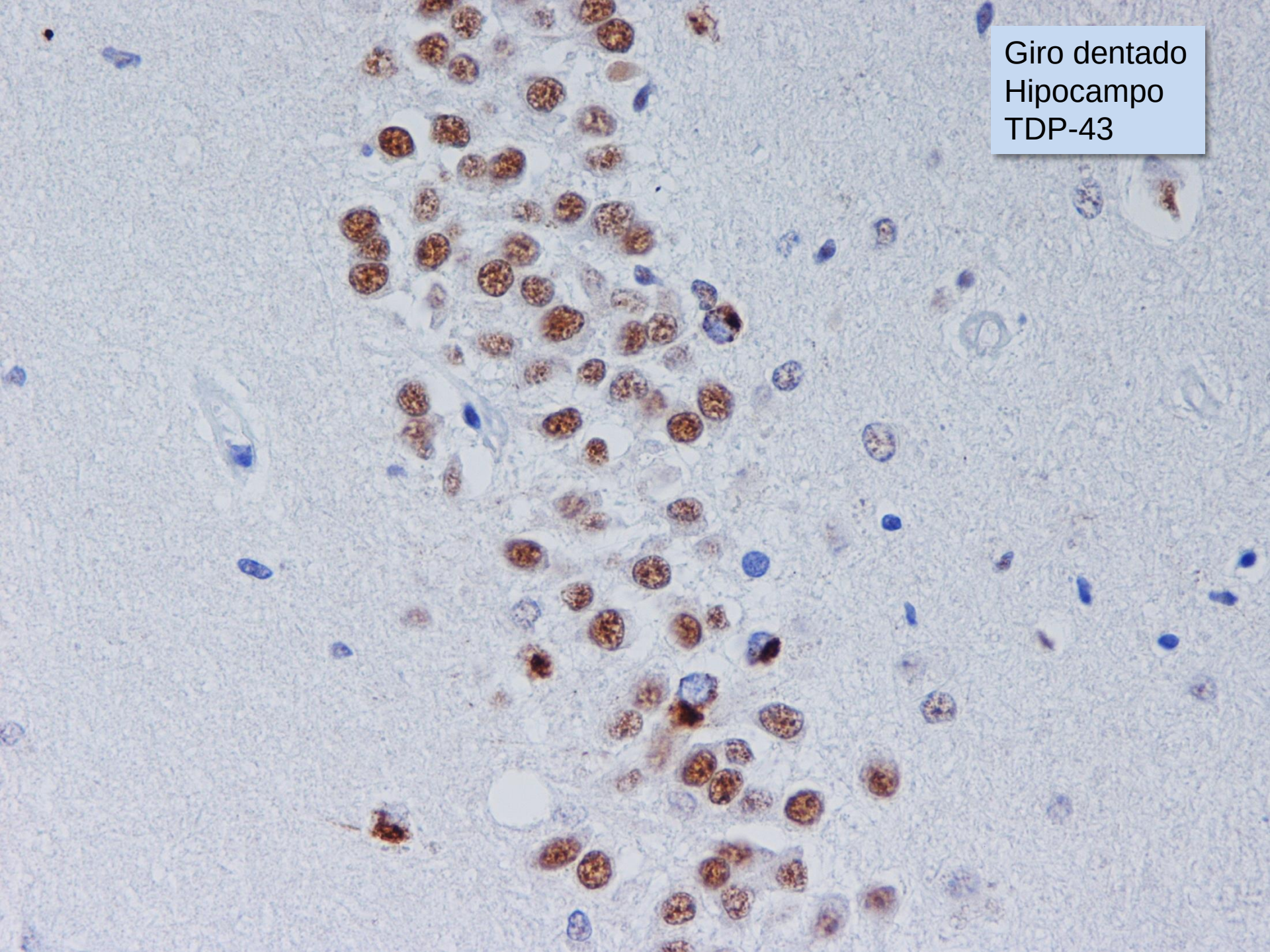
Giro dentado
Hipocampo
TDP-43

Table 3 Brettschneider J *et al.*, 2013

Tissue blocks and regions for staging of pTDP-43 pathology in ALS

Stage 1:	block 1: agranular motor neocortex – Brodmann areas 4, 6 block 2: medulla oblongata at the level of N. XII – bulbar somatomotor neurons of N. XII optional: spinal cord layer 9 – ventral horn α-motoneurons
Stage 2:	block 1 block 2: inferior olive, medullary reticular formation optional: parvocellular portion of the red nucleus
Stage 3:	blocks 1 and 2 block 3: prefrontal neocortex (e.g., gyrus rectus, orbital gyri) block 4: striatum optional: postcentral neocortex
Stage 4:	blocks 1-4 block 5: hippocampal formation, entorhinal region, adjoining temporal neocortex

Staging is based on a minimum of five tissue blocks, additional blocks, e.g., from the spinal cord or midbrain, are optional. When assigning stages, the extent (topographical distribution pattern) is accorded more weight than the degree (severity) of the pTDP-43 pathology in each region.

Tan RH *et al.*, 2015

Table 1 Comparison of the overlapping brain regions used in the different TDP-43 staging schemes

	Amyotrophic lateral sclerosis	Behavioural variant frontotemporal dementia	Alzheimer's disease
Number of stages	4	4	5
Amygdala	Stage 3	Stage 1	Stage 1
Orbital cortex, gyrus rectus	Stage 3	Stage 1	Not assessed
Inferior olive, parvocellular red nucleus	Stage 2	Stage 2	Not assessed
Entorhinal cortex	Stage 4	Stage 2	Stage 2
Hippocampal dentate gyrus	Stage 4	Stage 2	Stage 3
Inferior temporal cortex	Stage 4	Stage 2	Stage 4
Prefrontal cortex	Stage 3	Stage 2	Stage 5
Hypoglossal nucleus, motor cortex	Stage 1	Stage 3	Not assessed
Substantia nigra, locus coeruleus	Stage 2	Stage 4	Not assessed

Comparison is shown for amyotrophic lateral sclerosis (Brettschneider *et al.*, 2014), behavioural variant FTD (Brettschneider *et al.*, 2013) and Alzheimer's disease (Josephs *et al.*, 2014*a*), and the stage indicated (by increasing shading) if pathology is observed in the brain region.

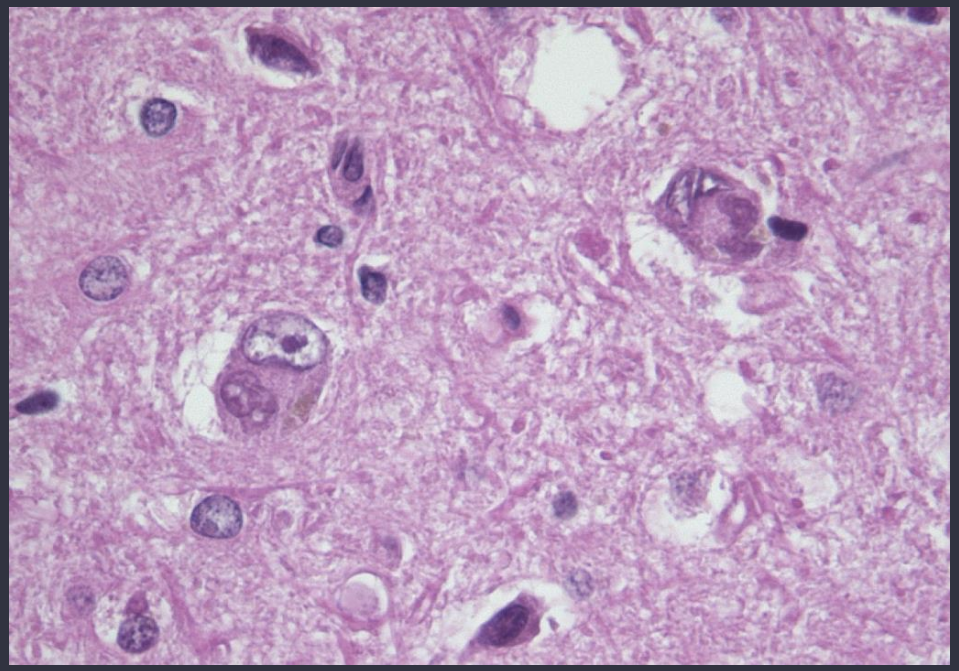

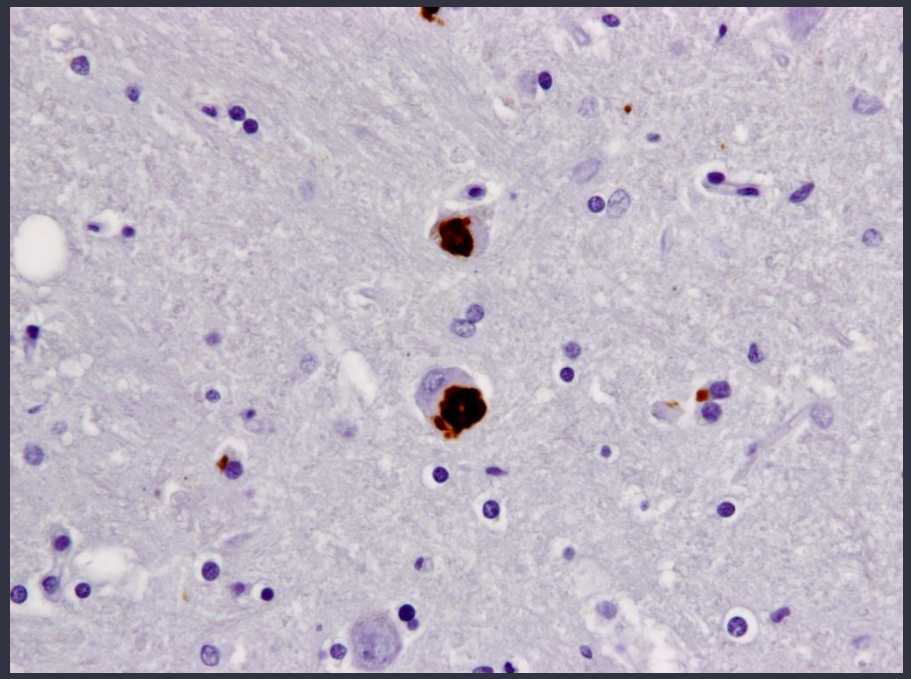

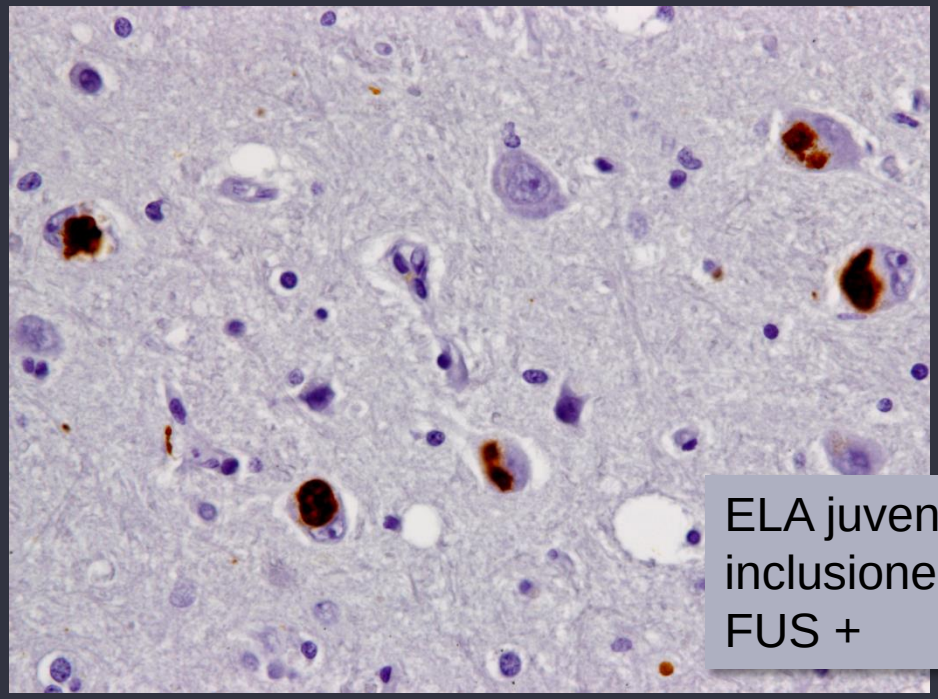

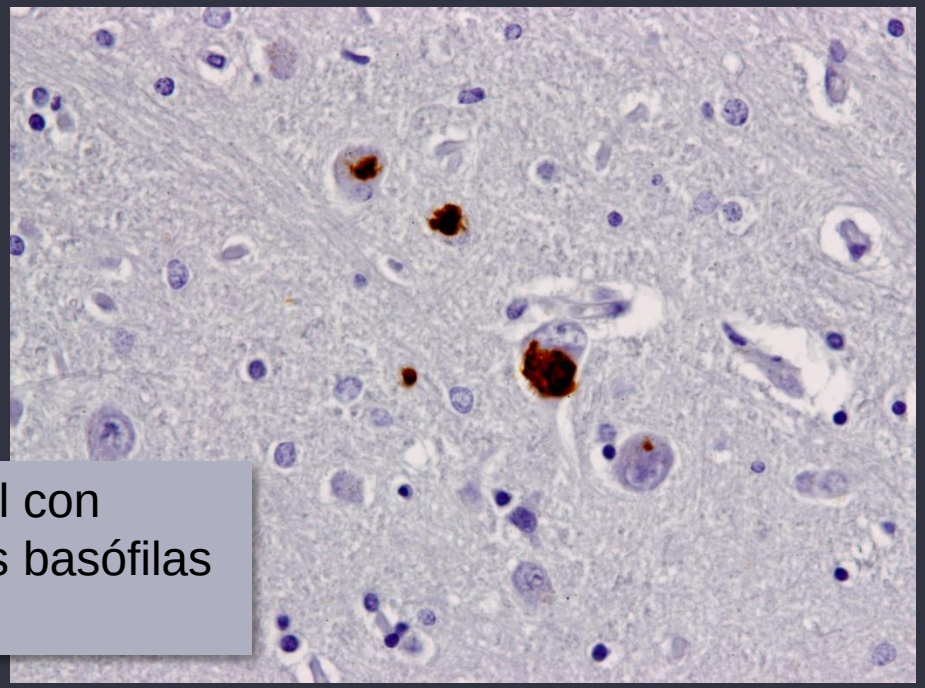

ELA juvenil con inclusiones basófilas FUS +

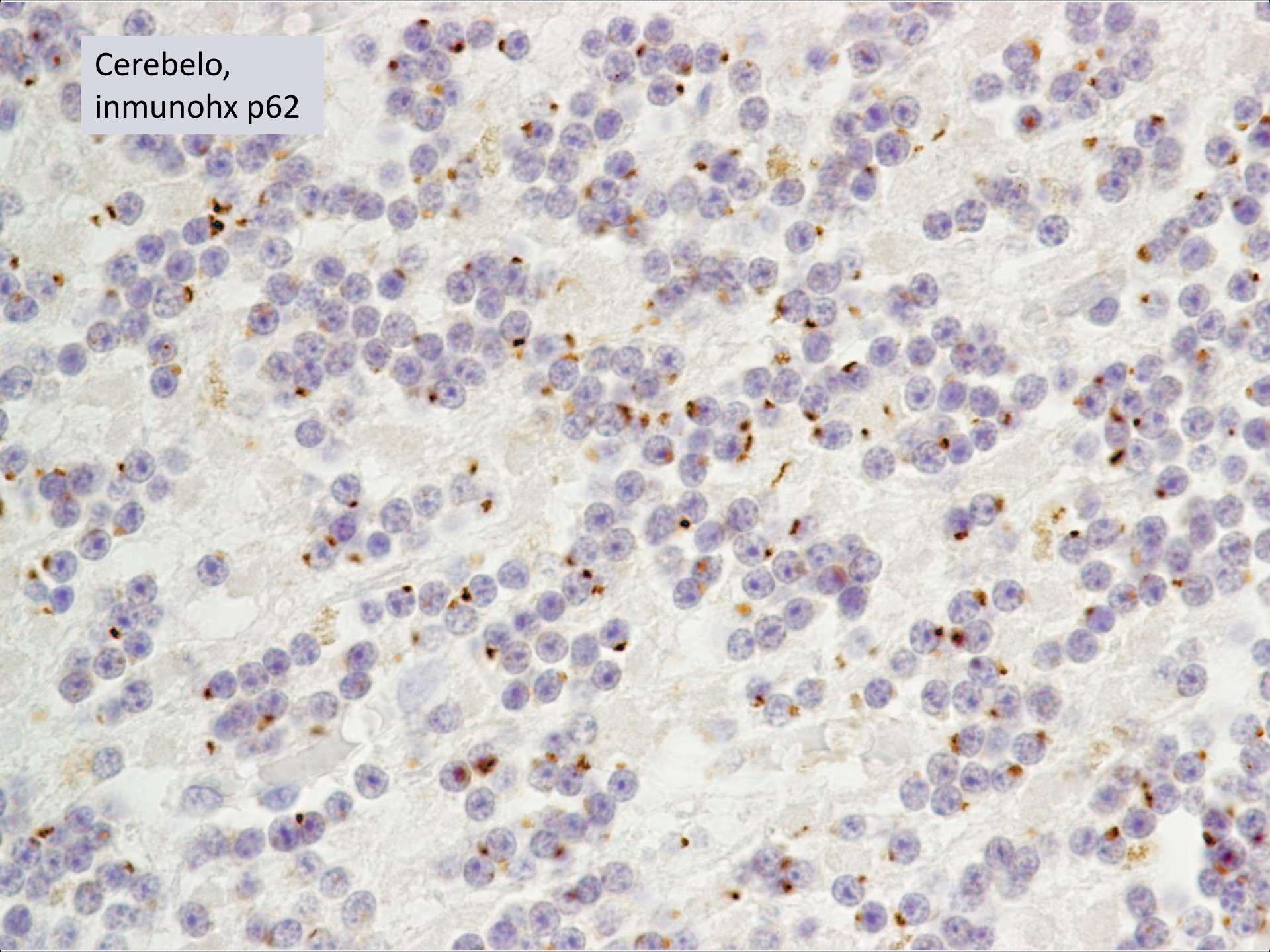
Cerebelo,
inmunohx p62

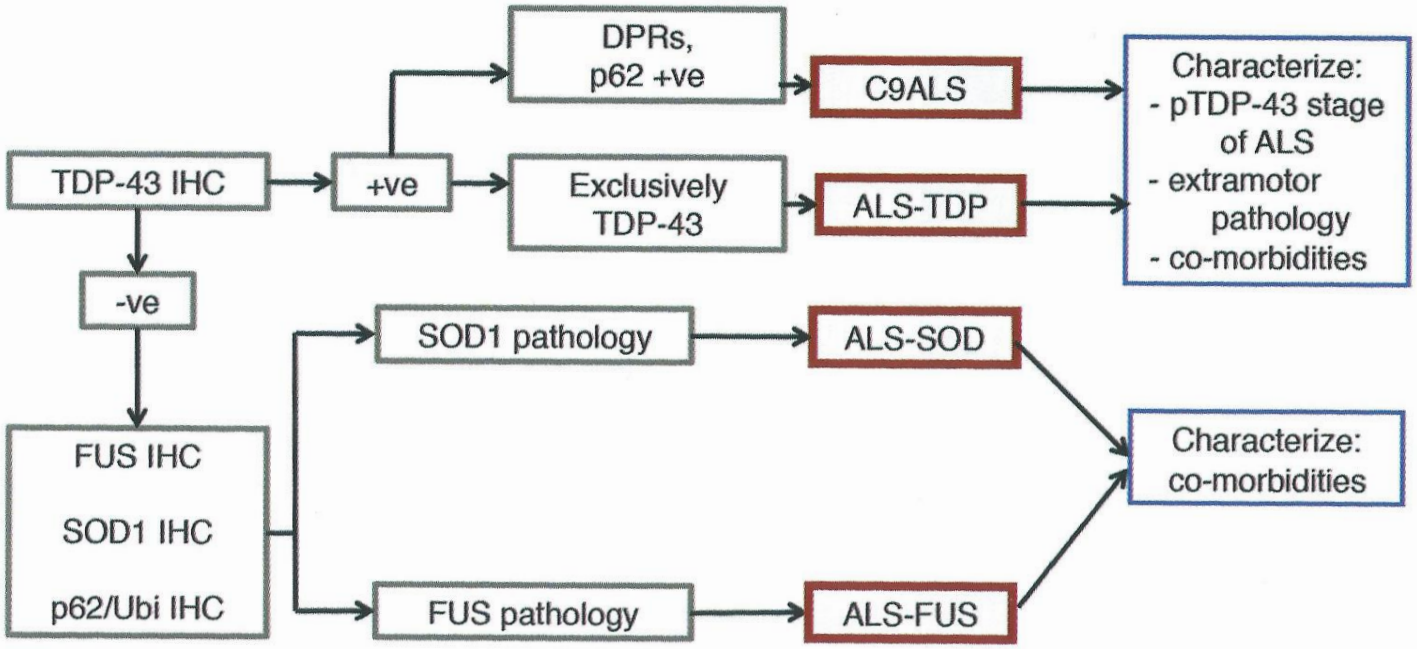

Figure 12.6 Algorithm for evaluating amyotrophic lateral sclerosis (ALS). The first step is to determine whether the case is a TDP-43 proteinopathy (the most frequent phenotype) or not. ALS-TDP and ALS with *C9orf72* expansion may be differentiated by p62 IHC and further verified by immunohistochemical detection of dipeptide repeats (DPRs) in the latter. TDP-43-negative cases can be subdivided into ALS-*SOD1* and ALS-FUS by using FUS and/or SOD1 IHC. Although cases classified as TDP-43-negative may contain weak and sparse nuclear TDP-43 labeling, it is not the hallmark pathological protein. Red boxes indicate ALS type and blue boxes indicate further characterization of the case. IHC, immunohistochemistry; pTDP-43, phosphorylated TDP-43; Ubi, ubiquitin.

Hortobágy T and Cairns N, 2015

IVYSPRING INTERNATIONAL PUBLISHER

International Journal of Biological Sciences

2015; 11(5): 546-558. doi: 10.7150/ijbs.11084

Research Paper

Evidence for Fungal Infection in Cerebrospinal Fluid and Brain Tissue from Patients with Amyotrophic Lateral Sclerosis

Ruth Alonso[1], Diana Pisa[1], Ana Isabel Marina[1], Esperanza Morato[1], Alberto Rábano[2], Izaskun Rodal[2] and Luis Carrasco[1]✉

1. Centro de Biología Molecular "Severo Ochoa". c/Nicolás Cabrera, 1. Universidad Autónoma de Madrid. Cantoblanco. 28049 Madrid. Spain.
2. Department of Neuropathology and Tissue Bank, Unidad de Investigación Proyecto Alzheimer, Fundación CIEN, Instituto de Salud Carlos III, Madrid. Spain.

Unidad de Cultura Científica

La ELA podría estar provocada por hongos

30/04/2015

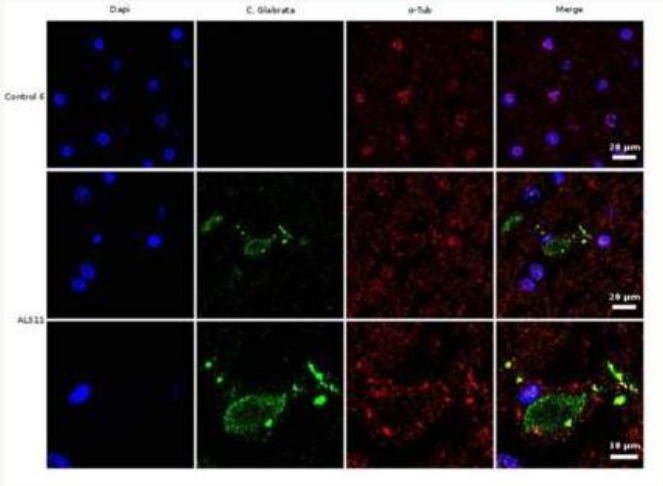

1 2

Científicos españoles han descrito la posible etiología de la esclerosis lateral amiotrófica (ELA). Proponen que la causa de esta enfermedad se debe a la infección con especies de hongos. El mismo equipo ha presentado evidencias que vinculan las infecciones fúngicas con otras enfermedades neurodegenerativas.

El grupo de investigación que lidera Luis Carrasco en el Centro de Biología Molecular Severo Ochoa (CBMSO), centro mixto

frontiers in Neuroscience

ORIGINAL RESEARCH
published: 08 March 2016
doi: 10.3389/fnins.2016.00086

Corpora Amylacea of Brain Tissue from Neurodegenerative Diseases Are Stained with Specific Antifungal Antibodies

*Diana Pisa[1], Ruth Alonso[1], Alberto Rábano[2] and Luis Carrasco[1]**

[1] Centro de Biología Molecular "Severo Ochoa," Universidad Autónoma de Madrid, Madrid, Spain, [2] Department of Neuropathology and Tissue Bank, Unidad de Investigación Proyecto Alzheimer, Fundación Centro de Investigación de Enfermedades Neurologicas, Instituto de Salud Carlos III, Madrid, Spain

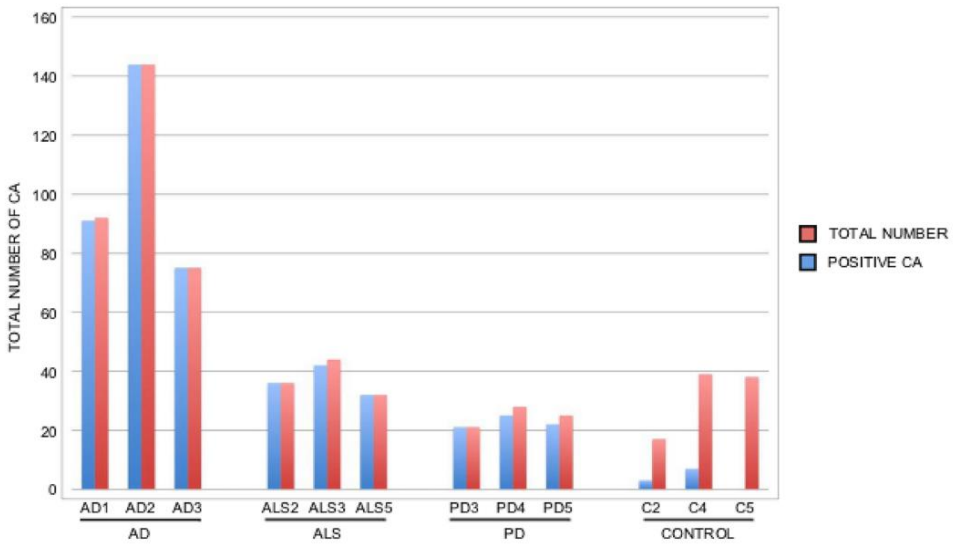

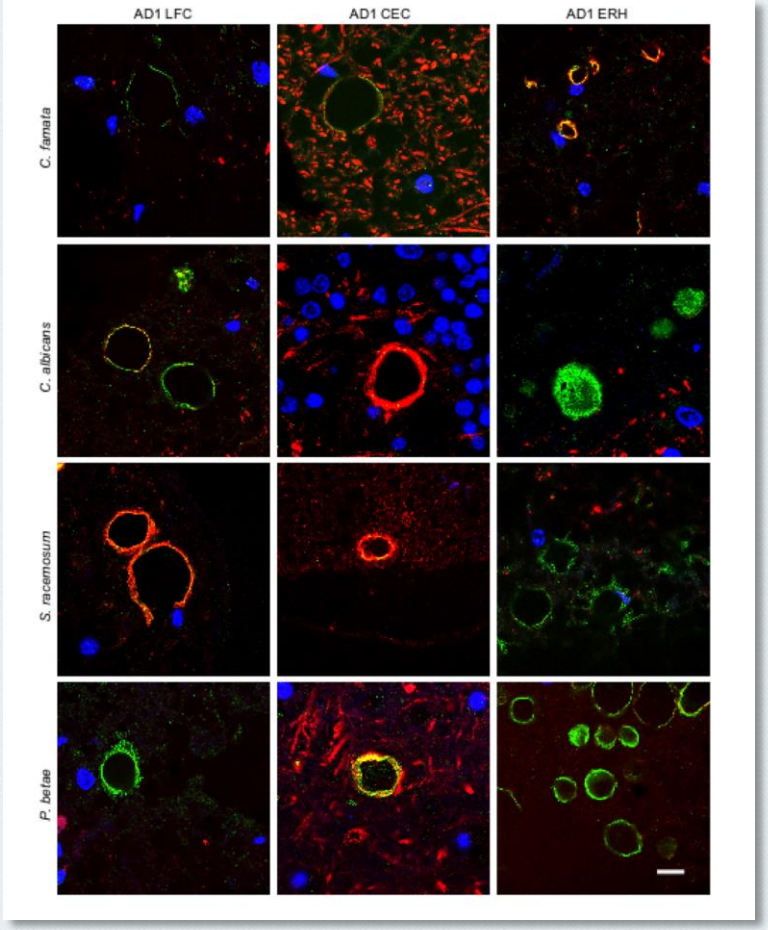

btcien
Banco de Tejidos de la Fundación Cien

¡Gracias!

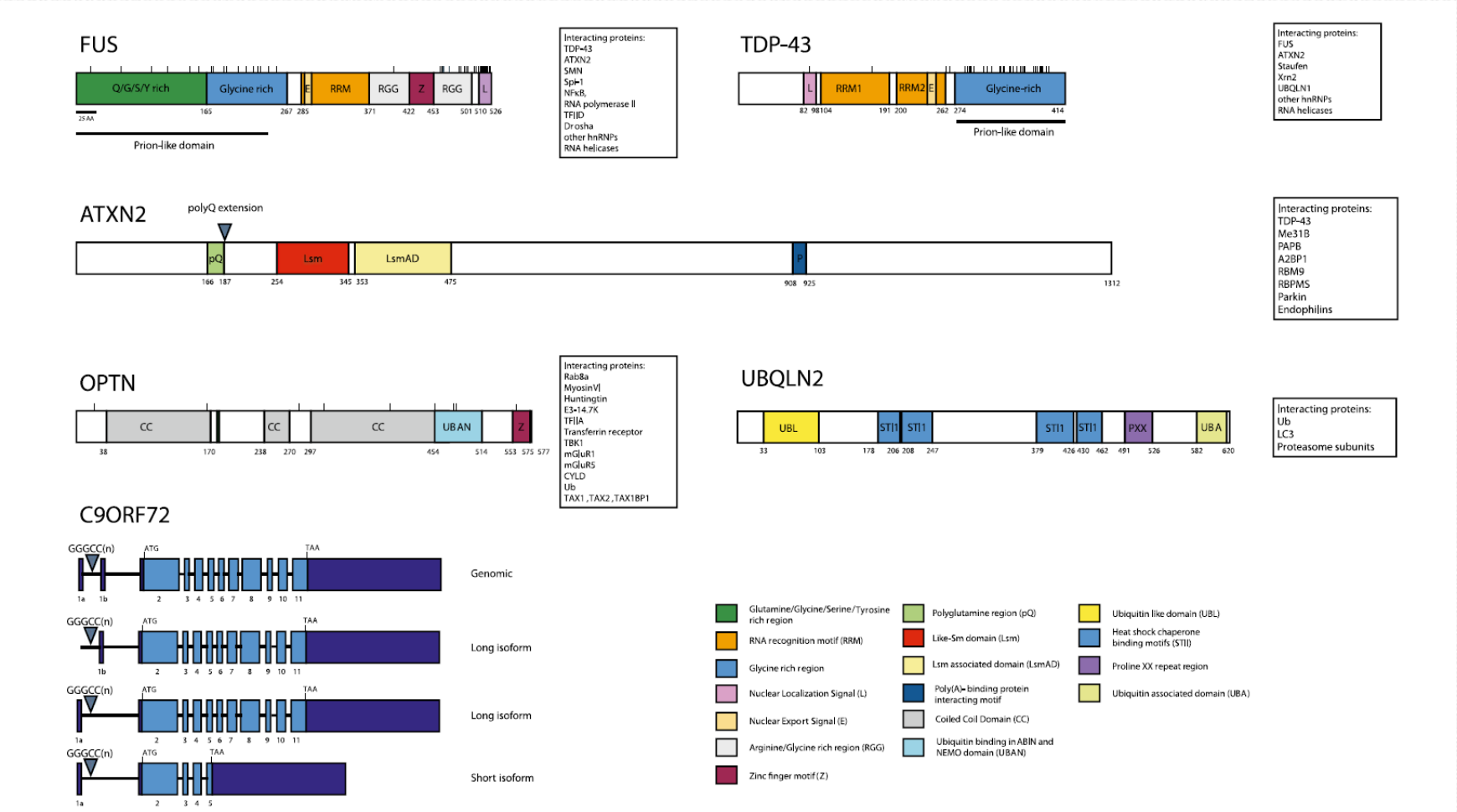

Blockhuis AM et al, 2013