MINISTERIO DE ECONOMÍA, INDUSTRIA Y COMPETITIVIDAD

Instituto de Salud Carlos III

FUNDACIÓN REINA SOFÍA

btcien Banco de Tejidos de la Fundación Cien

Actualización de la neuropatología de la degeneración lobar frontotemporal

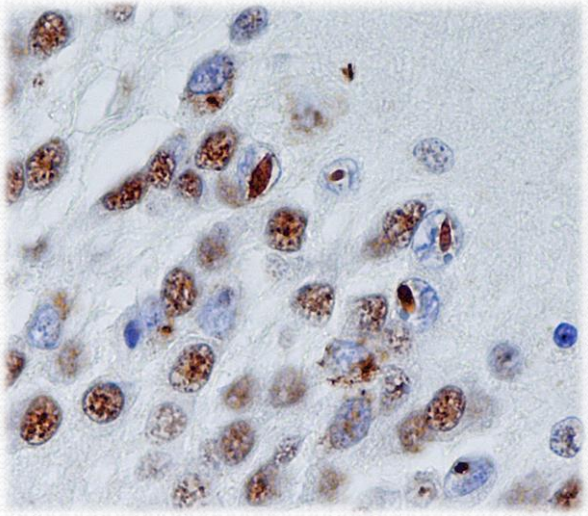

Alberto Rábano

Neuropatología y Banco de Tejidos
Fundación CIEN, ISCIII

REPORTS

6 OCTOBER 2006 VOL 314 SCIENCE

Ubiquitinated TDP-43 in Frontotemporal Lobar Degeneration and Amyotrophic Lateral Sclerosis

Manuela Neumann,[1,11]* Deepak M. Sampathu,[1]* Linda K. Kwong,[1]* Adam C. Truax,[1] Matthew C. Micsenyi,[1] Thomas T. Chou,[2] Jennifer Bruce,[1] Theresa Schuck,[1] Murray Grossman,[3,4] Christopher M. Clark,[3,4] Leo F. McCluskey,[3] Bruce L. Miller,[6] Eliezer Masliah,[7] Ian R. Mackenzie,[8] Howard Feldman,[9] Wolfgang Feiden,[10] Hans A. Kretzschmar,[11] John Q. Trojanowski,[1,4,5] Virginia M.-Y. Lee[1,4,5]†

doi:10.1093/brain/awp214 Brain 2009: 132; 2922–2931 | 2922

BRAIN
A JOURNAL OF NEUROLOGY

A new subtype of frontotemporal lobar degeneration with FUS pathology

Manuela Neumann,[1] Rosa Rademakers,[2] Sigrun Roeber,[3] Matt Baker,[2] Hans A. Kretzschmar[3] and Ian R. A. Mackenzie[4]

Mackenzie IRA *et al*. **Nomenclature for neuropathologic subtypes of frontotemporal lobar degeneration: consensus recommendations.** Acta Neuropathol. 2009 January ; 117(1): 15–18.

1. FTLD should be retained as the general terminology for pathological conditions that are commonly associated with the clinical entities of FTD, PNFA and/or SD, and in which degeneration of the frontal and temporal lobes is a characteristic feature. It is recognized, however, that other anatomical regions (especially the parietal lobes and striatonigral system) may also be involved in some of these cases.
2. Major subdivisions should be designated by the protein abnormality that is presumed to be pathogenic or most characteristic of the condition (i.e. FTLD-protein) (Table 1).
3. When a new entity is discovered or when the molecular identity of the major pathological factor in an existing group is clarified, the appropriate term will be FTLD-pathological molecule.
4. Whenever possible, cases should be further sub-classified, using current terminology, to define the specific pattern of pathology [i.e. FTLD-tau (CBD) or FTLD-TDP (type 2)] (Table 1).

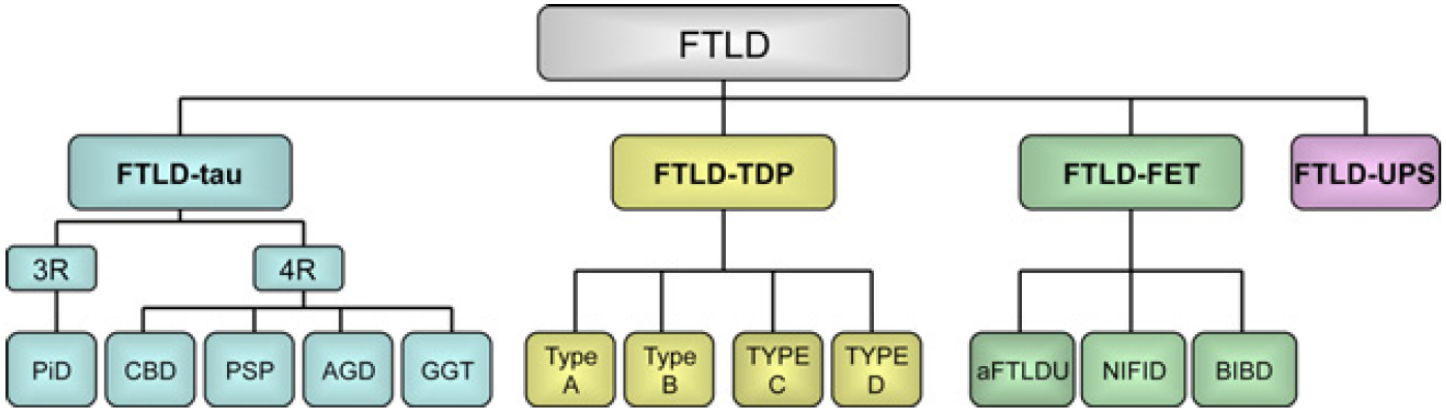

Fig. 1 Frontotemporal lobar degeneration (FTLD) molecular classification. 3R, 3 repeat; 4R, 4 repeat; aFTLDU, atypical FTLD with ubiquitin-positive inclusions; AGD, argyrophilic grain disease; BIBD, basophilic inclusion body disease; CBD, corticobasal degeneration; FET, fused in sarcoma, Ewing's sarcoma, TATA-binding protein-associated factor 15; GGT, globular glial tauopathy; NIFID, neuronal intermediate filament inclusion disease; PiD, Pick's disease; PSP, progressive supranuclear palsy; TDP, transactive response DNA binding protein; UPS, ubiquitin proteasome system.

Mackenzie IRA *et al., J Neurochem*., 2016

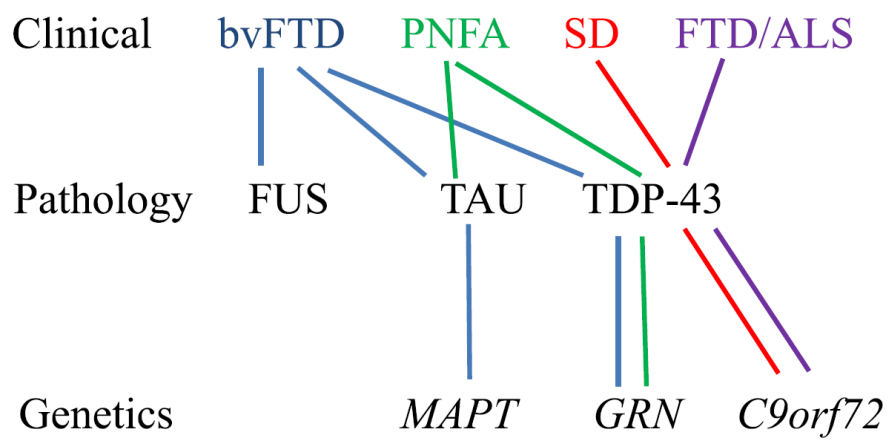

Figure 5. Clinicopathological-genetic relationships.

Table 1. Clinicopathological relationships.

Clinical phenotype	Pathology (type and subtype)								
	Tau		TDP-43				FUS		
			A	B	C	D	aFTLD-U	NIFID	BIBD
bvFTD	NFT	PB	NCI/DN	NCI	–	NII	NCI/NII	NCI	NCI
bvFTD/ALS	–	–	–	NCI	–	–	–	–	–
PNFA	–	PB	NCI/DN	–	–	–	–	–	–
SD	–	–	–	–	DN	–	–	–	–

bvFTD = behavioral variant frontotemporal dementia; ALS = Amyotrophic Lateral Sclerosis; PNFA = Progressive Non-Flent Aphasia; SD = Semantic dementia; aFTLD-U = atypical FTLD-U; NIFID = Neuronal Intermediate Filament Inclusion Body Disease; BIBD = Basophilic Inclusion Body Disease; NFT = neurofibrillary tangles; PB = Pick bodies; NCI = neuronal cytoplasmic inclusions; DN = dystrophic neurites; NII = neuronal intranuclear inclusions.

Mann DMA & Snowden JS, *Brain Pathol.*, 2017

Donaciones con DLFT en el Banco de Tejidos CIEN

FUS

TDP-43

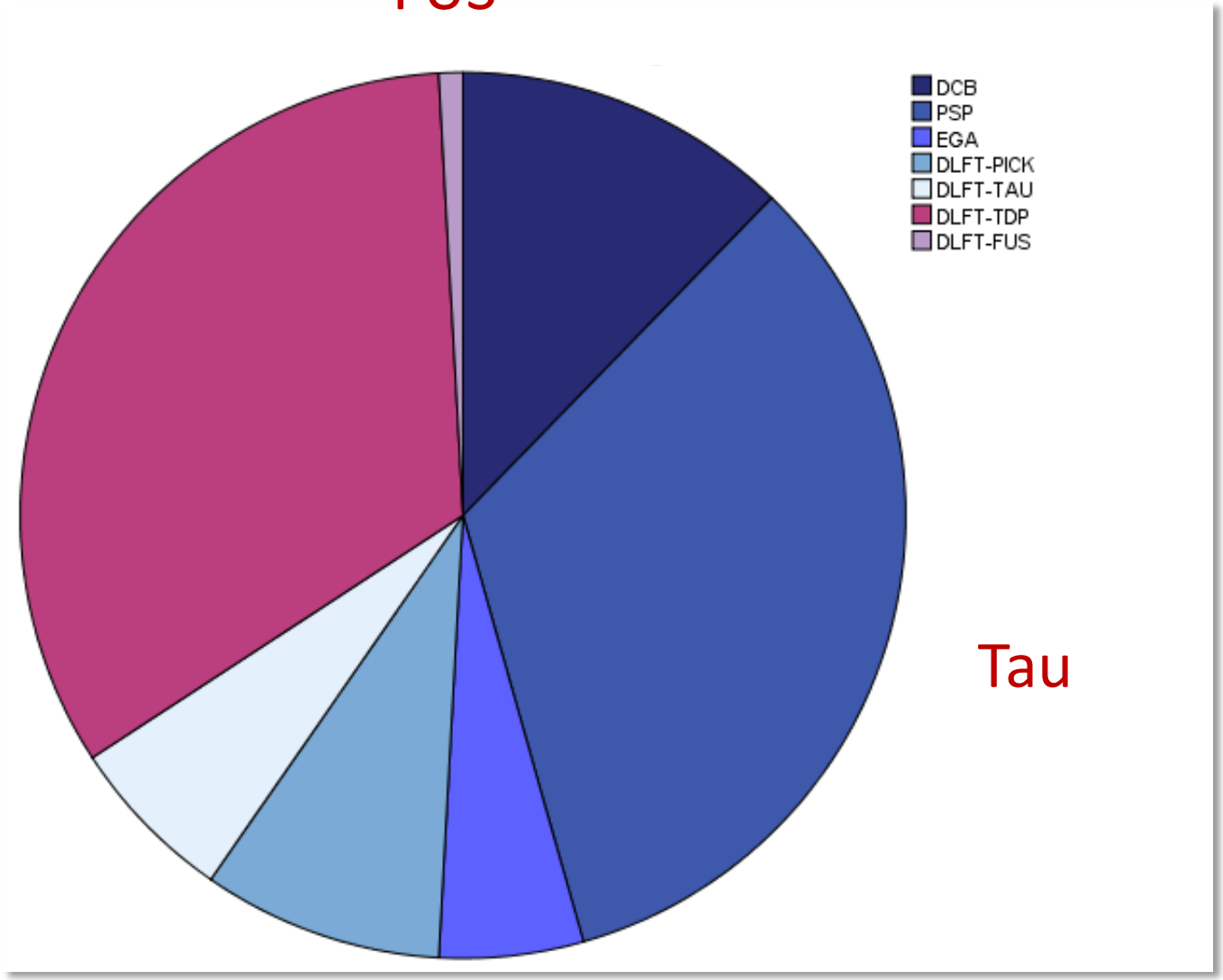

Tau

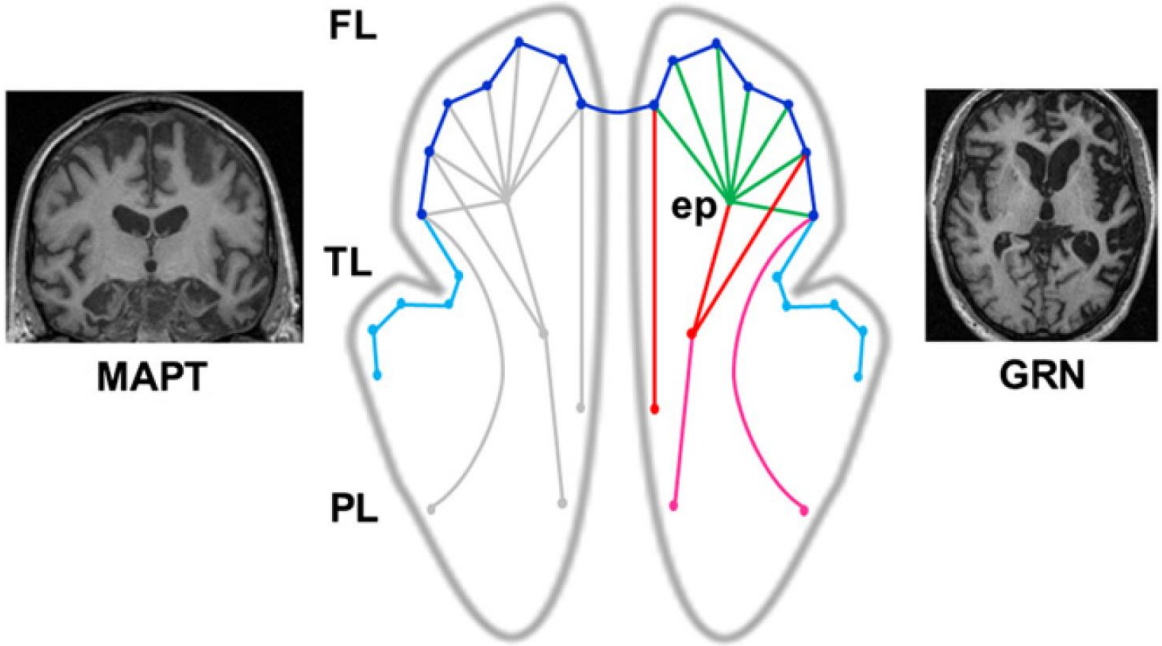

Figure 1. From Syndromes to Molecular Nexopathies

Warren JD *et al*., *Neuron*, 2012

Degeneración lobar frontotemporal con inclusiones **tau (+)**

Isoformas de tau

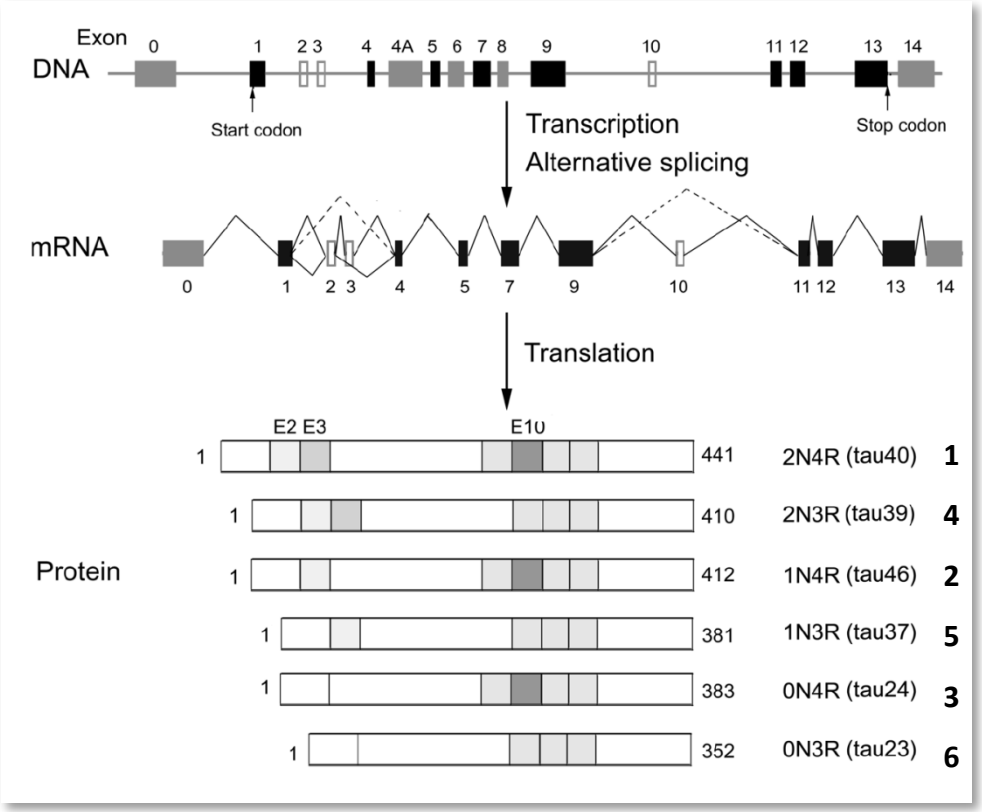

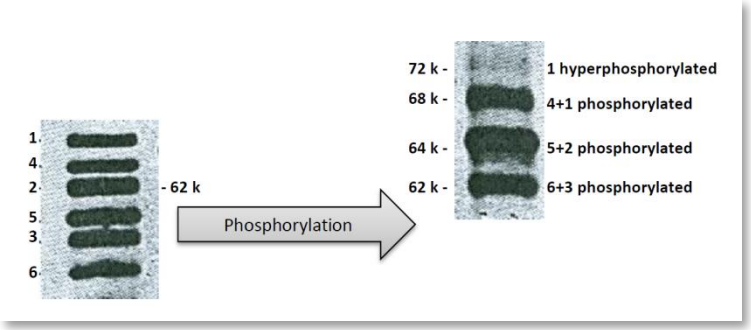

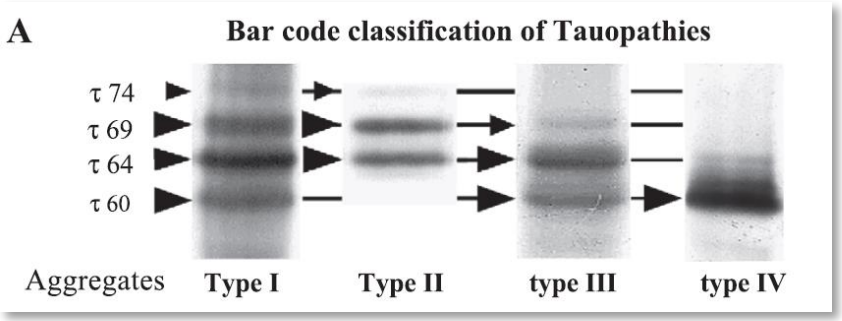

3R/4R 4R 3R

Liu & Gong, 2008

Sergeant *et al.*, 2005

Degeneración córticobasal

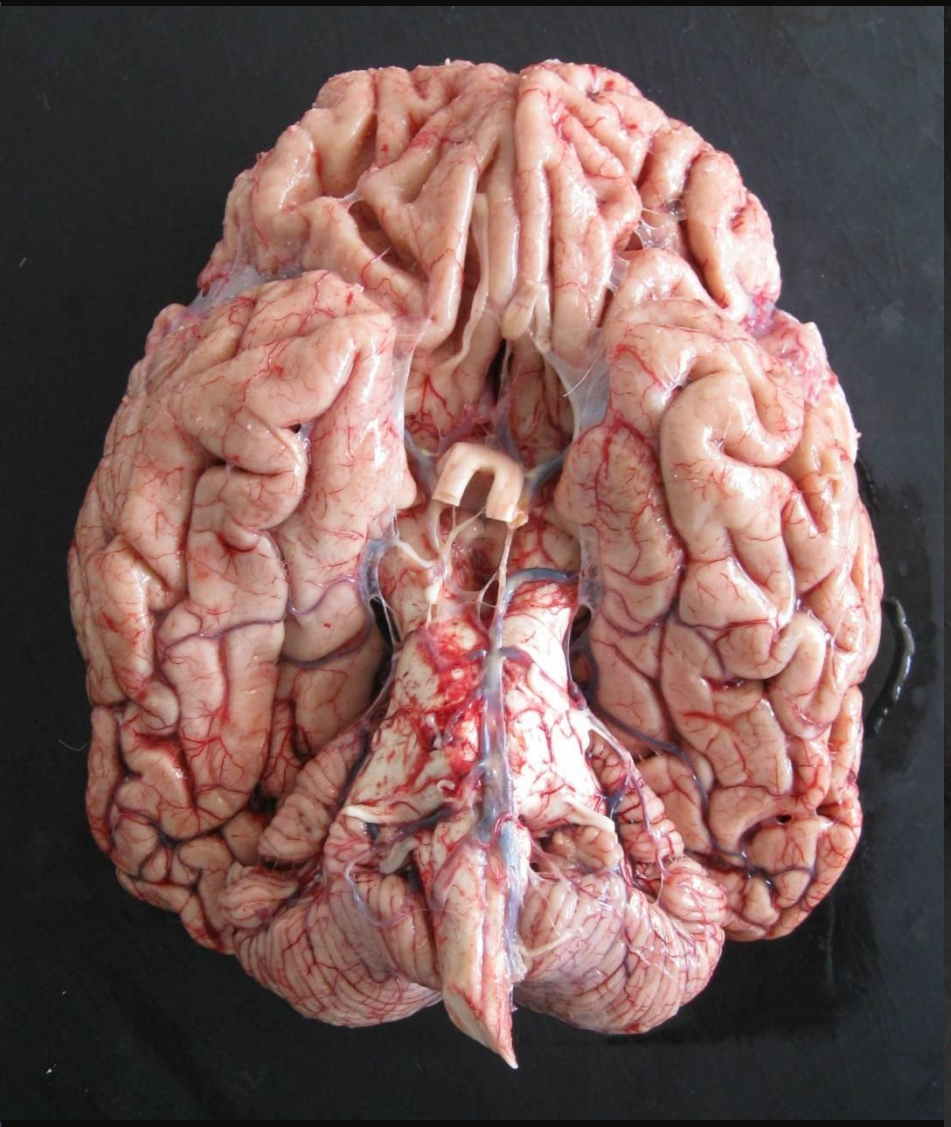

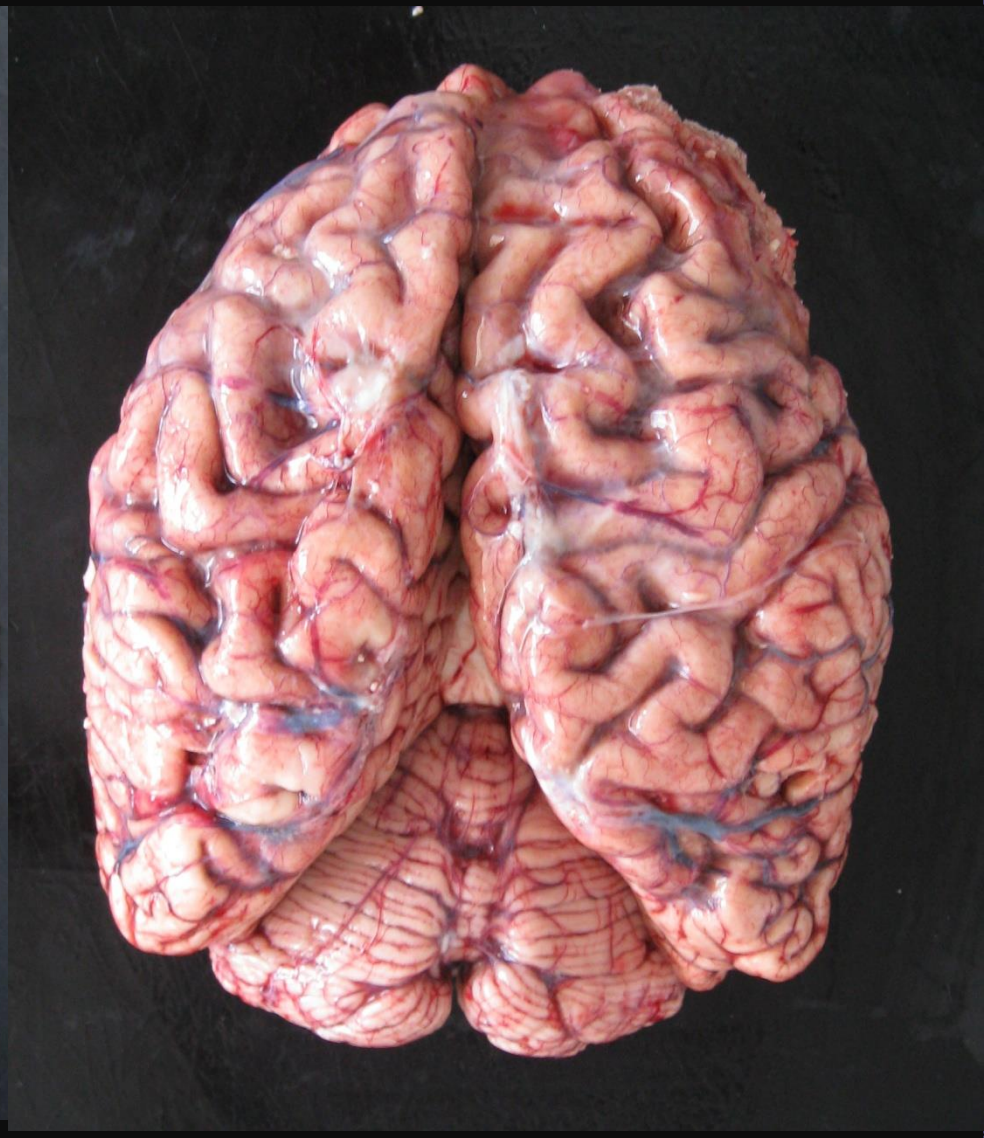

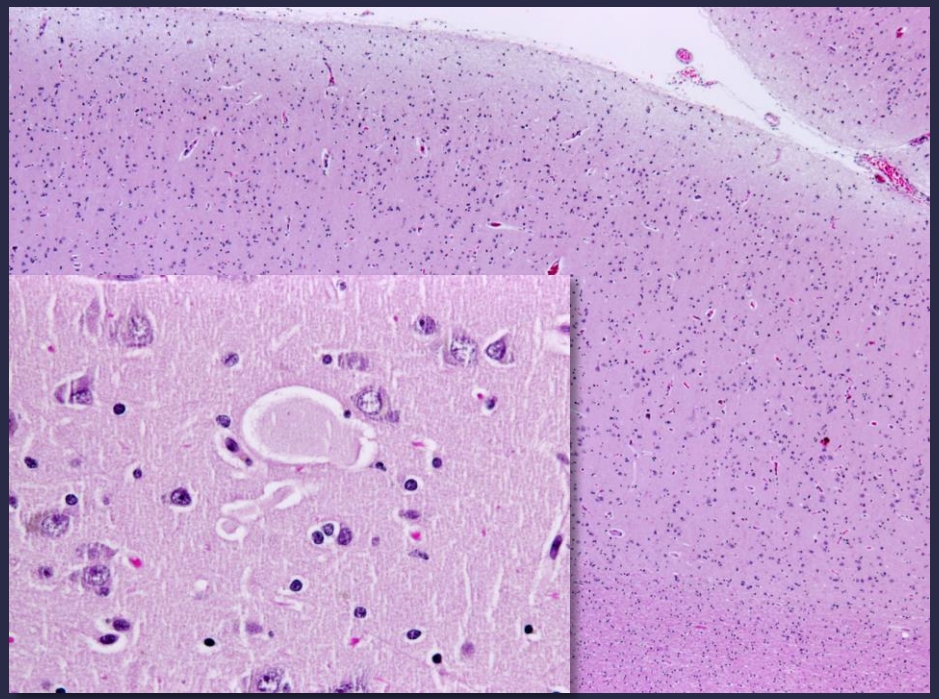

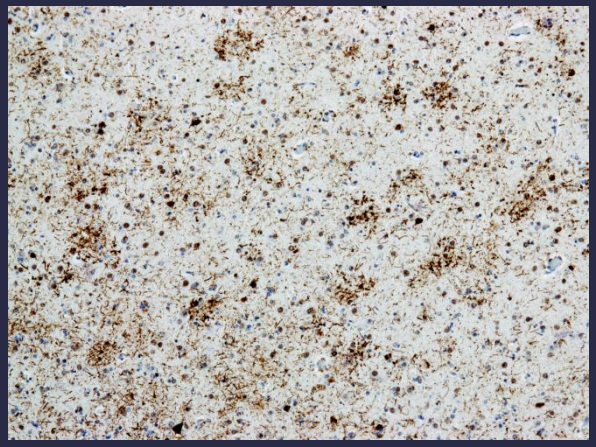

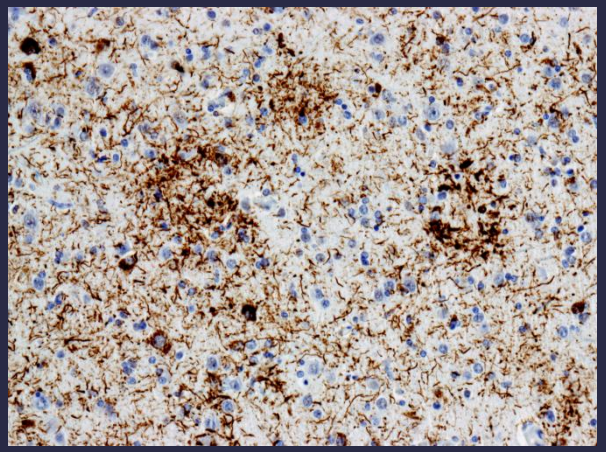

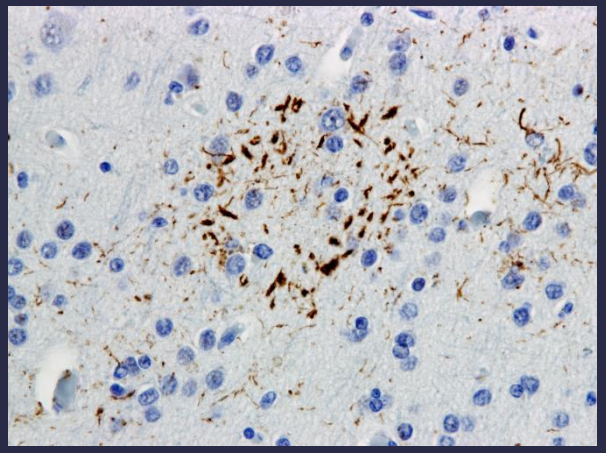

Córtex frontal, tau AT100

Parálisis supranuclear progresiva – demencia frontotemporal

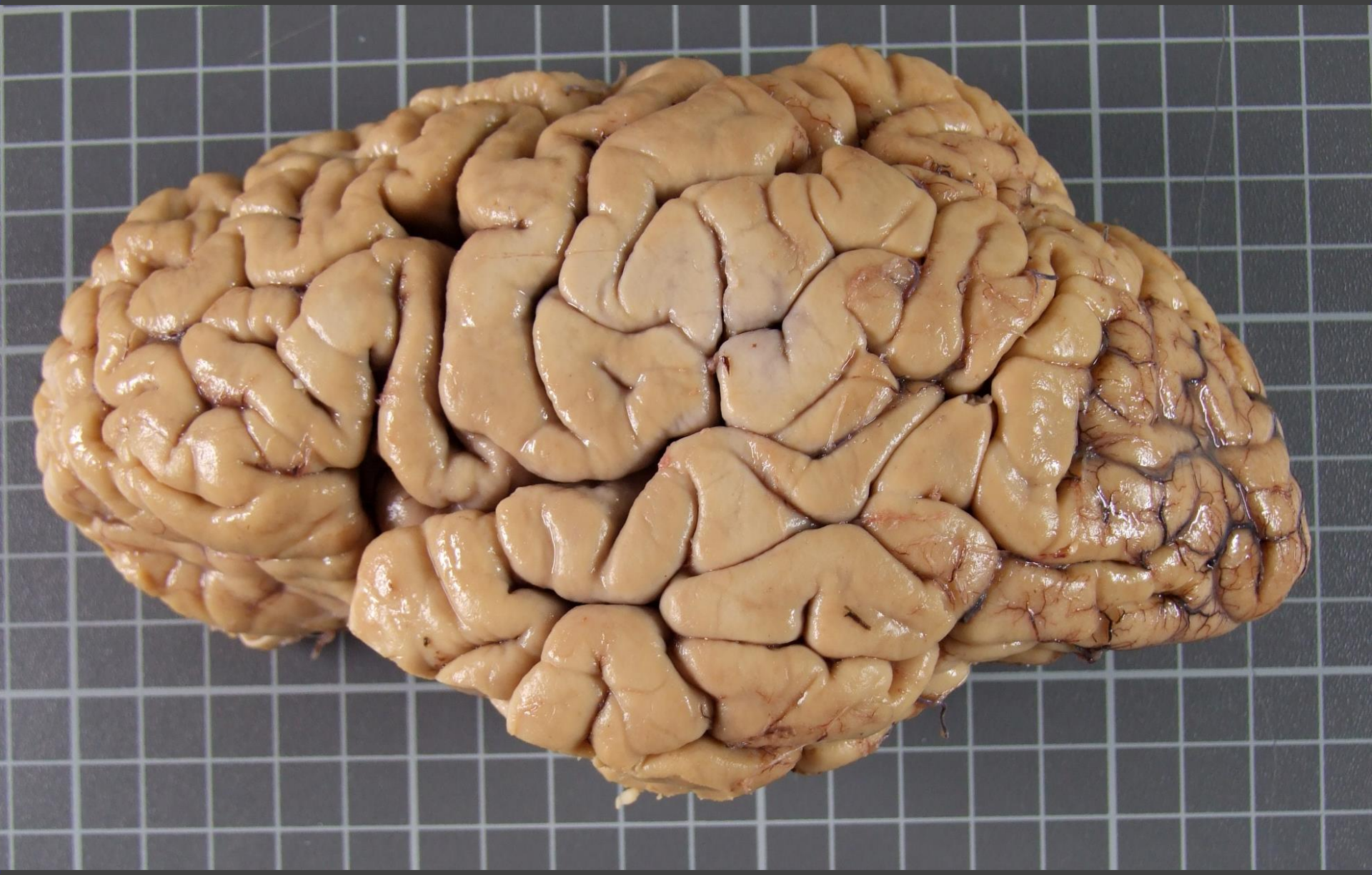

Parálisis supranuclear progresiva

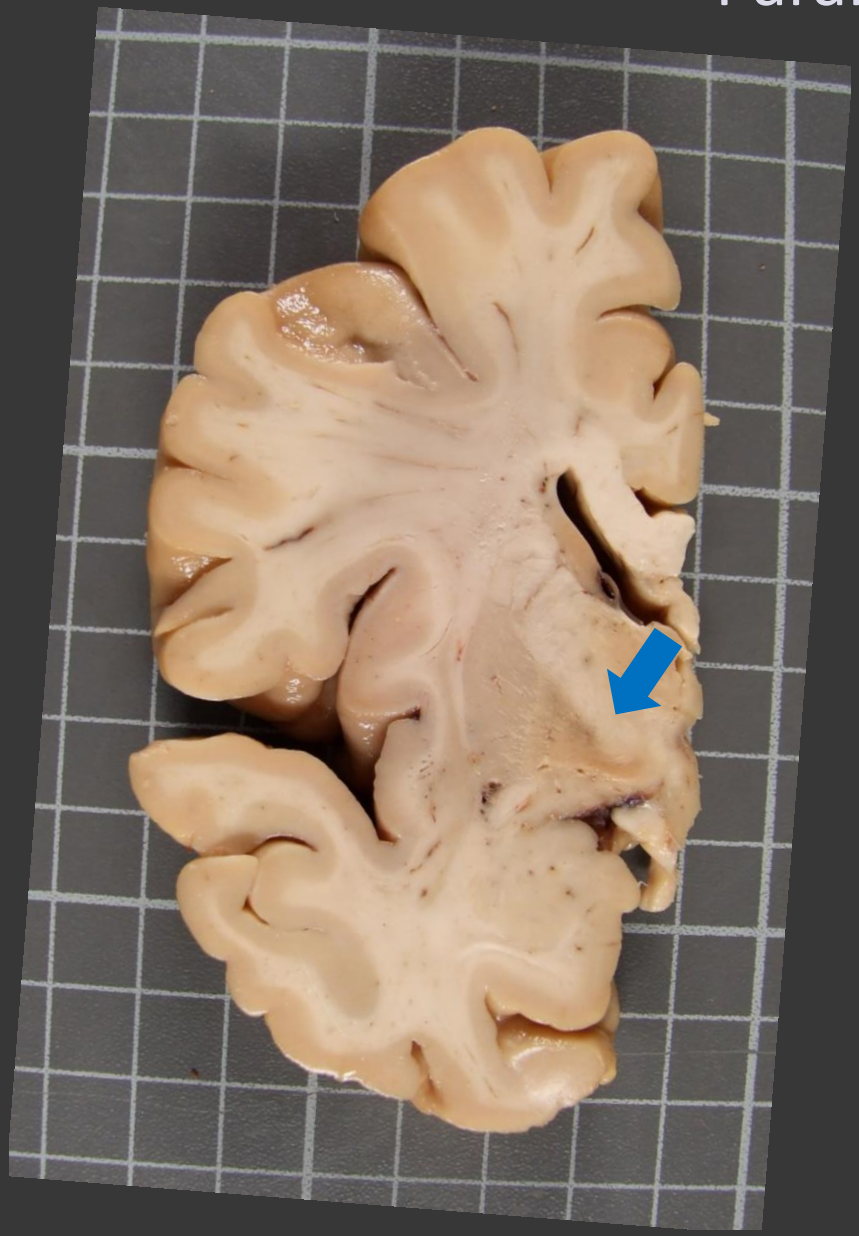

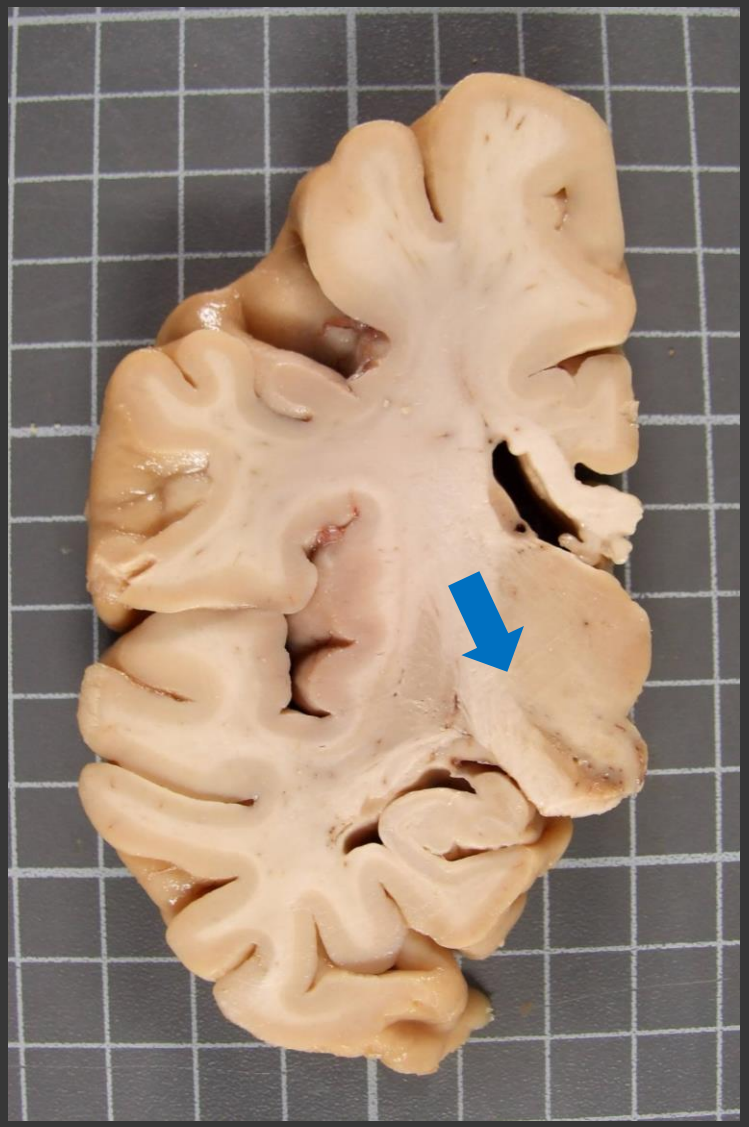

Cx frontal
Tau AT100

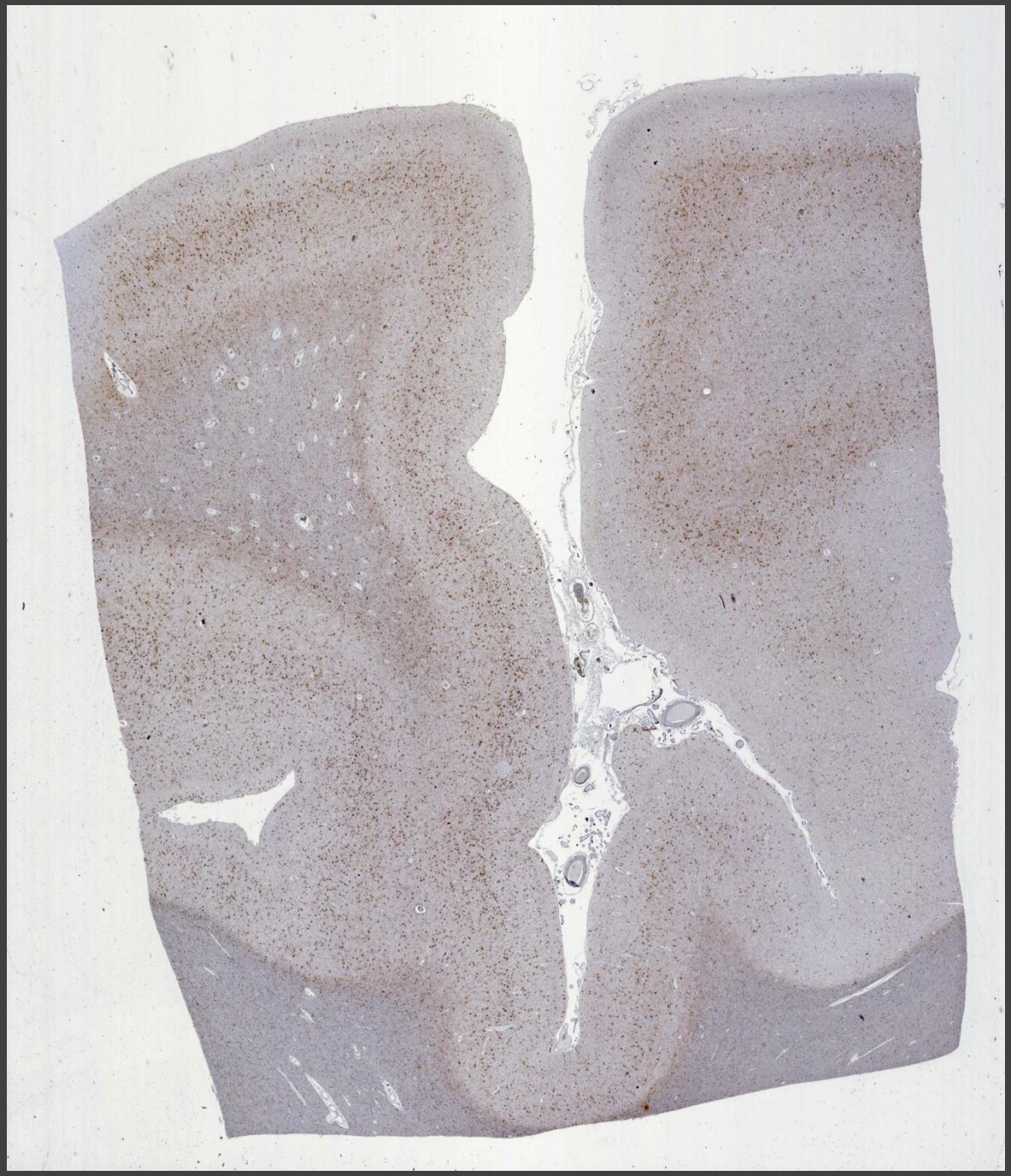

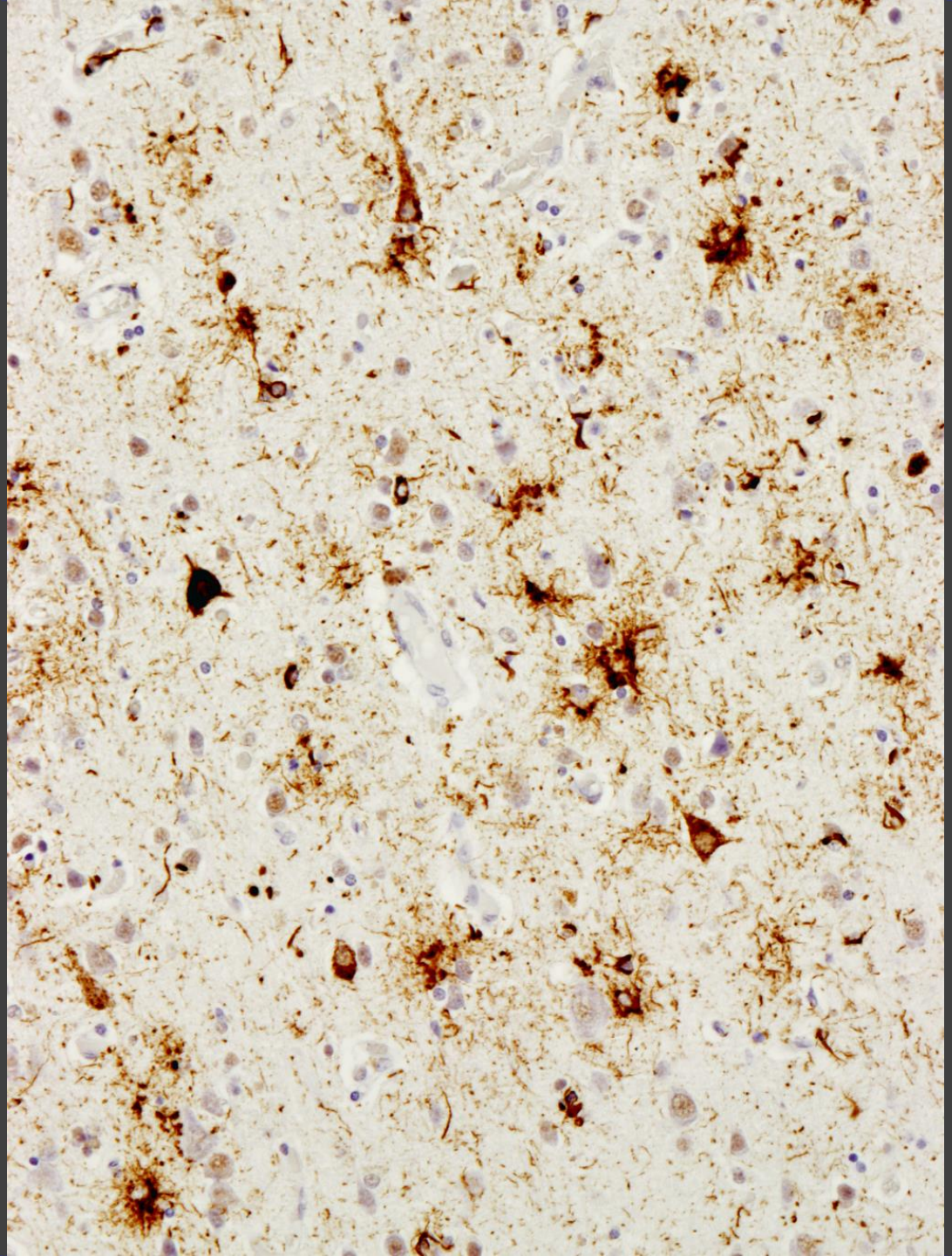

INCLUSIONES TAU (+):

Astrocitos en penacho
"tufted astrocytes"

Ovillos globoides

Preovillos

Inclusiones
oligodendrogliales
"coiled bodies"

Hebras neuropílicas

Enfermedad de Pick

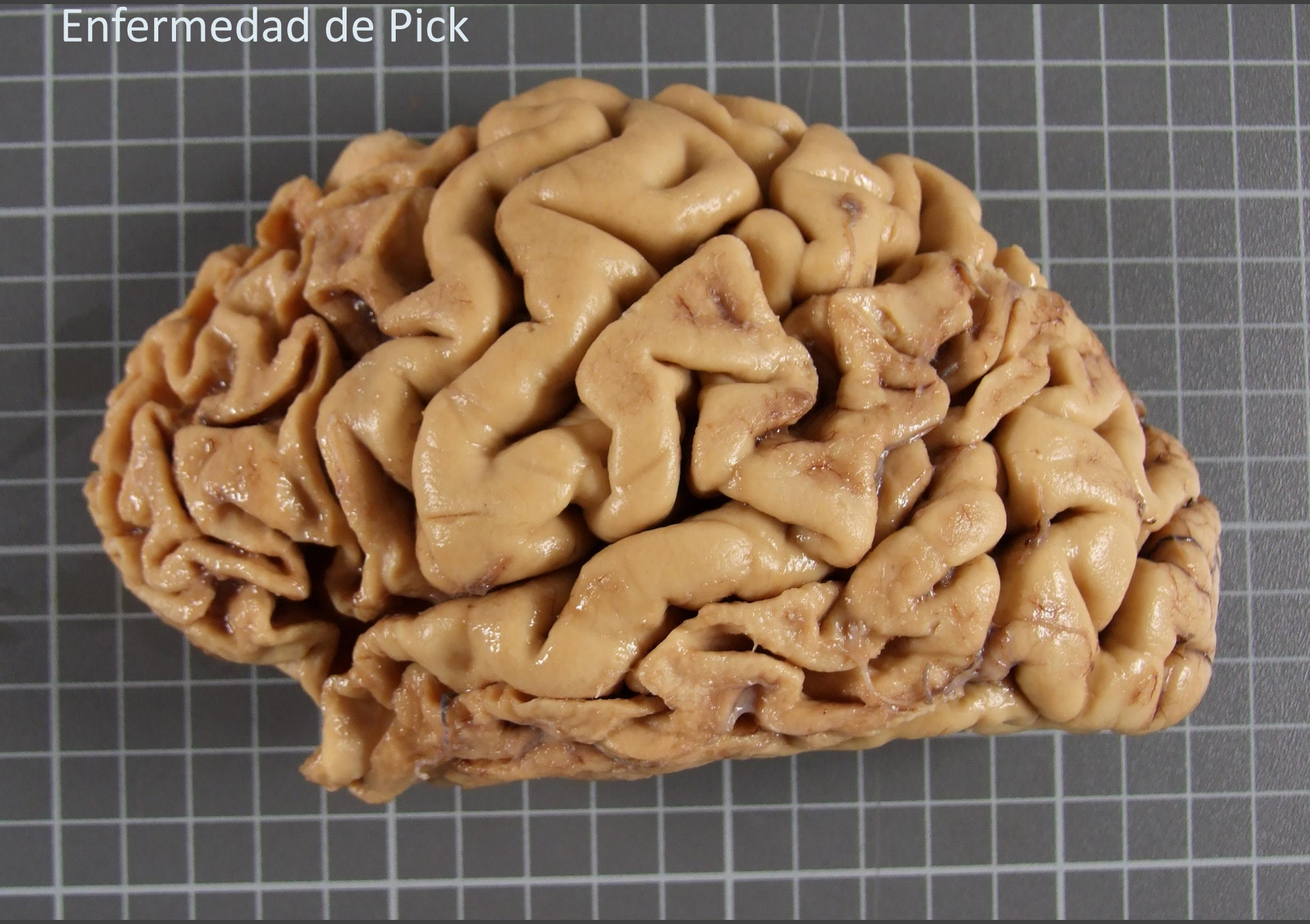

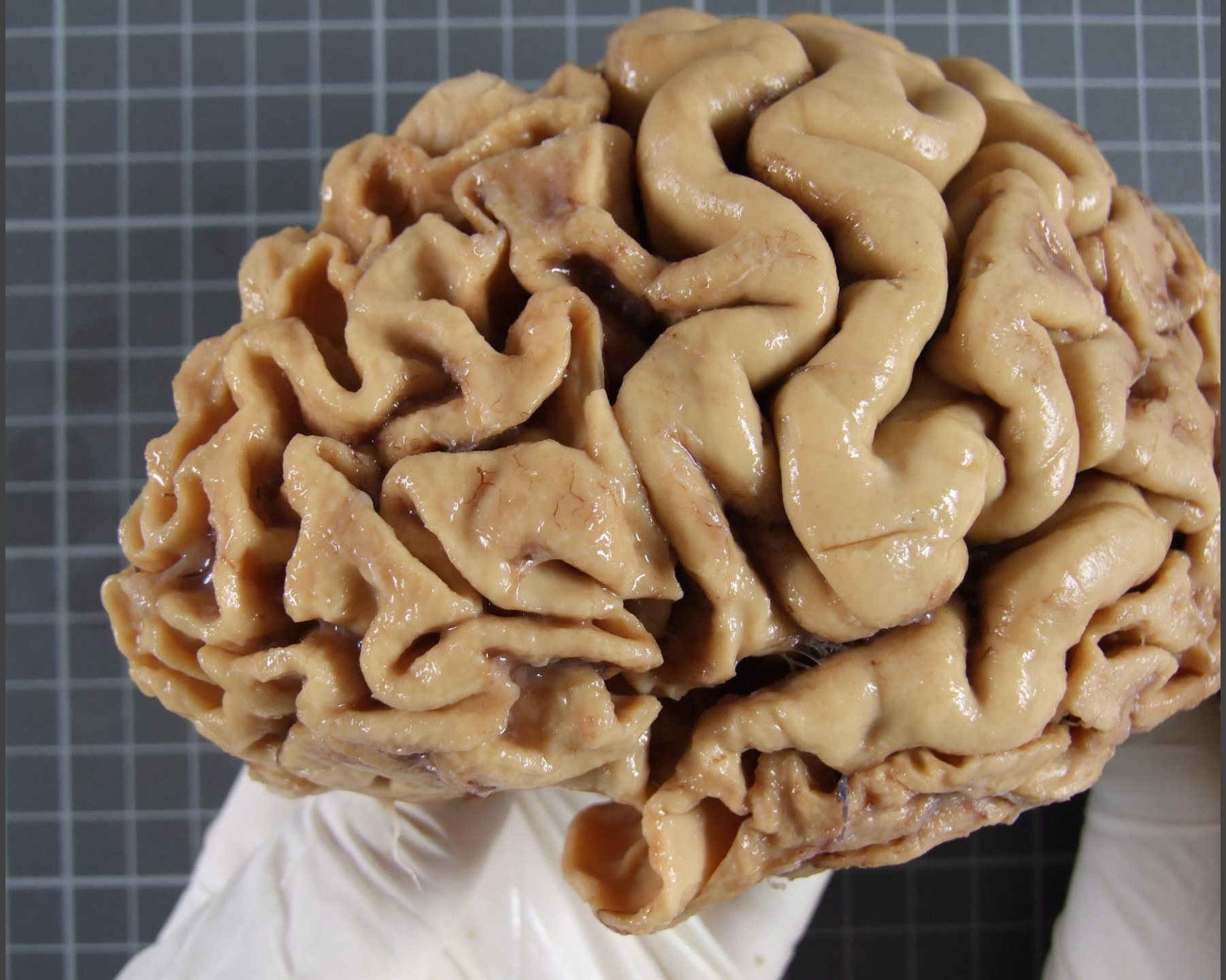

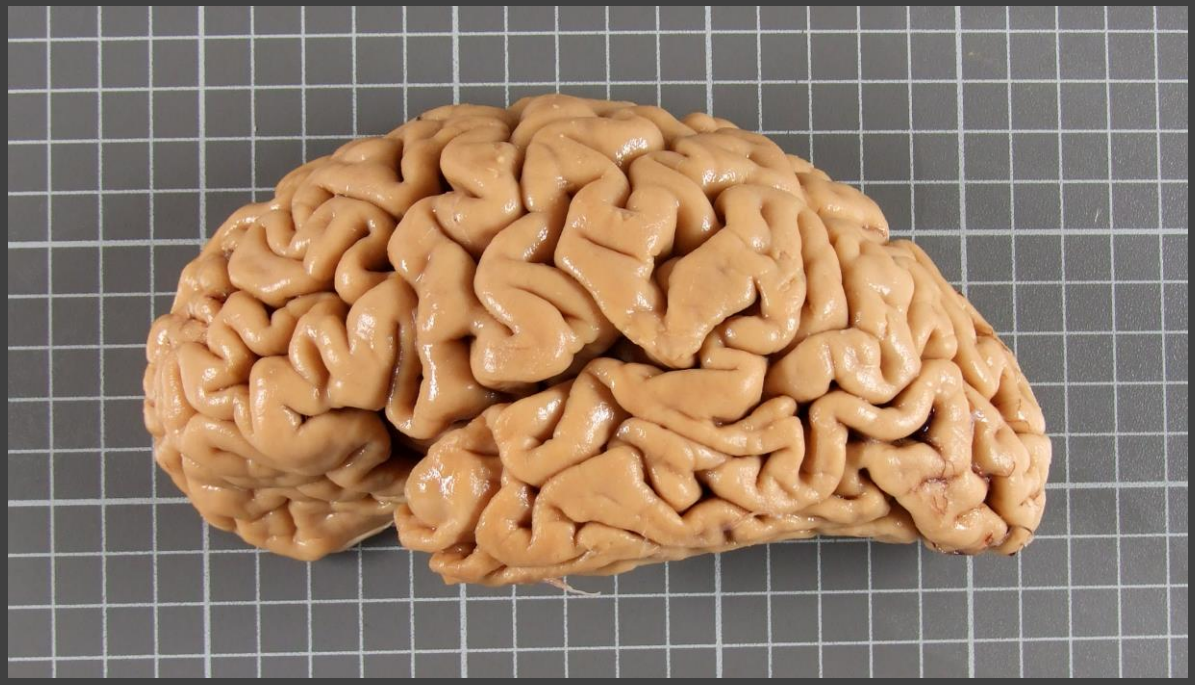

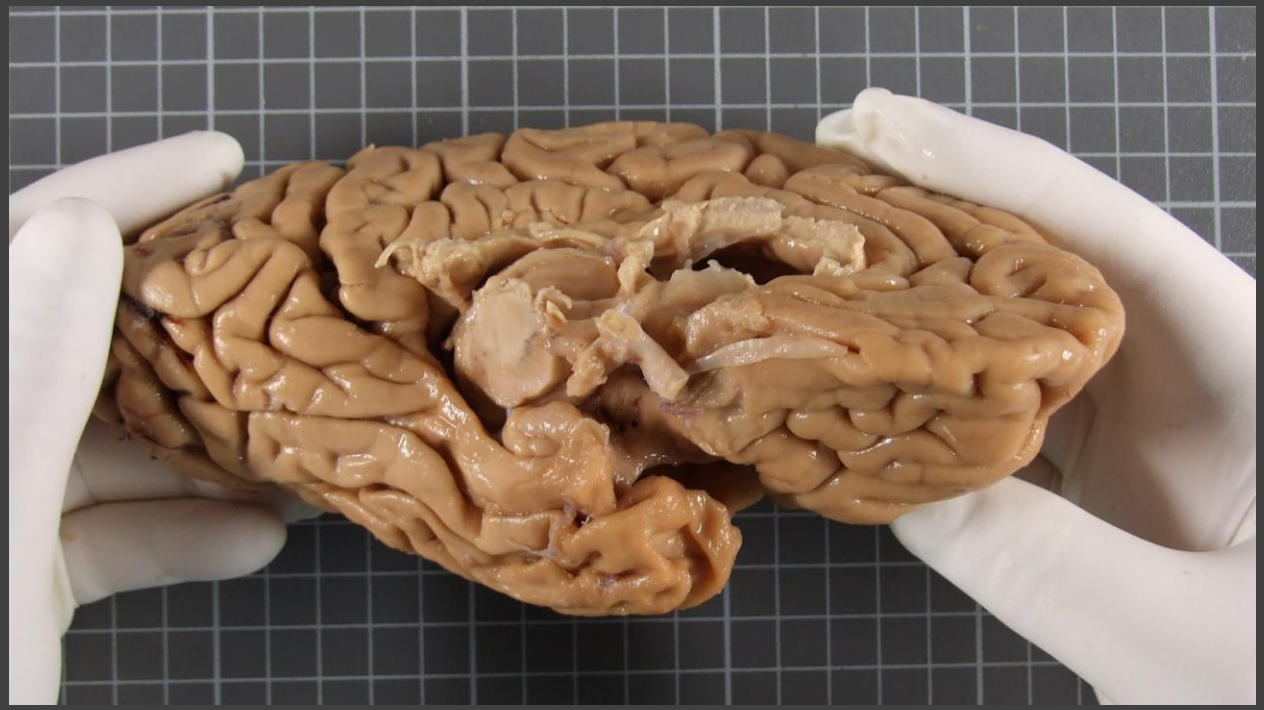

Enfermedad de Pick

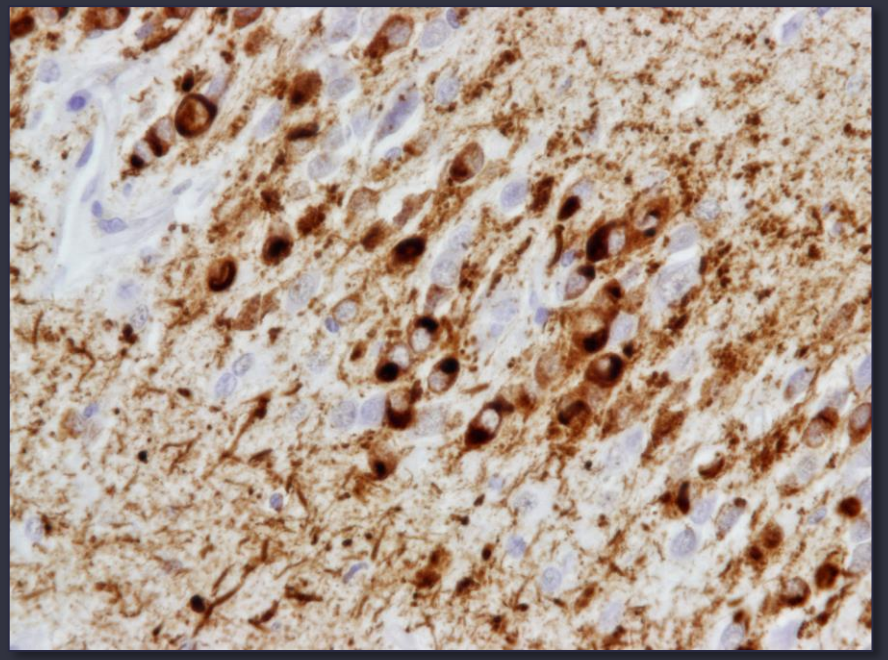

DLFT-tau

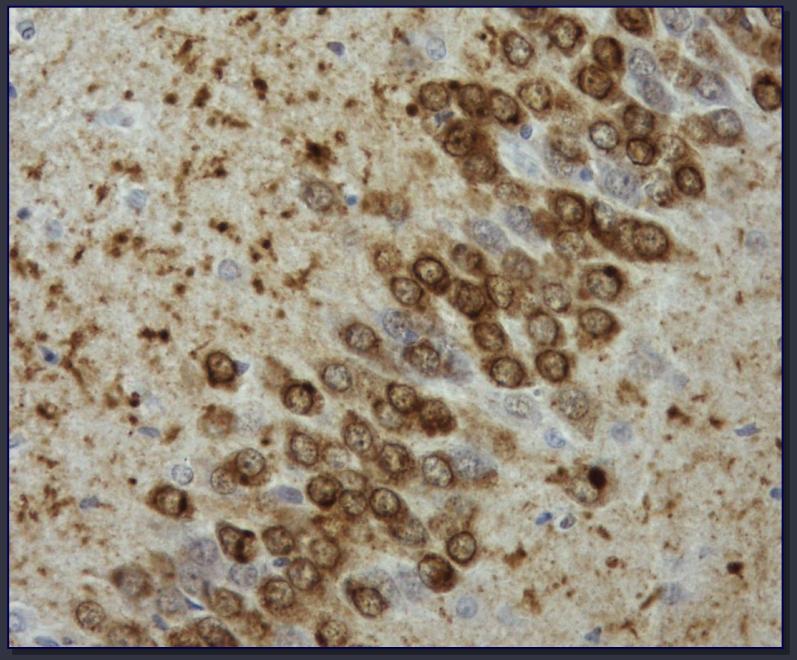

Tau AT100

Enfermedad de granos argirófilos

Gallyas

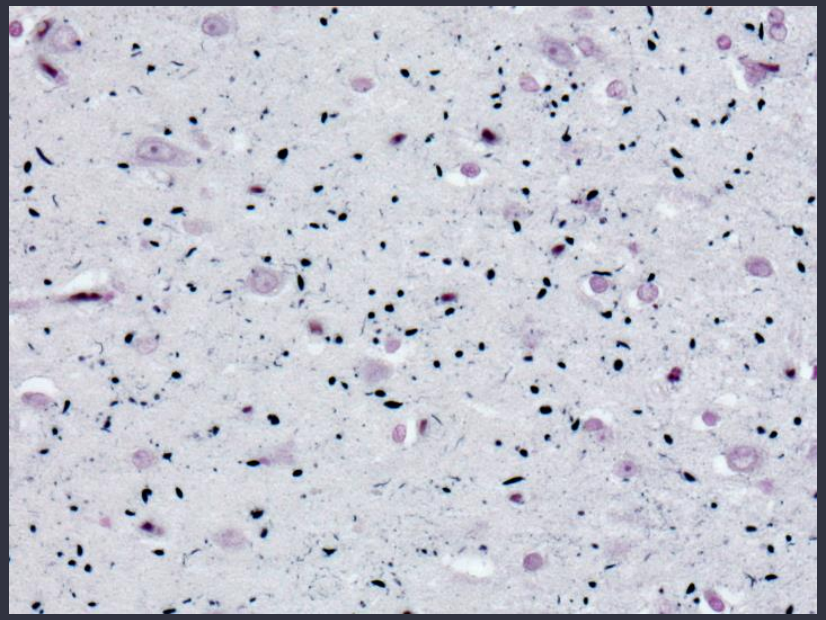

Taupatía con IGG

Tau AT8

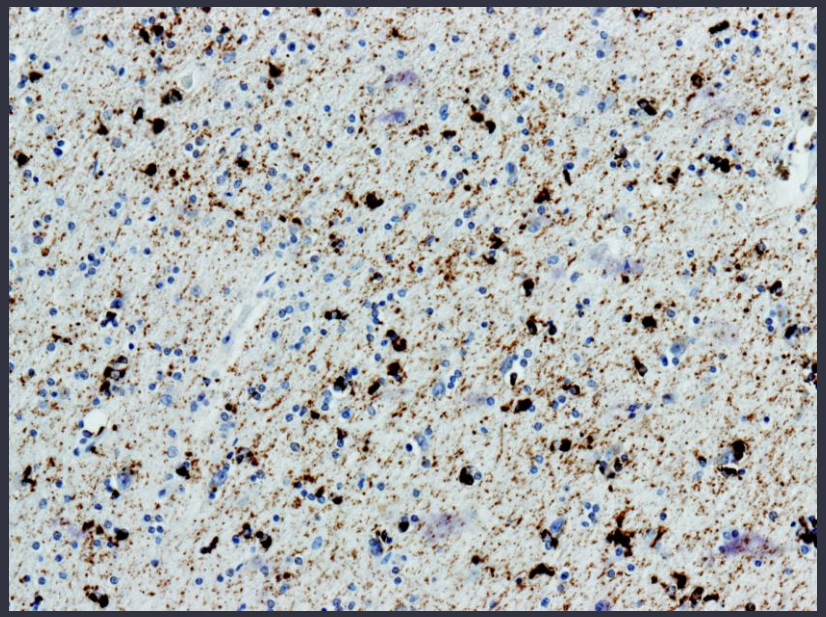

Degeneración lobar frontotemporal con inclusiones **TDP-43 (+)**

Patobiología de la TDP-43

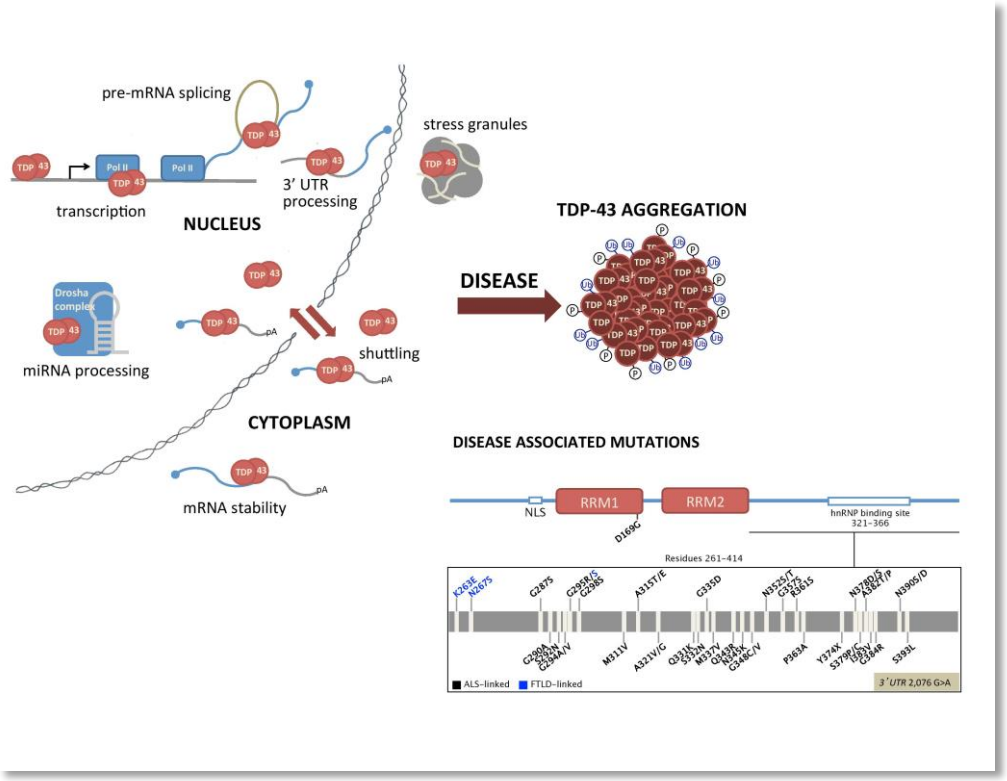

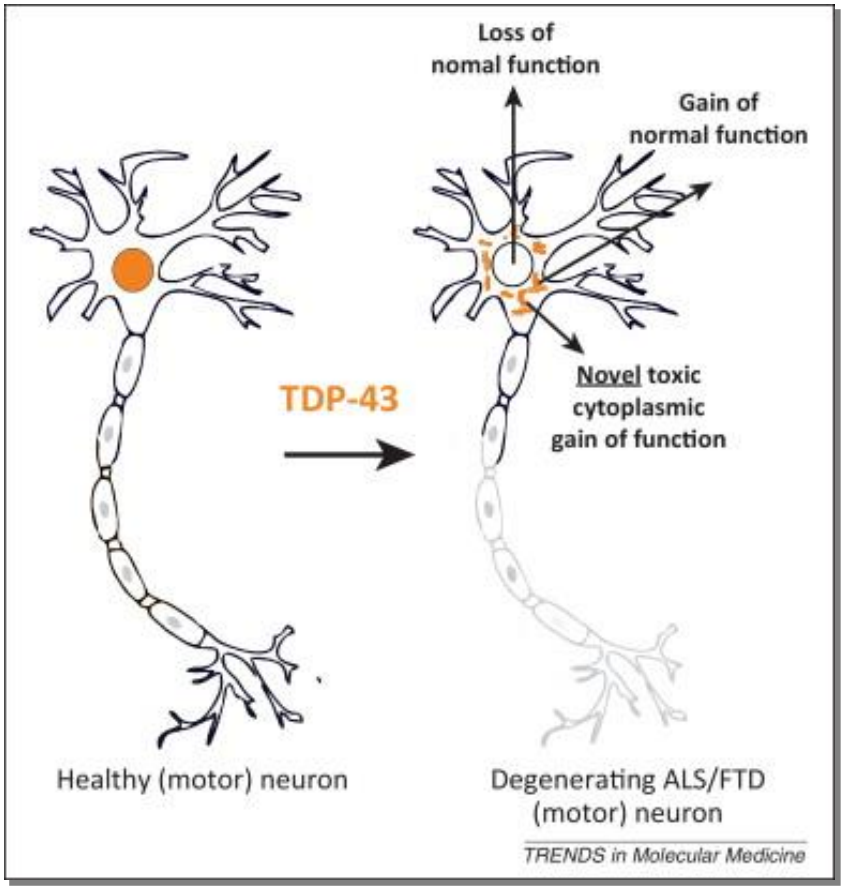

https://hopecenter.wustl.edu/?faculty=youhna-ayala-phd

Degeneración lobar frontotemporal TDP

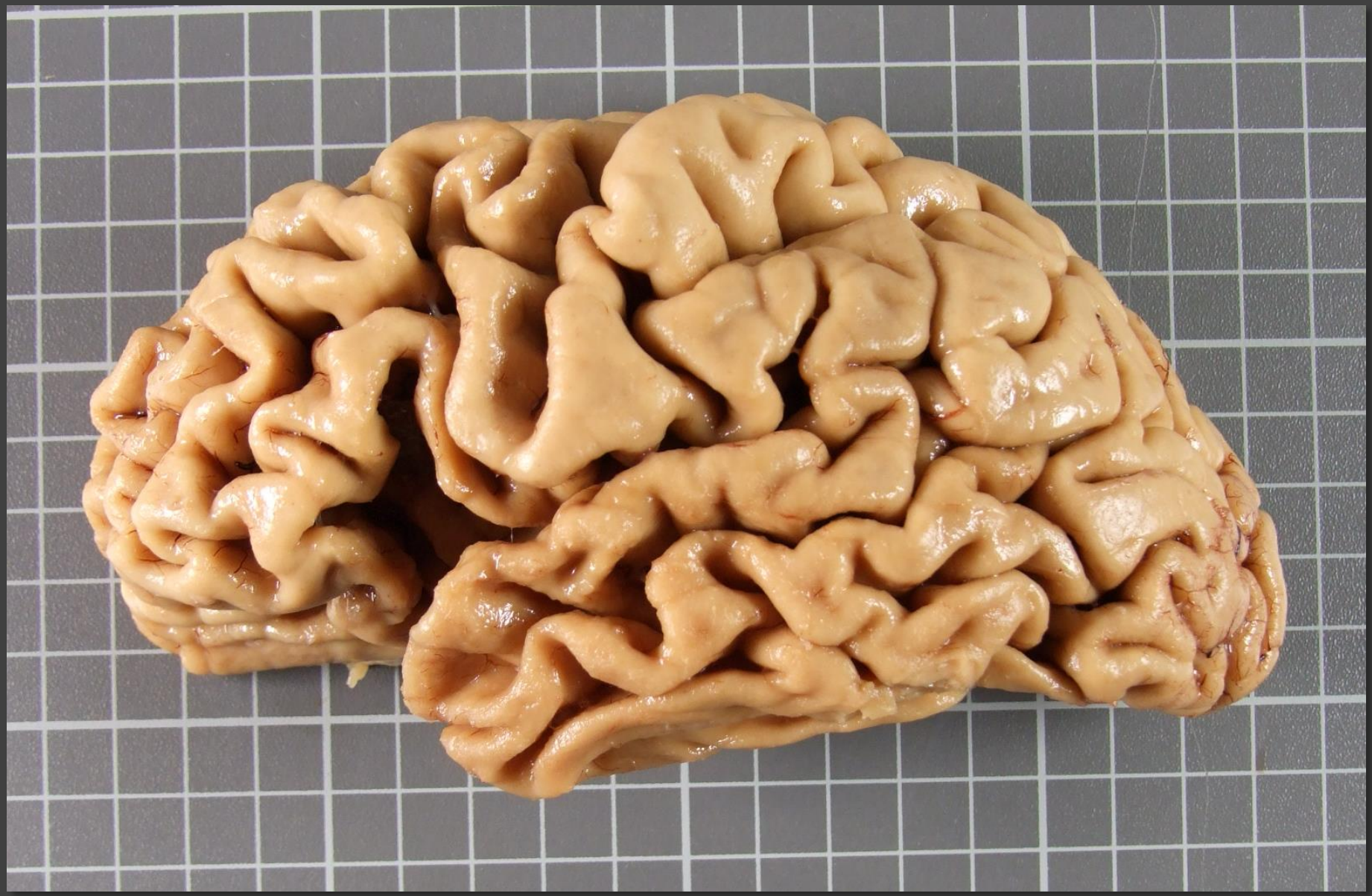

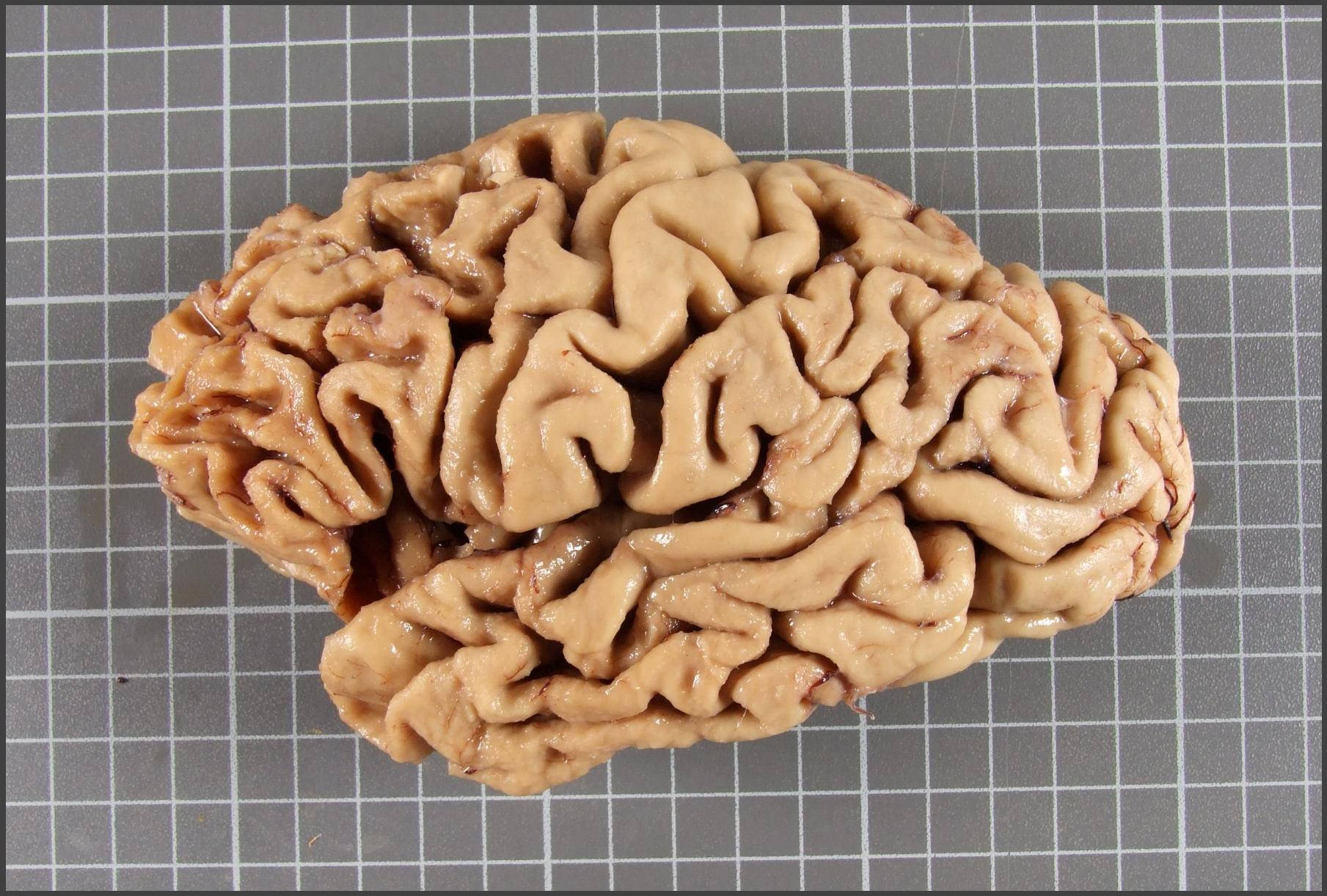

Clasificación de la DLFT-TDP

Table 1 Proposed new classification system for FTLD-TDP pathology, compared with existing systems

New system	Mackenzie et al. [7]	Sampathu et al. [11]	Cortical pathology	Common phenotype	Associated genetic defects
Tipo A	Type 1	Type 3	Many NCI Many short DN Predominantly layer 2	bvFTD PNFA	*GRN* mutations
Tipo B	Type 3	Type 2	Moderate NCI Few DN All layers	bvFTD MND with FTD	Linkage to chromosome 9p
Tipo C	Type 2	Type 1	Many long DN Few NCI Predominantly layer 2	SD bvFTD	
Tipo D	Type 4[a]	Type 4[a]	Many short DN Many lentiform NII Few NCI All layers	Familial IBMPFD	*VCP* mutations

bvFTD behavioural variant frontotemporal dementia, *DN* dystrophic neurites, *GRN* progranulin gene, *IBMPFD* inclusion body myopathy with Paget's disease of bone and frontotemporal dementia, *MND* motor neuron disease, *NCI* neuronal cytoplasmic inclusions, *NII* neuronal intranuclear inclusions, *PNFA* progressive non-fluent aphasia, *SD* semantic dementia, *VCP* valosin-containing protein gene

[a] Described subsequently by Forman et al. [4]

Mackenzie IRA *et al., Acta Neuropathol.*, 2011

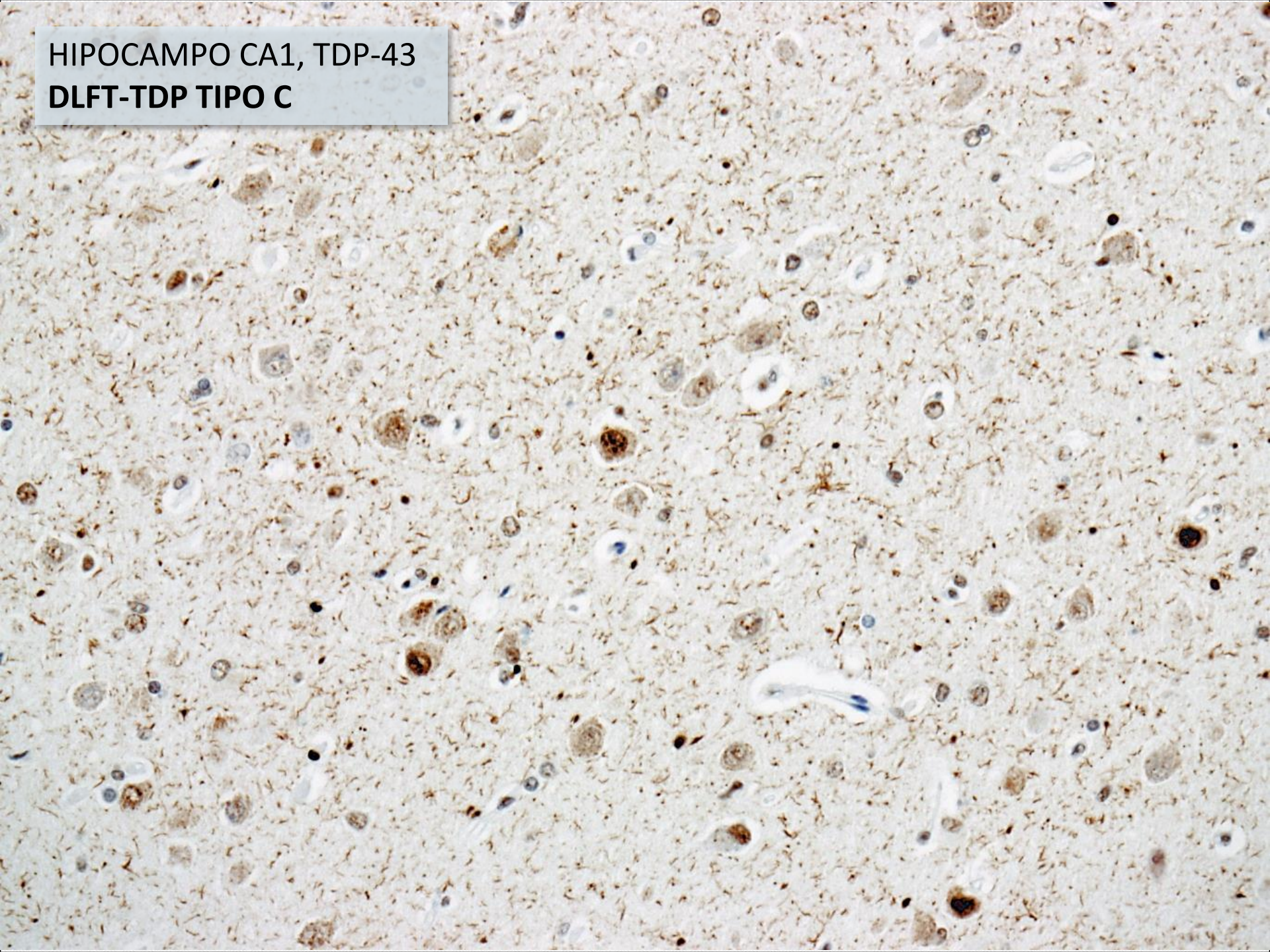
HIPOCAMPO CA1, TDP-43
DLFT-TDP TIPO C

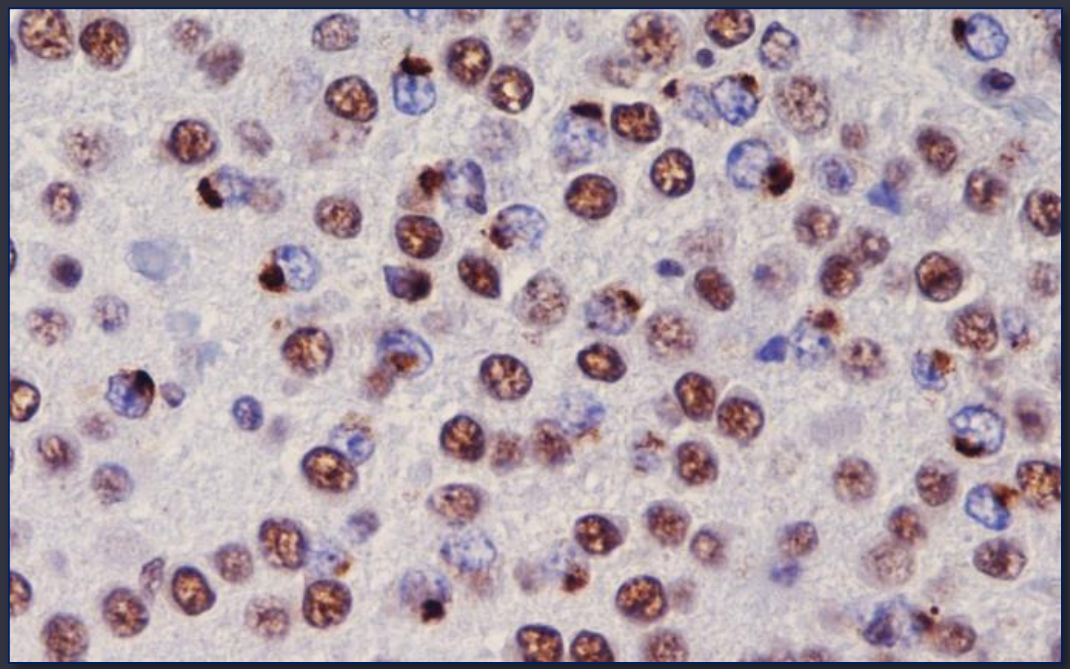

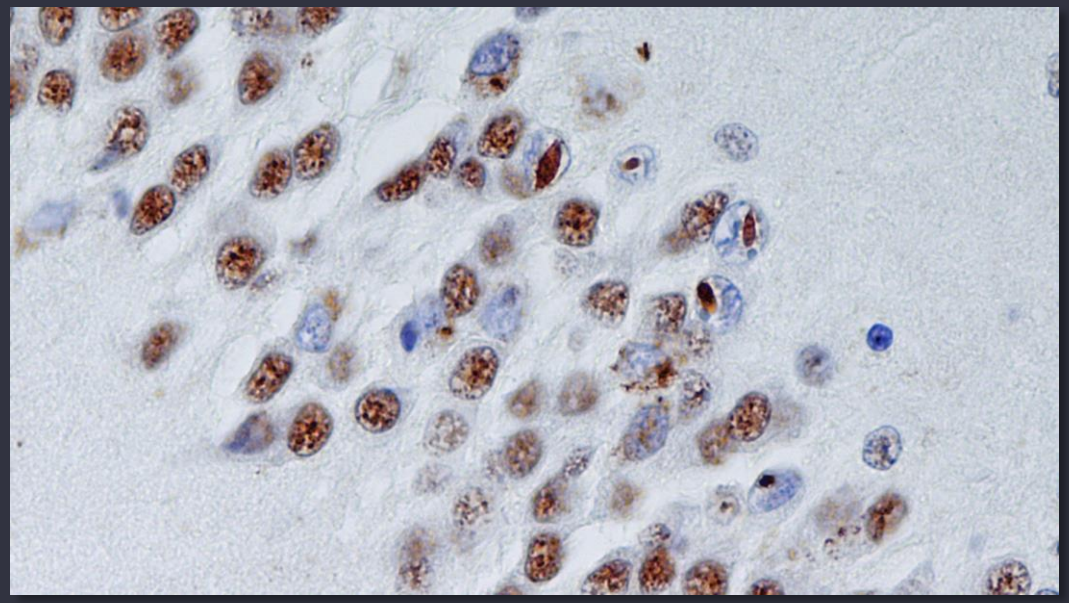

HIPOCAMPO,
GIRO DENTADO,
INMUNOHX TDP-43

CÓRTEX FRONTAL CAPA II,
INMUNOHX TDP-43
DLFT-TDP TIPO A
MUTACIÓN EN *PGRN*

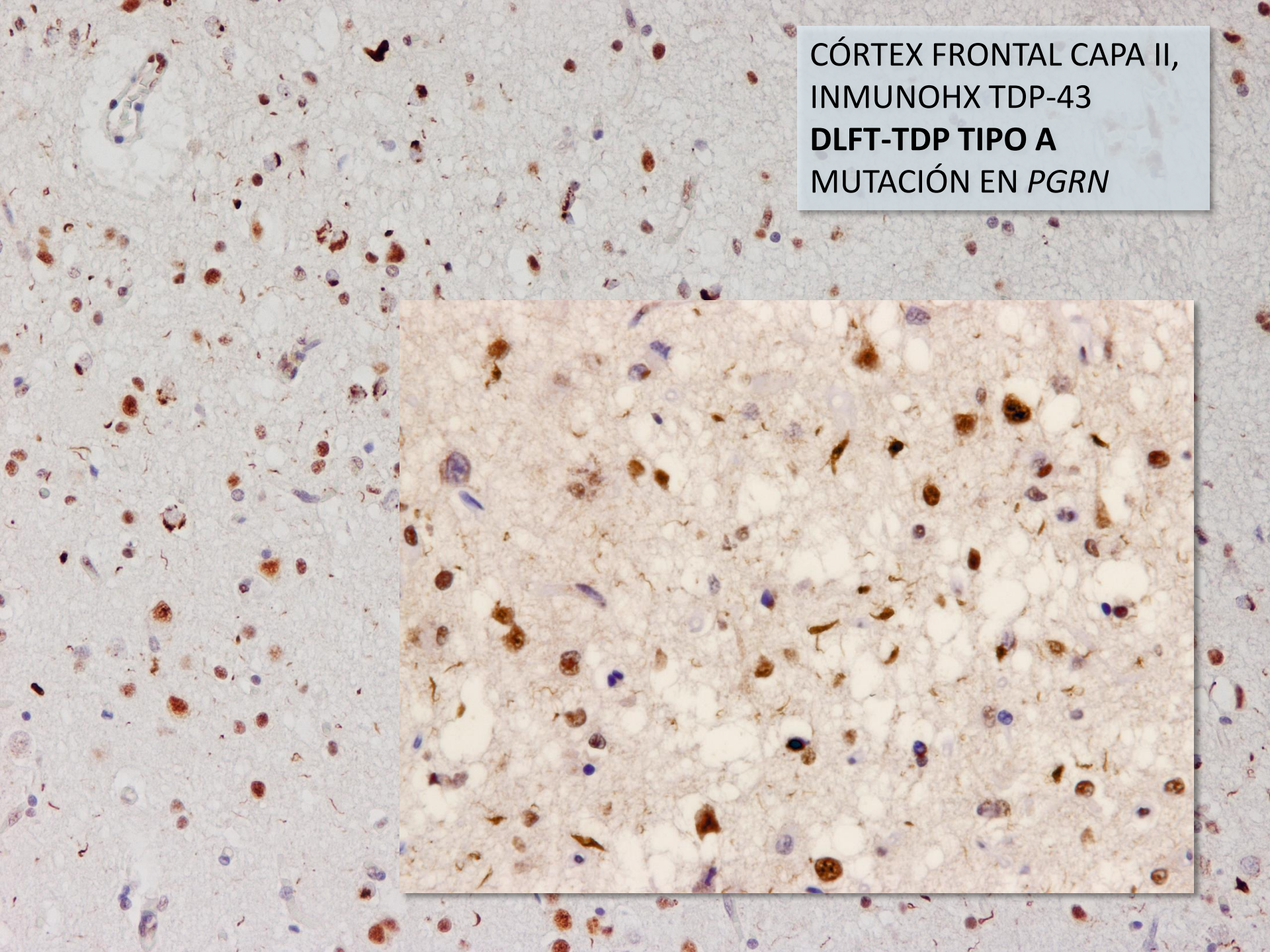

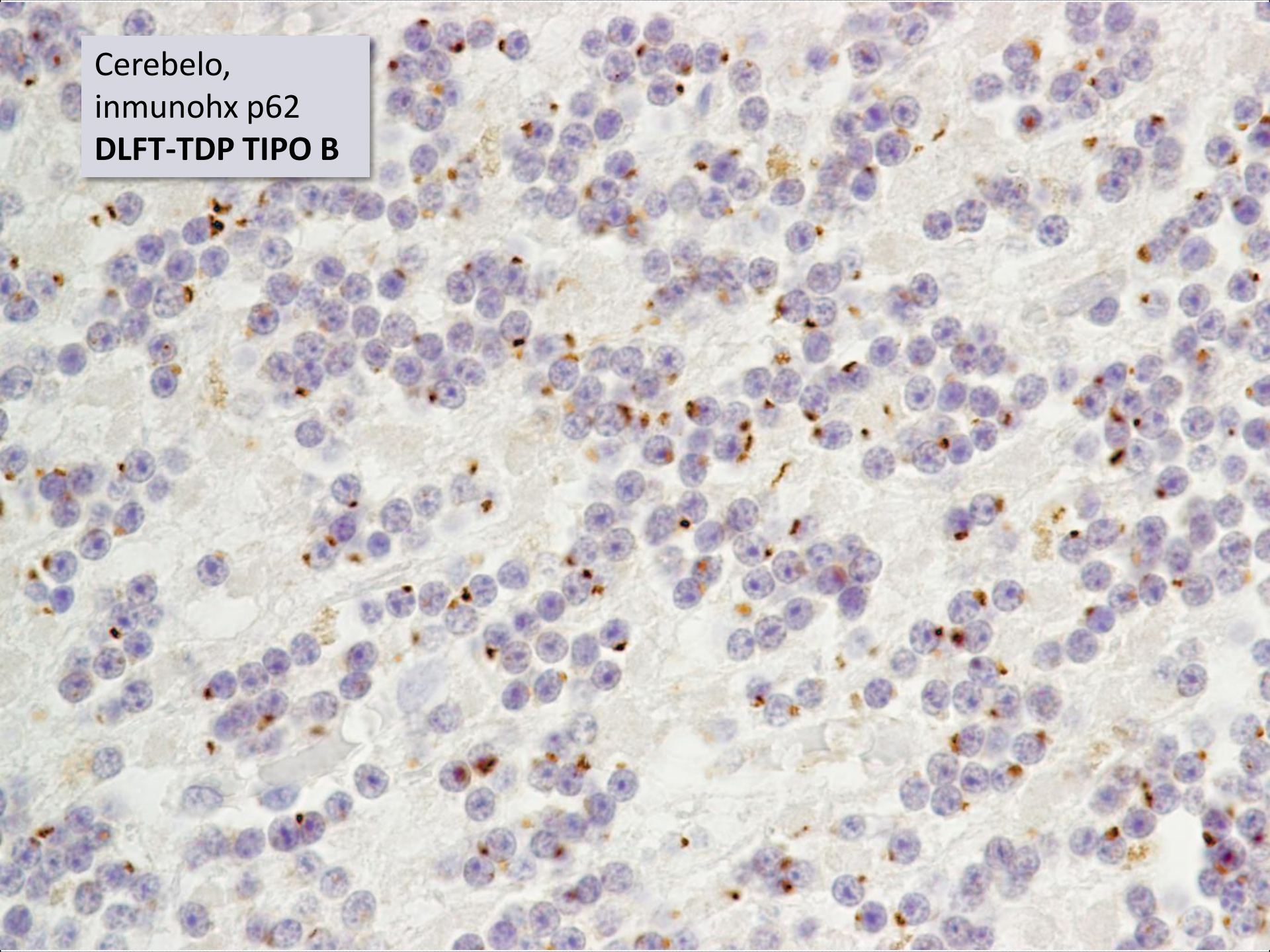
Cerebelo,
inmunohx p62
DLFT-TDP TIPO B

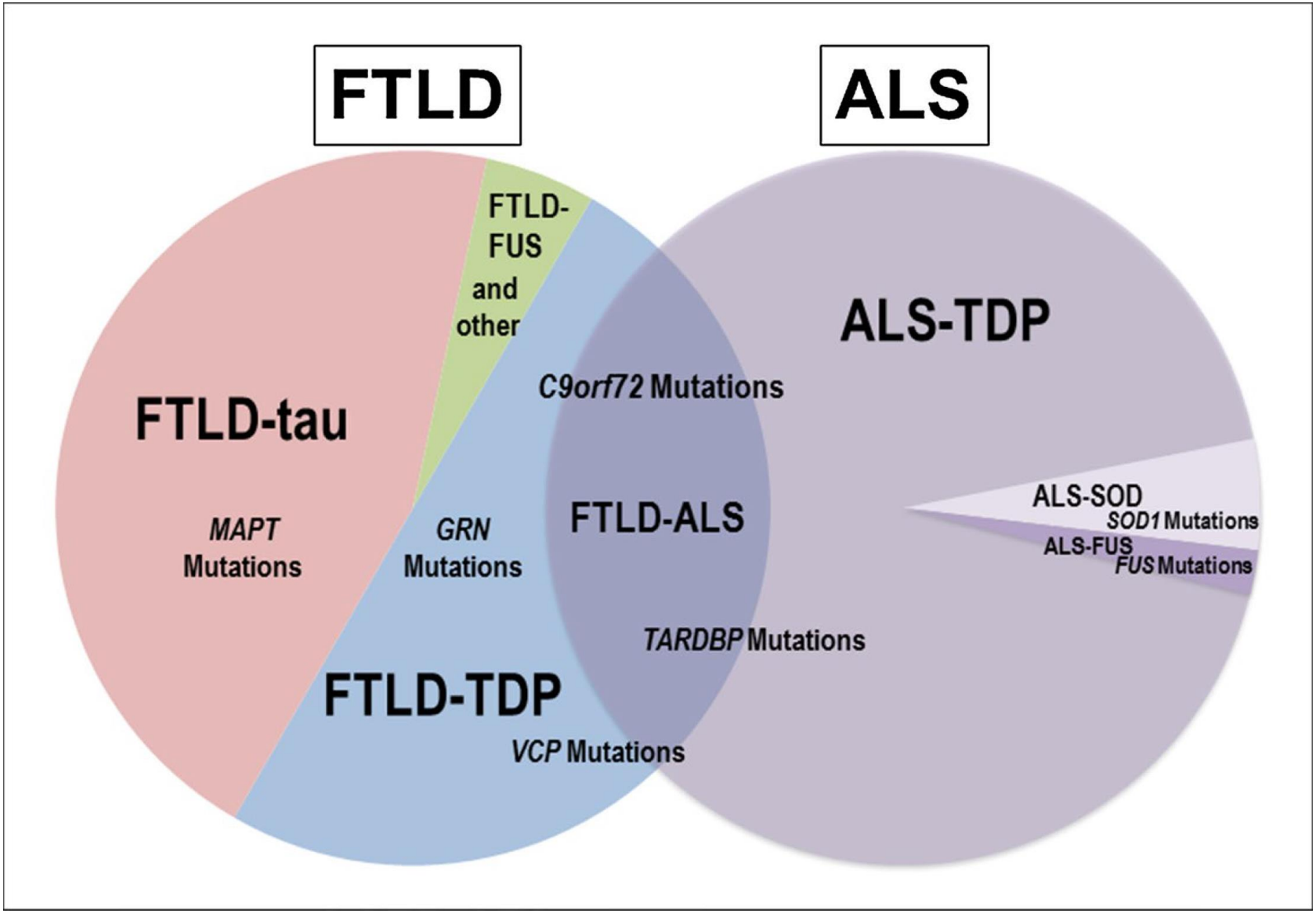

Irwin DJ et al., Acta Neuropathol. 2014

Degeneración lobar frontotemporal con inclusiones **FUS (+)**

Degeneración lobar frontotemporal FUS

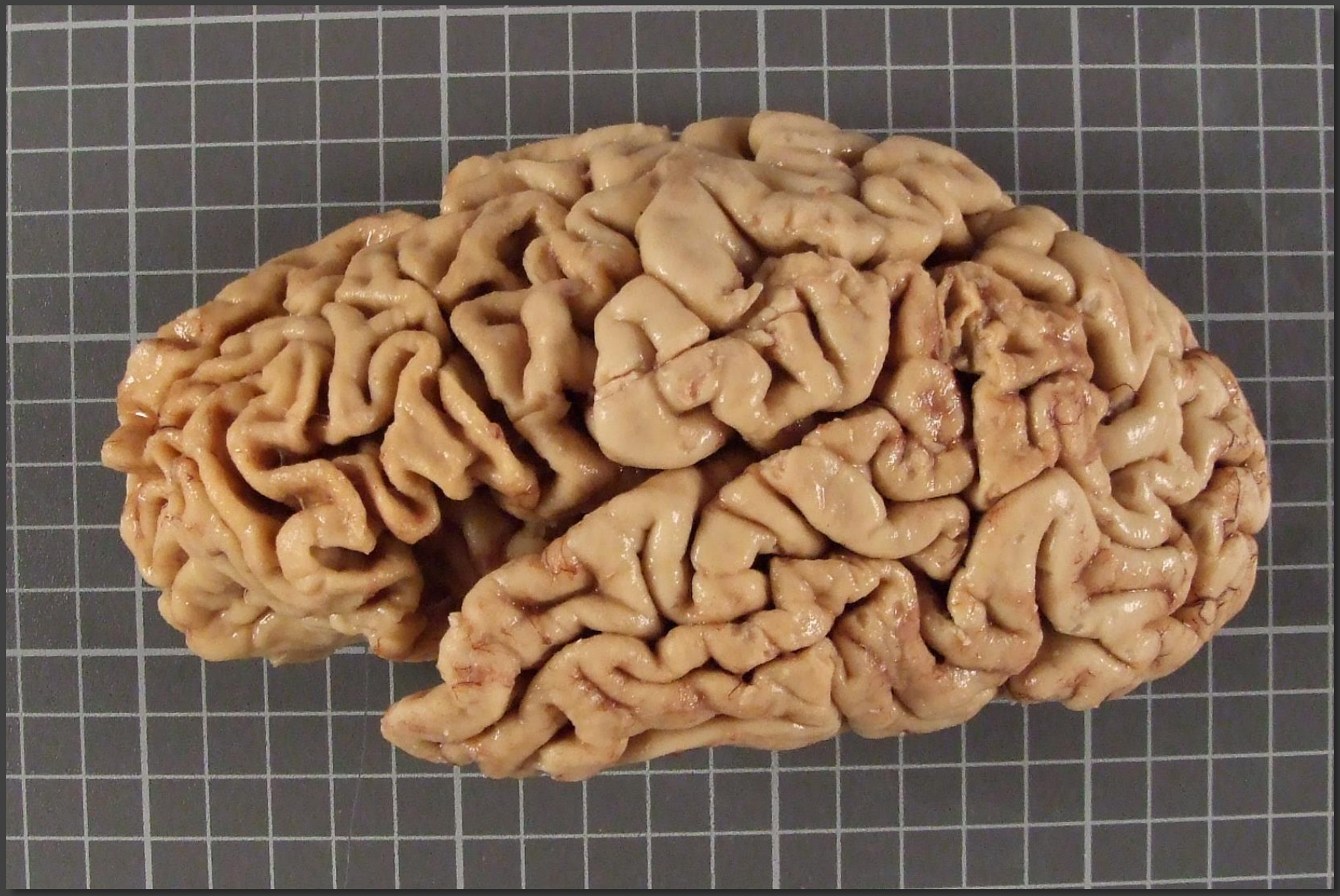

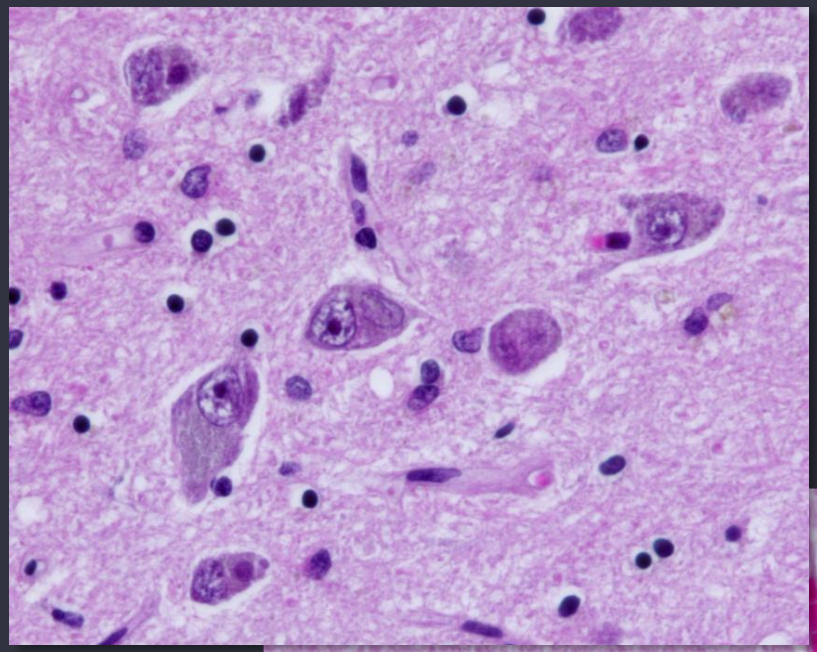

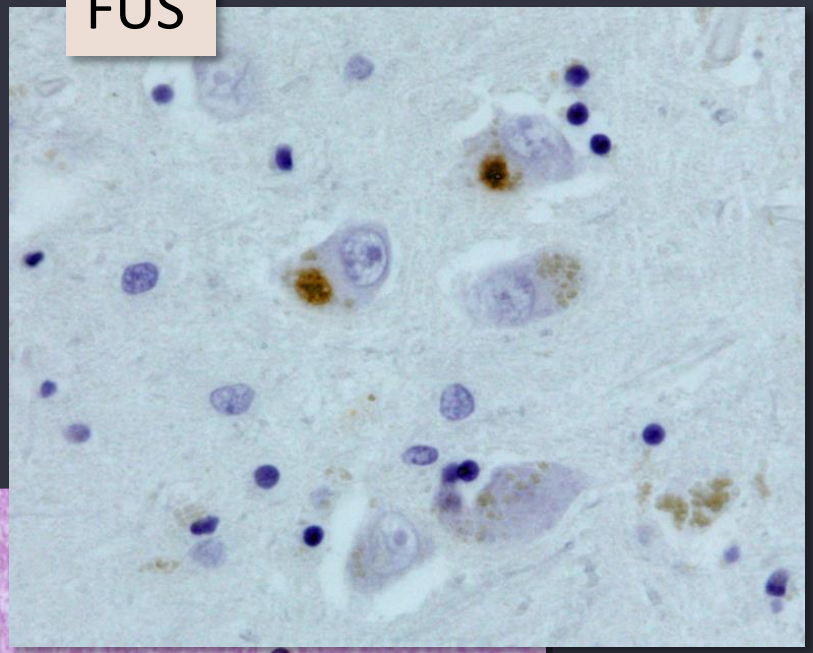
FUS

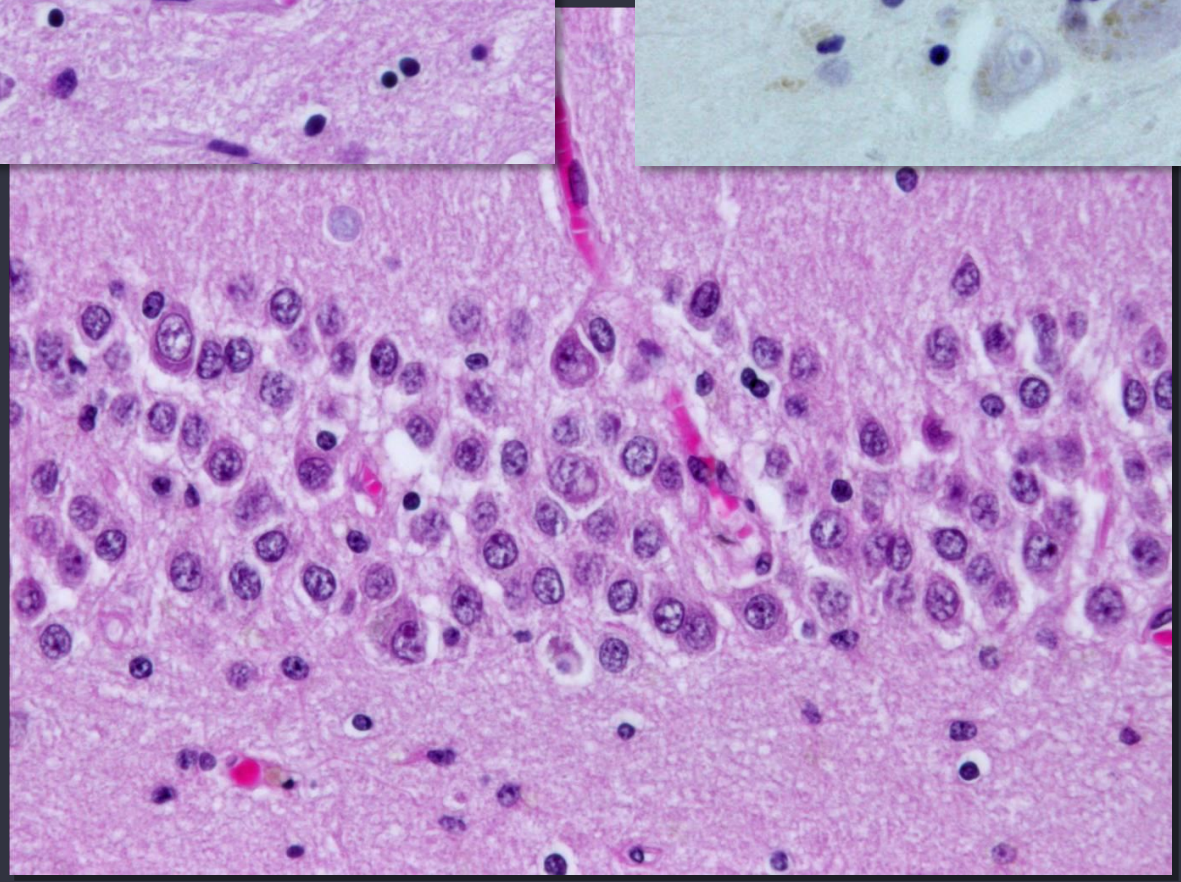

Patología TDP-43 + Tau

Enfermedad de Pick

Tau

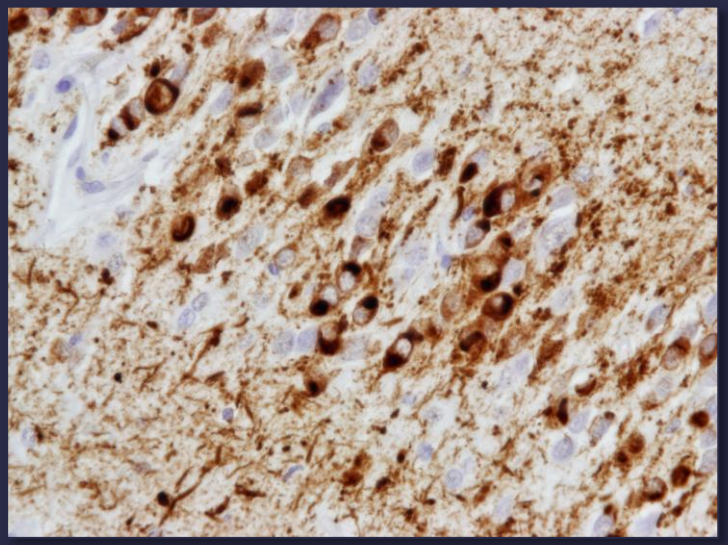

TDP
-43

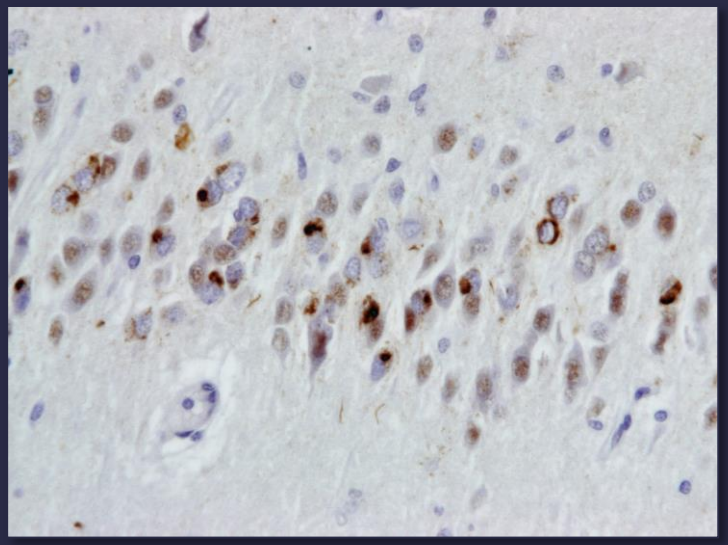

Esclerosis del hipocampo

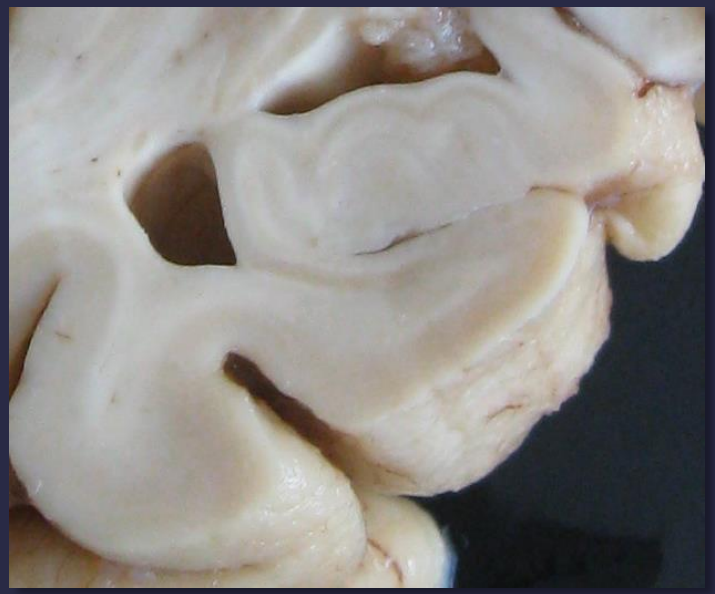

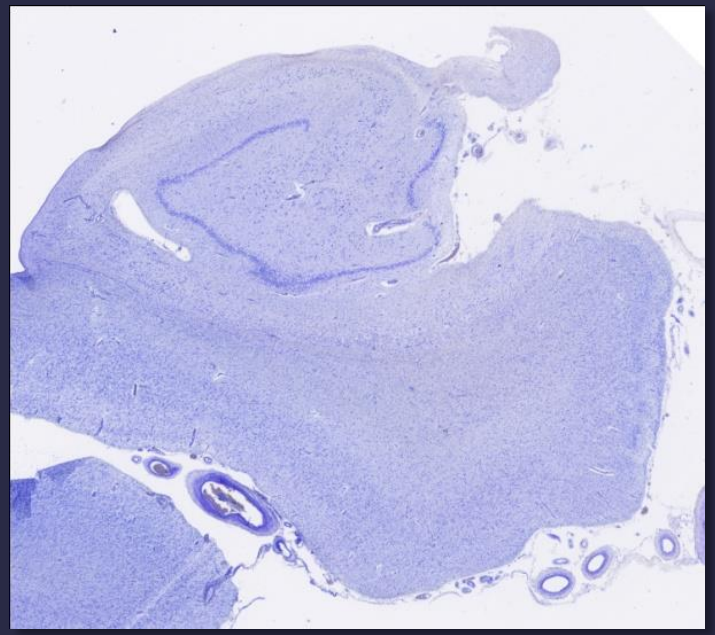

Table 1 Comparison of the overlapping brain regions used in the different TDP-43 staging schemes

	Amyotrophic lateral sclerosis	Behavioural variant frontotemporal dementia	Alzheimer's disease
Number of stages	4	4	5
Amygdala	Stage 3	Stage 1	Stage 1
Orbital cortex, gyrus rectus	Stage 3	Stage 1	Not assessed
Inferior olive, parvocellular red nucleus	Stage 2	Stage 2	Not assessed
Entorhinal cortex	Stage 4	Stage 2	Stage 2
Hippocampal dentate gyrus	Stage 4	Stage 2	Stage 3
Inferior temporal cortex	Stage 4	Stage 2	Stage 4
Prefrontal cortex	Stage 3	Stage 2	Stage 5
Hypoglossal nucleus, motor cortex	Stage 1	Stage 3	Not assessed
Substantia nigra, locus coeruleus	Stage 2	Stage 4	Not assessed

Comparison is shown for amyotrophic lateral sclerosis (Brettschneider *et al.*, 2014), behavioural variant FTD (Brettschneider *et al.*, 2013) and Alzheimer's disease (Josephs *et al.*, 2014*a*), and the stage indicated (by increasing shading) if pathology is observed in the brain region.

Tan RH *et al.*, *Brain* 2015

Stage 1	Stage 2	Stage 3	Stage 4	Stage 5	Stage 6
• Amygdala	• Entorhinal • Subiculum	• Dentate • OTC	• Insula • Ventral striatum • Basal forebrain • Inferior temporal	• Substantia nigra • Inferior olive • Midbrain tectum	• Basal ganglia • Middle frontal

Josephs KA et al., Acta Neuropathol. 2016

¡Gracias!

btcïen
Banco de Tejidos de la Fundación Cien

Web:
http://bt.fundacioncien.es/

Twitter:
@banco_tx_CIEN