NEUROPATOLOGÍA DE LA ENFERMEDAD DE PARKINSON:

DE LEWY A BRAAK

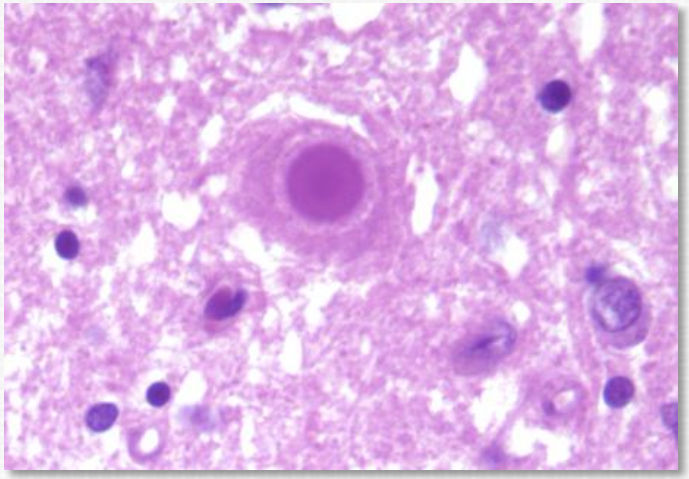

Alberto Rábano
Banco de Tejidos CIEN
Fundación CIEN, ISCIII

Entidades C-P con patología de Lewy

- Enfermedad de Parkinson idiopática (+ EP con Demencia)
- Demencia con cuerpos de Lewy

LBD

- Enfermedad de Parkinson familiar (*)
- Fallo autonómico
- Disfagia con cuerpos de Lewy

Goedert, M. *et al. Nat. Rev. Neurol.* **9**, 13–24 (2013);

REVIEWS

100 years of Lewy pathology

Michel Goedert, Maria Grazia Spillantini, Kelly Del Tredici and Heiko Braak

F. H. Lewy (Lewey) & Company

- **1912-1913:** Descripción de los cuerpos y neuritas "de Lewy" (*Handbuch der Neurologie*), en el n. motor dorsal del n. vago, el n. basalis de Meynert, el globo pálido, el n. lateral y el n. periventricular del tálamo.
- **1919:** K. Tretiakoff describe la presencia de cuerpos de Lewy (crea el epónimo) en la s. nigra, y la degeneración neuronal.
- **1923:** Lewy confirma parcialmente los hallazgos de Tretiakoff (11 de 50 casos).
- **1938:** R. Hassler establece la relación entre la degeneración de la s. nigra y el parkinsonismo.

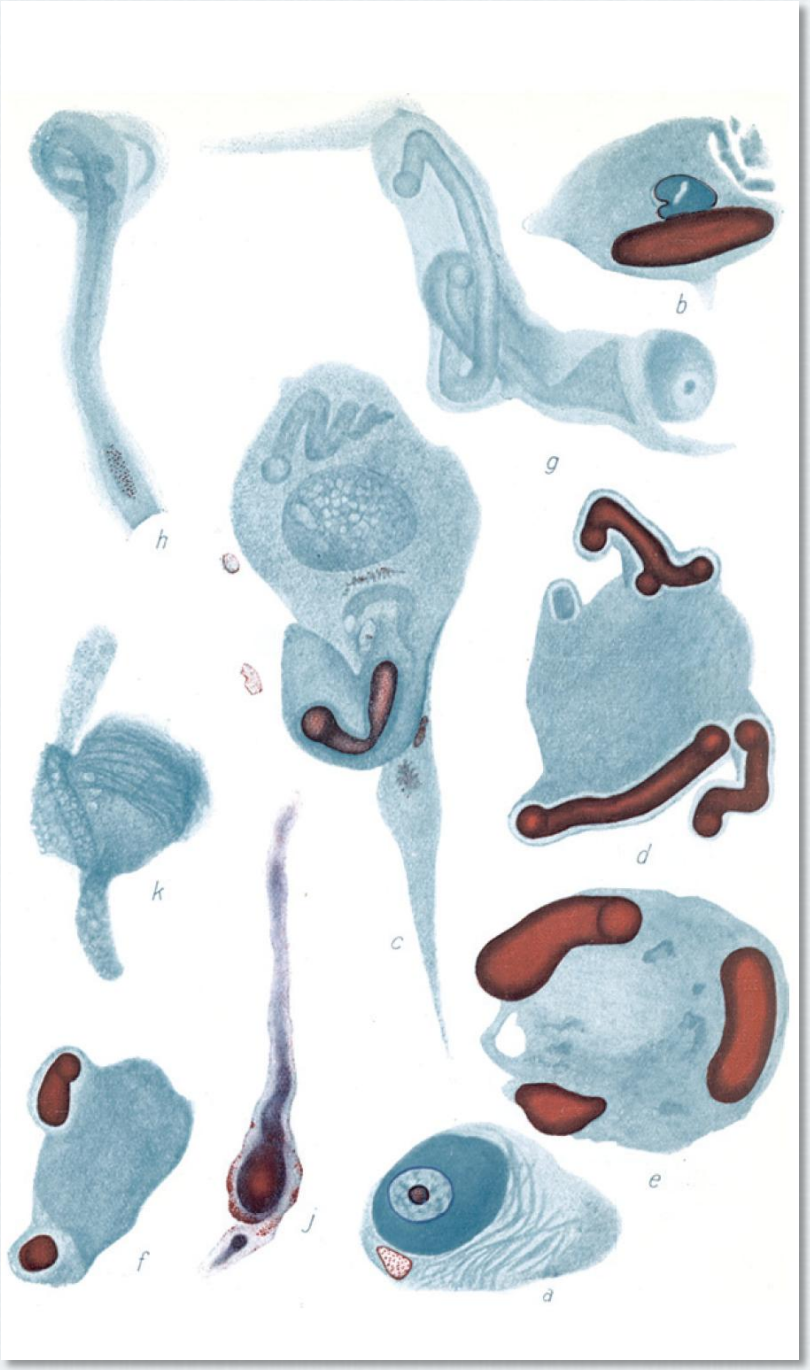

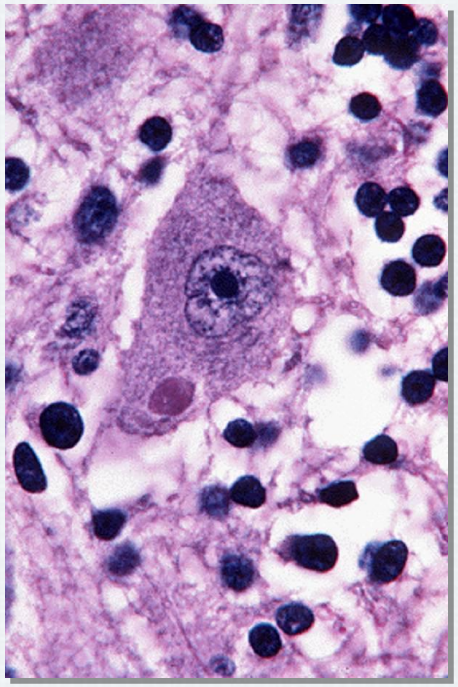

Cuerpo de Negri

E. de Parkinson, n. motor dorsal del n. vago
F.H. Lewy, 1923

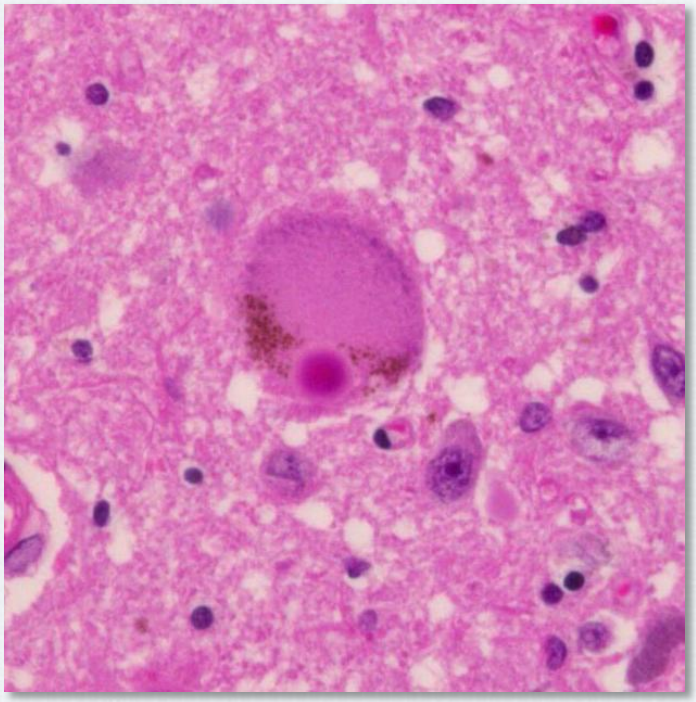

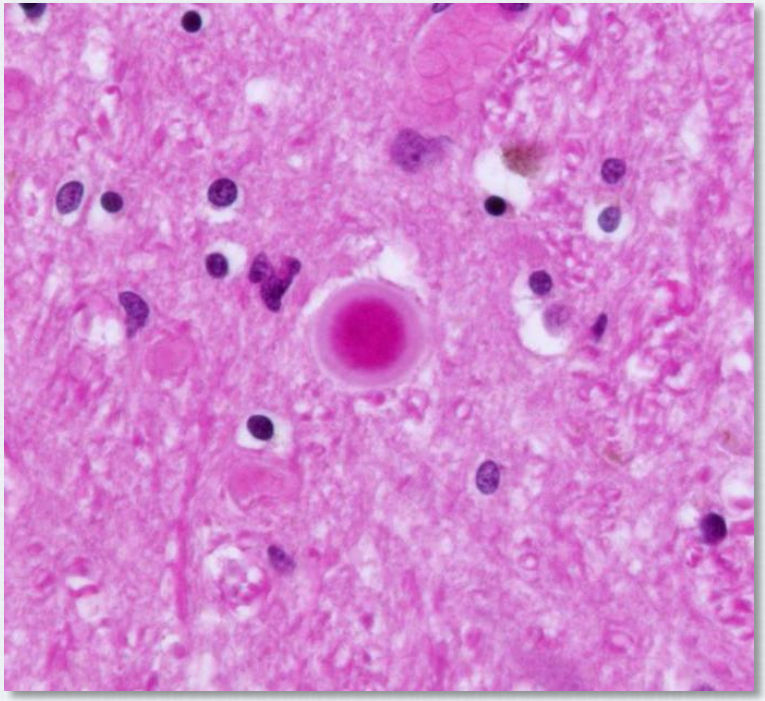

Cuerpos de Lewy (8-30 µ), hematoxilina-eosina

Cuerpo pálido

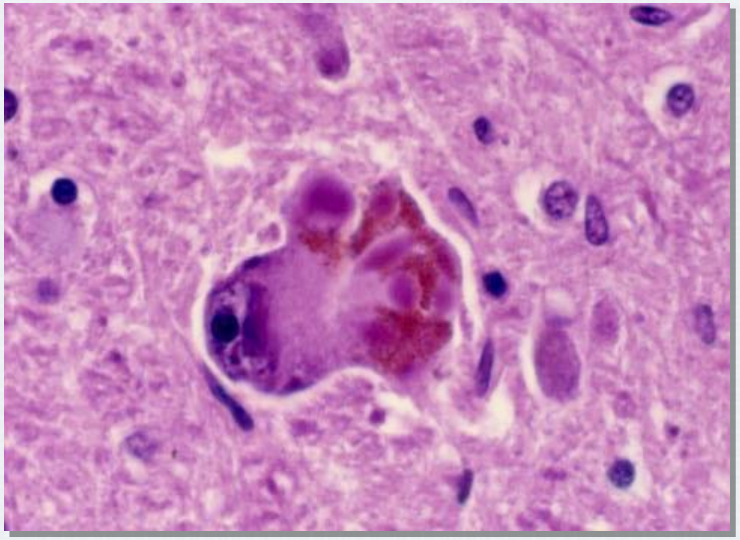

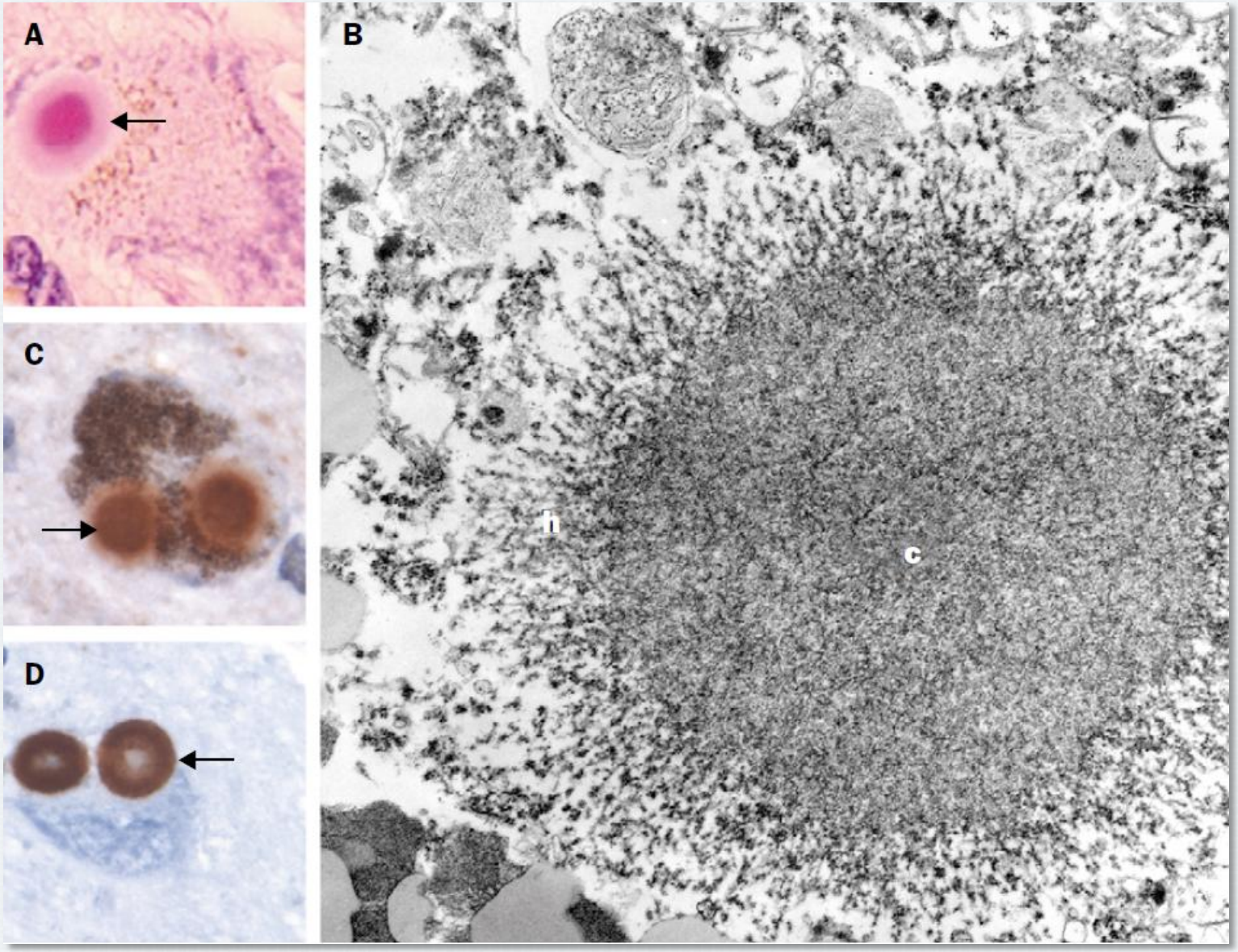

Olanow et al., 2004

J. Neurol. Neurosurg. Psychiat., 1960, 23, 74.

THE INCIDENCE AND CHARACTERISTICS OF LEWY BODIES IN IDIOPATHIC PARALYSIS AGITANS (PARKINSON'S DISEASE)

BY

J. BETHLEM and W. A. DEN HARTOG JAGER

From the Neurological Clinic, University of Amsterdam

FINDING OF LEWY BODIES ABSTRACTED FROM THE LITERATURE

Authors	Idiopathic Paralysis Agitans		Post-encephalitic Parkinsonism		Control Cases	
	No. of Cases	Lewy Bodies	No. of Cases	Lewy Bodies	No. of Cases	Lewy Bodies
Trétiakoff (1919)	9	6	3	0	—	—
Redlich (1930)	1	1	2	2	—	—
van Valkenburg (1941)	1	1	—	—	—	—
Beheim-Schwarzbach (1952)	16	16	13	0	30	10
Greenfield and Bosanquet (1953)	19	19	10	0	22	0
Röveti (1956)	—	—	8	0	15	2
Total	46	43	36	2	67	12

INCIDENCE OF LEWY INCLUSIONS

No.	Sex	Age	Locus Coeruleus	Substantia Nigra	Substantia Innominata
Idiopathic Paralysis Agitans					
458	M	59	+	+	+
477	F	60	+	+	+
478	F	61	+	+	+
509	M	74	+	+	—
510	M	73	+	+	—
519	F	76	+	+	—
524	M	71	+	+	+
533	M	82	+	+	—
534	M	88	+	+	+
555	F	73	+	+	—
556	F	63	+	+	+
561	F	72	+	+	+
490	F	72	+	Used	+
501	F	75	+	for other	+
516	M	79	+	purposes	—
Post-encephalitic Parkinsonism					
446	M	60	—	—	—
447	M	68	—	—	—
568	M	37	—	—	—
569	F	57	—	—	—

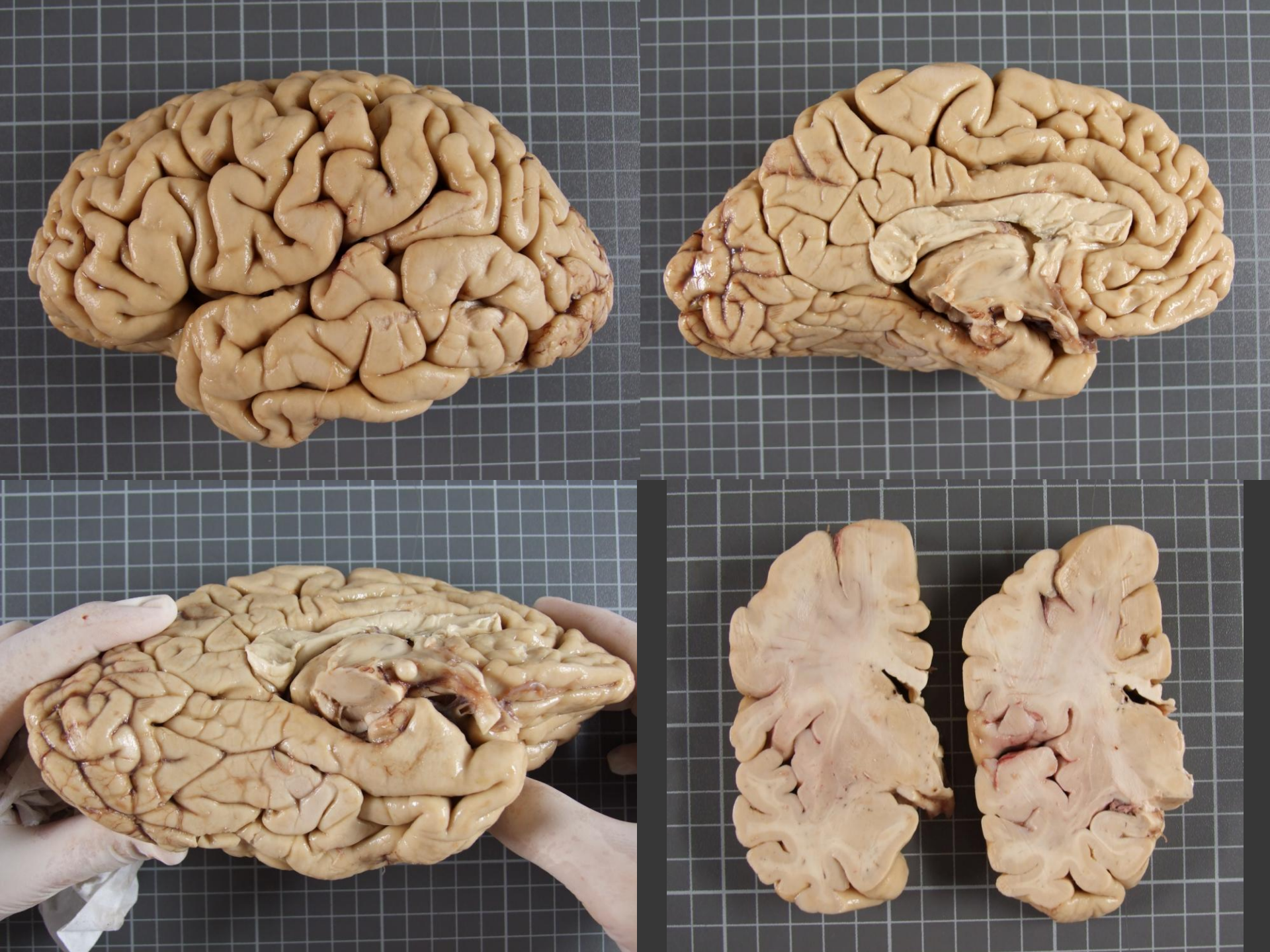

Parálisis supranuclear progresiva

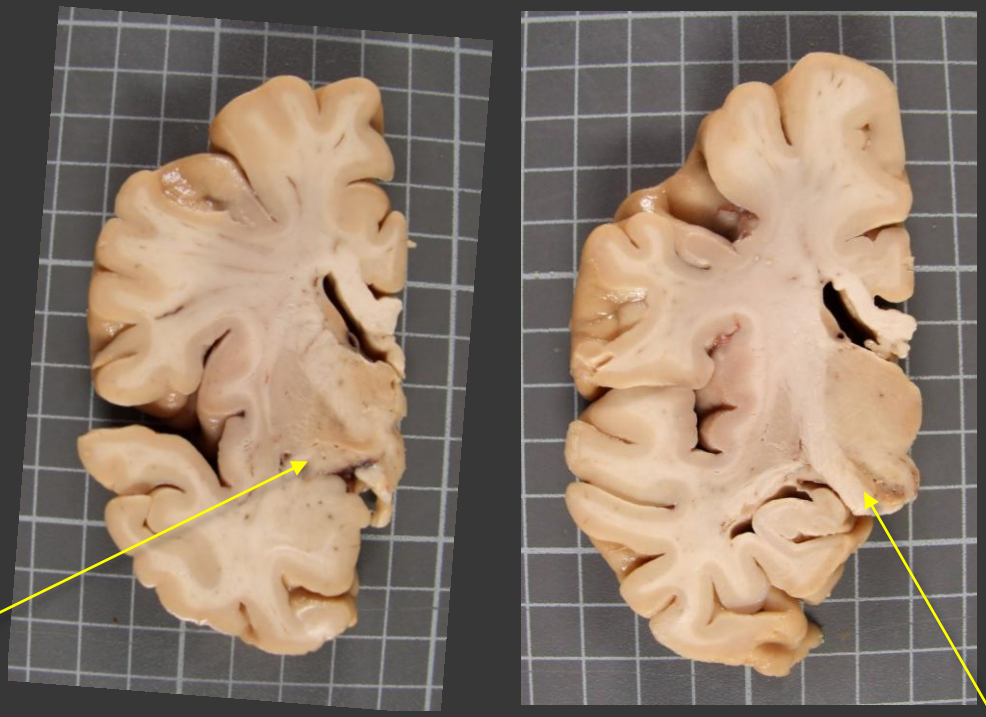

Globo pálido

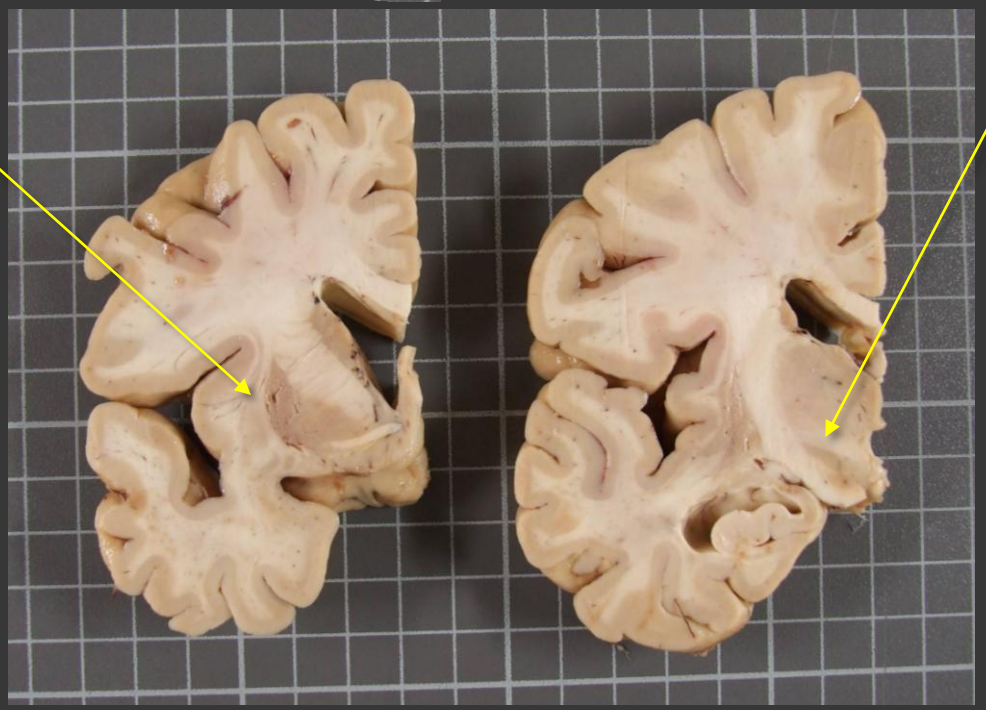

Putamen

N. subtalámico

Atrofia multisistémica

Sustancia nigra, hematoxilina - eosina

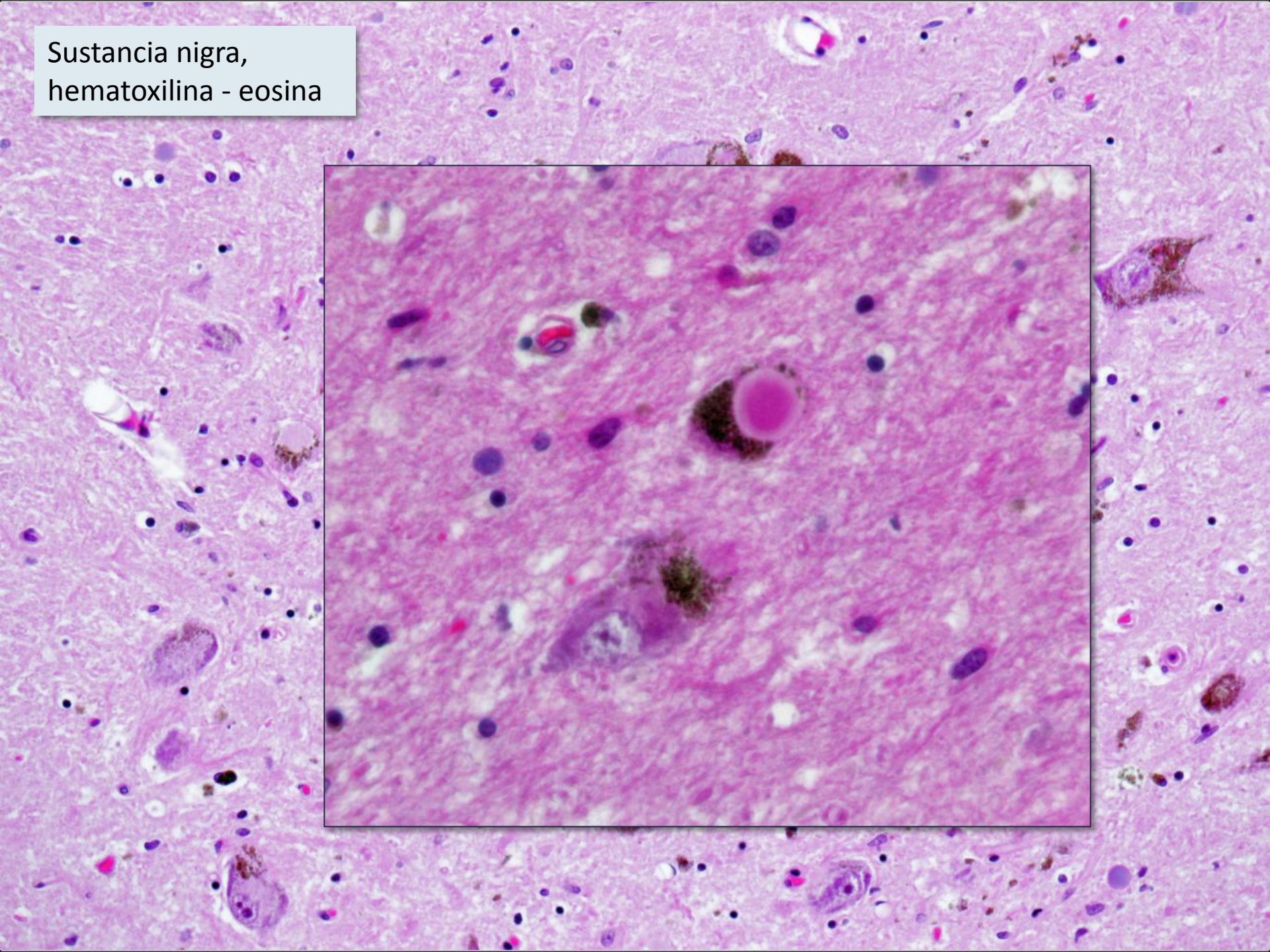

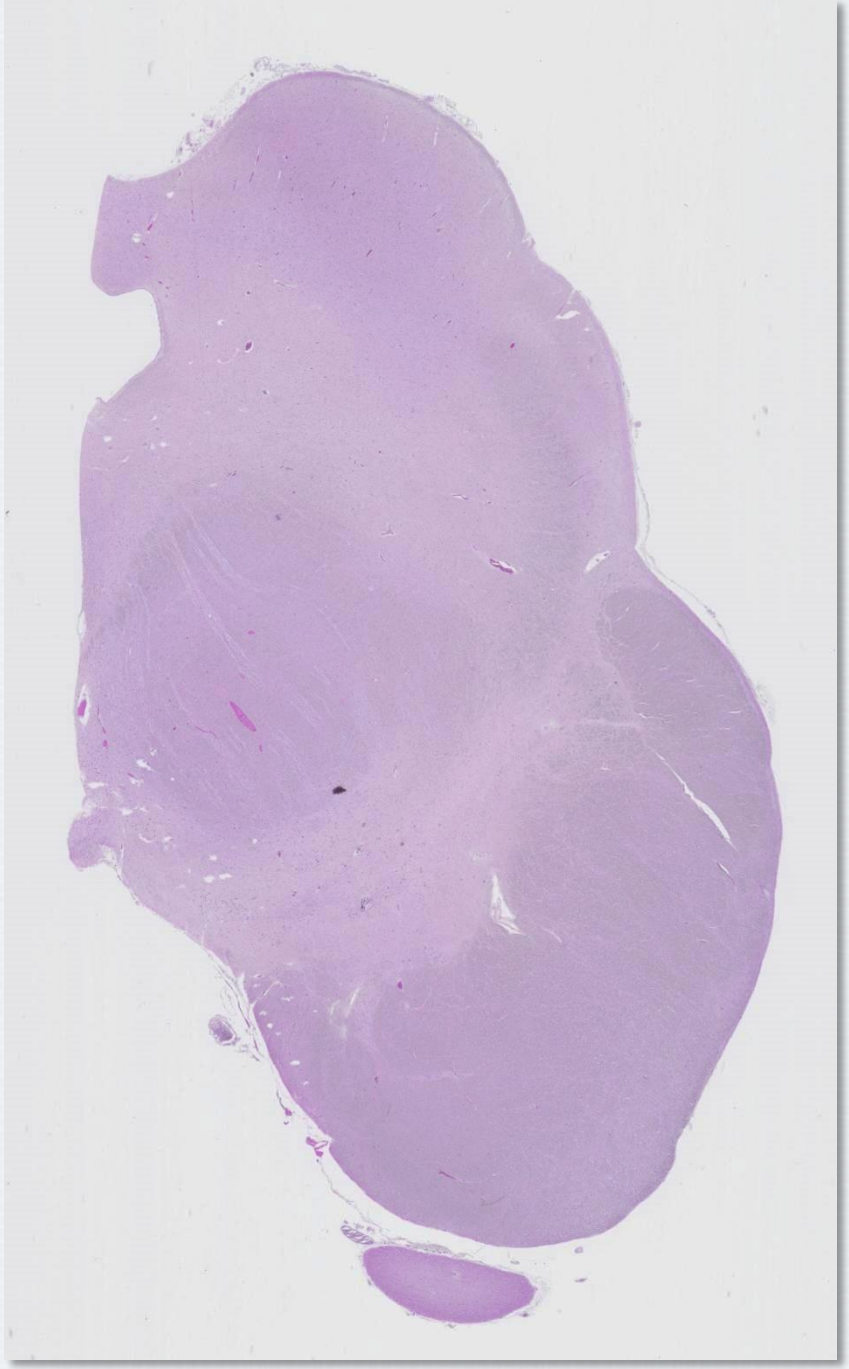

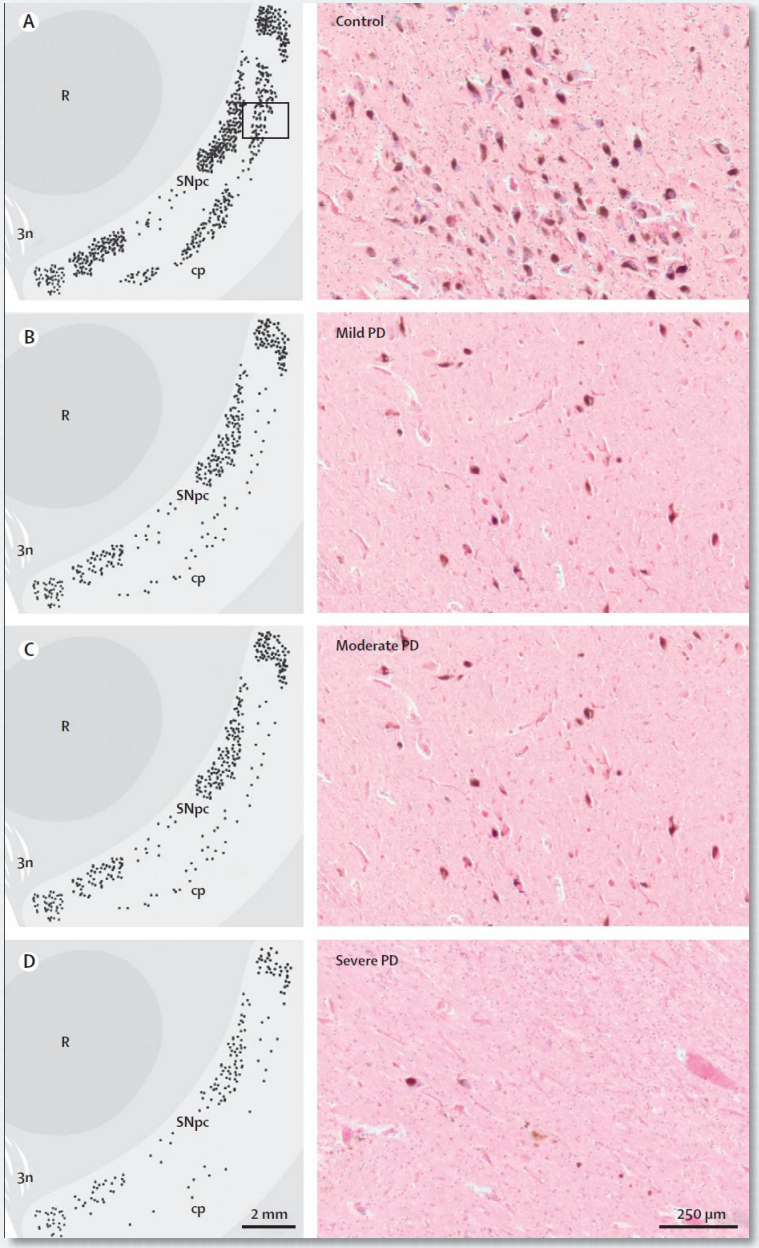

Dickson et al., 2009

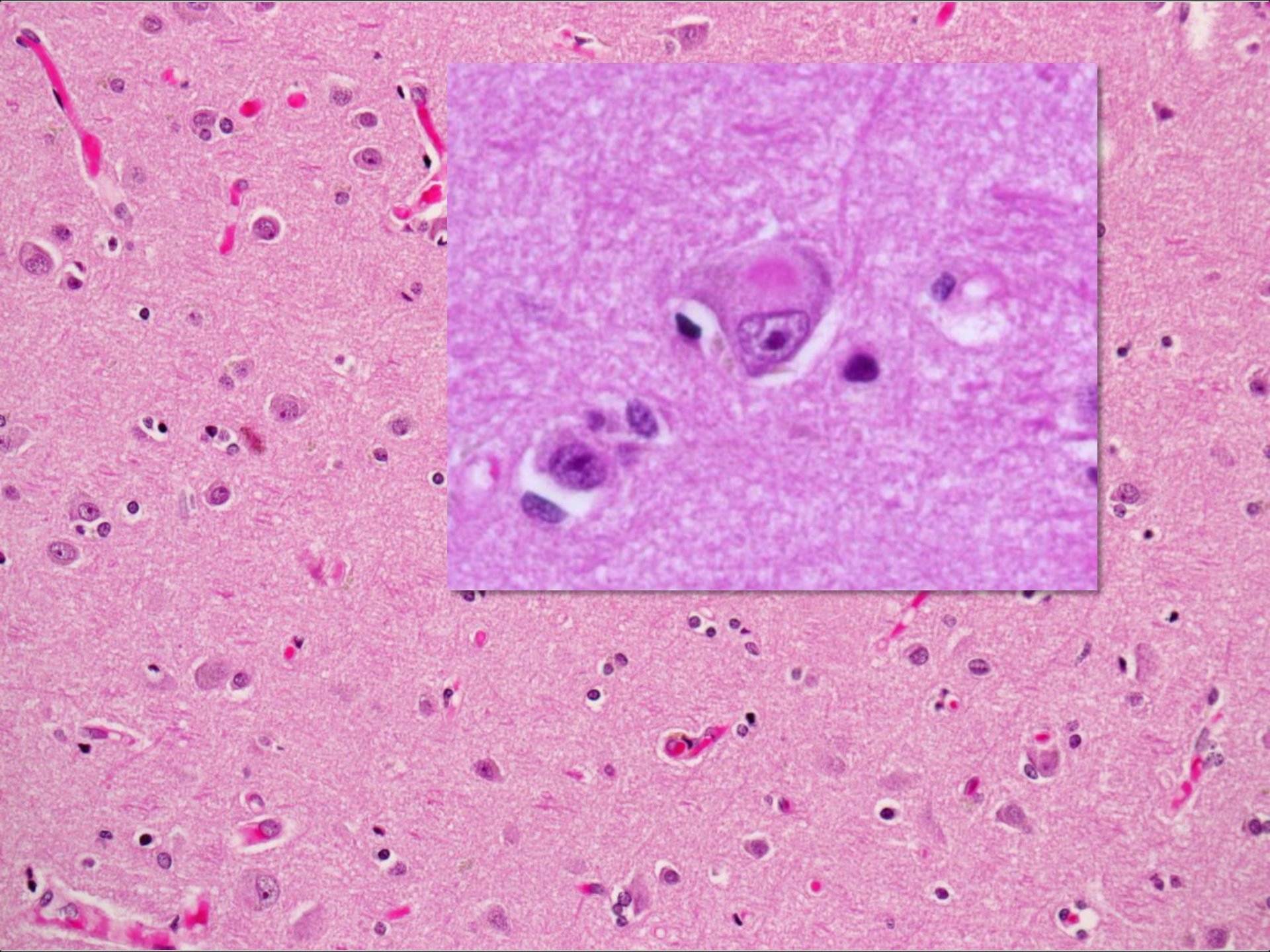

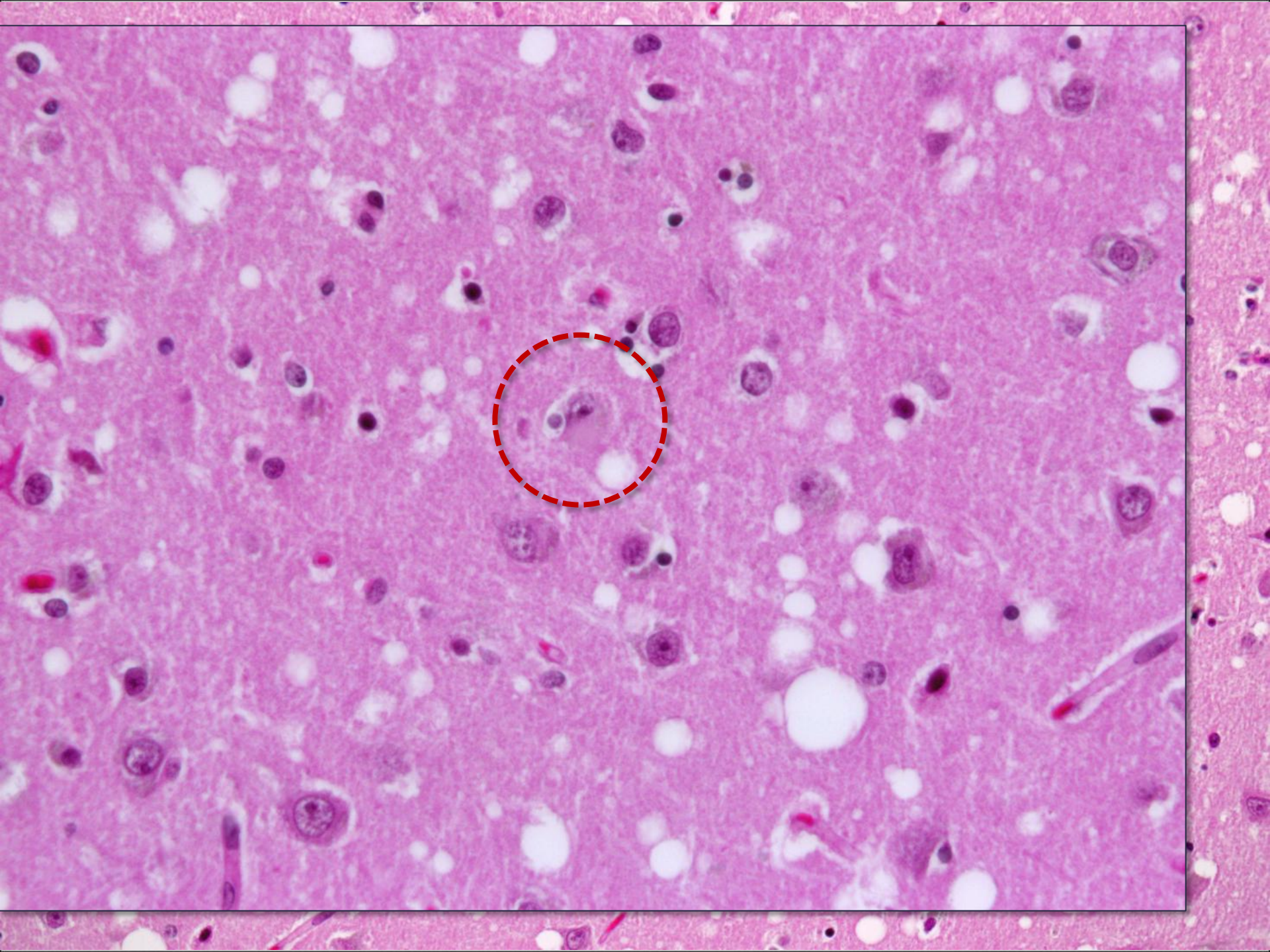

Mutation in the α-Synuclein Gene Identified in Families with Parkinson's Disease

Mihael H. Polymeropoulos,* Christian Lavedan†, Elisabeth Leroy†, Susan E. Ide, Anindya Dehejia, Amalia Dutra, Brian Pike, Holly Root, Jeffrey Rubenstein, Rebecca Boyer, Edward S. Stenroos, Settara Chandrasekharappa, Aglaia Athanassiadou, Theodore Papapetropoulos, William G. Johnson, Alice M. Lazzarini, Roger C. Duvoisin, Giuseppe Di Iorio, Lawrence I. Golbe, Robert L. Nussbaum

www.sciencemag.org • SCIENCE • VOL. 276 • 27 JUNE 1997

```
                10        20        30
                 |         |         |
1   MDVFMKGLSKAKEGVVAAAEKTKQGVAEAAGKT----------KEGVLY  Homo sapiens
1   MDVFMKGLSKAKEGVVAAAEKTKQGVAEAAGKT----------KEGVLY  Rattus norvegicus
1   MDVFMKGLSMAKEGVVAAAEKTKQGVTEAAEKT----------KEGVLY  Bos taurus
1   MDVFMKGLSKAKEGVVAAAEKTKQGVAEAAGKT----------KEGVLY  Serinus canaria
1   MDVLKKGFSFAKEGVVAAAEKTKQGVQDAAEKTKQGVQDAAEKTKEGVMY  Torpedo californica

    40        50        60        70        80
     |         |         |         |         |
40  VGSKTKEGVVHGVATVAEKTKEQVTNVGGAVVTGVTAVAQKTVEGAGSIA  Homo sapiens
40  VGSKTKEGVVHGVTTVAEKTKEQVTNVGGAVVTGVTAVAQKTVEGAGNIA  Rattus norvegicus
40  VGSKTKEGVVQGVASVAEKTKEQASHLGGAVFSGAG----------NIA  Bos taurus
40  VGSRTKEGVVHGVTTVAEKTKEQVSNVGGAVVTGVTAVAQKTVEGAGNIA  Serinus canaria
51  VGTKTKEGVVQSVNTVTEKTKEQANVVGGAVVAGVNTVASKTVEGVENVA  Torpedo californica

    90       100       110       120
     |         |         |         |
90  AATGFVKKDQLGK-N--EEGAPQ--EGI---LED--MPVDPDNEAYEMPS  Homo sapiens
90  AATGFVKKDQMGK-G--EEGYPQ--EGI---LED--MPVDPSSEAYEMPS  Rattus norvegicus
79  AATGLVKKEEFPT-DLKPEEVAQ--EAAEEPLIE--PLMEPEGESYEEQP  Bos taurus
90  AATGLVKKDQLAKQN--EEGFLQ--EGM---VNNTGAAVDPDNEAYEMPP  Serinus canaria
101 AASGVVKLDEHGR-EIPAEQVAEGKQTTQEPLVE--ATEATE--------  Torpedo californica

    130       140
     |         |
130 EEGYQDYEPEA                                         Homo sapiens
130 EEGYQDYEPEA                                         Rattus norvegicus
124 QEEYQEYEPEA                                         Bos taurus
133 EEEYQDYEPEA                                         Serinus canaria
140 -------ETGK                                         Torpedo californica
```

	PARK designation	Chromosome location	Most common phenotype
α-synuclein pathology			
SNCA	*PARK1/4*	4q21	Parkinson's disease, dementia with Lewy bodies
*LRRK2**	*PARK8*	12q12	Parkinson's disease
GBA	..	1q21	Gaucher's disease (homozygous) and Parkinson's disease (heterozygous)
PANK2	..	20p13–p12.3	NBIA1
PLA2G6	..	22q13.1	NBIA2
Non-α-synuclein pathology			
PRKN†	*PARK2*	6q25.2–q27	Early-onset parkinsonism
ATXN2	..	12q24	SCA2
ATXN3	..	14q24.3–q31	SCA3 (Machado–Joseph disease)
MAPT	..	17q21.1	FTDP-17
GRN	..	17q21.32	FTLD-TDP
DCTN1	..	2p13	Perry syndrome
Pathology to be determined			
ATP13A2	*PARK9*	22q13.1	Kufor–Rakeb syndrome
UCHL1	*PARK5*	4p14	Parkinson's disease
DJ1	*PARK7*	1p36	Early-onset parkinsonism
PINK1	*PARK6*	1p36	Early-onset parkinsonism

Dickson et al., 2009

Proc. Natl. Acad. Sci. USA
Vol. 95, pp. 6469–6473, May 1998
Neurobiology

α-Synuclein in filamentous inclusions of Lewy bodies from Parkinson's disease and dementia with Lewy bodies

(ubiquitin/sarkosyl-insoluble filaments/immunoelectron microscopy)

MARIA GRAZIA SPILLANTINI*, R. ANTHONY CROWTHER†, ROSS JAKES†, MASATO HASEGAWA†, AND MICHEL GOEDERT†‡

*Medical Research Council Centre for Brain Repair and Department of Neurology, University of Cambridge, Robinson Way, Cambridge CB2 2PY, United Kingdom; and †Medical Research Council Laboratory of Molecular Biology, Hills Road, Cambridge CB2 2QH, United Kingdom

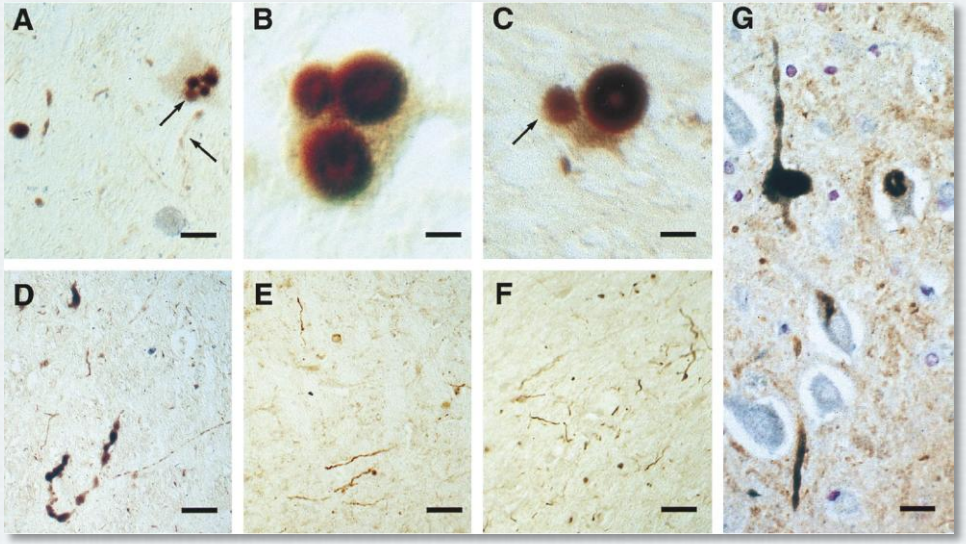

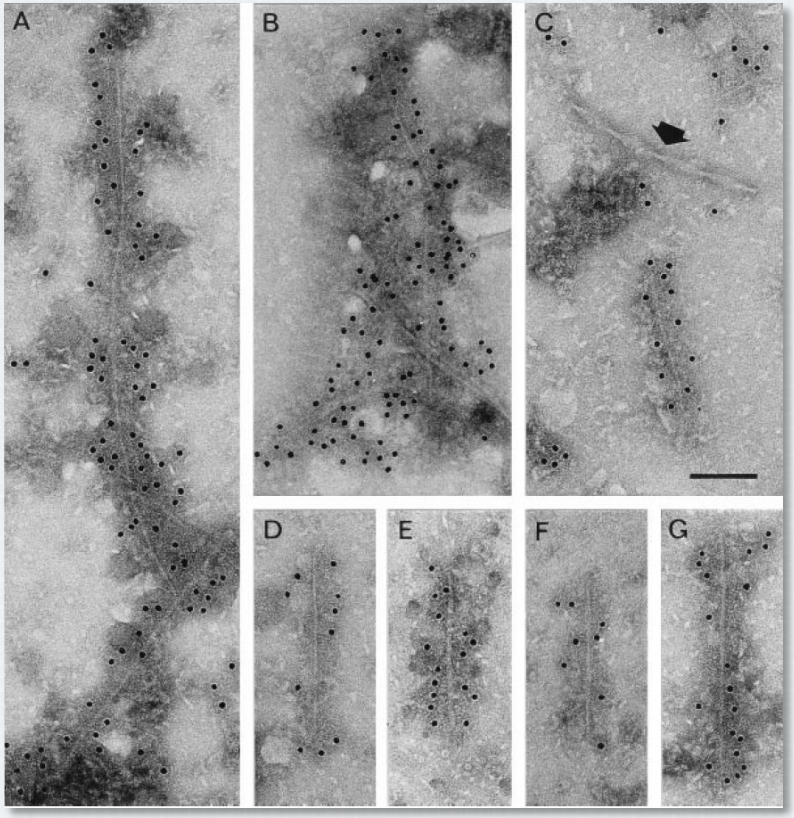

N. Motor dorsal del par X

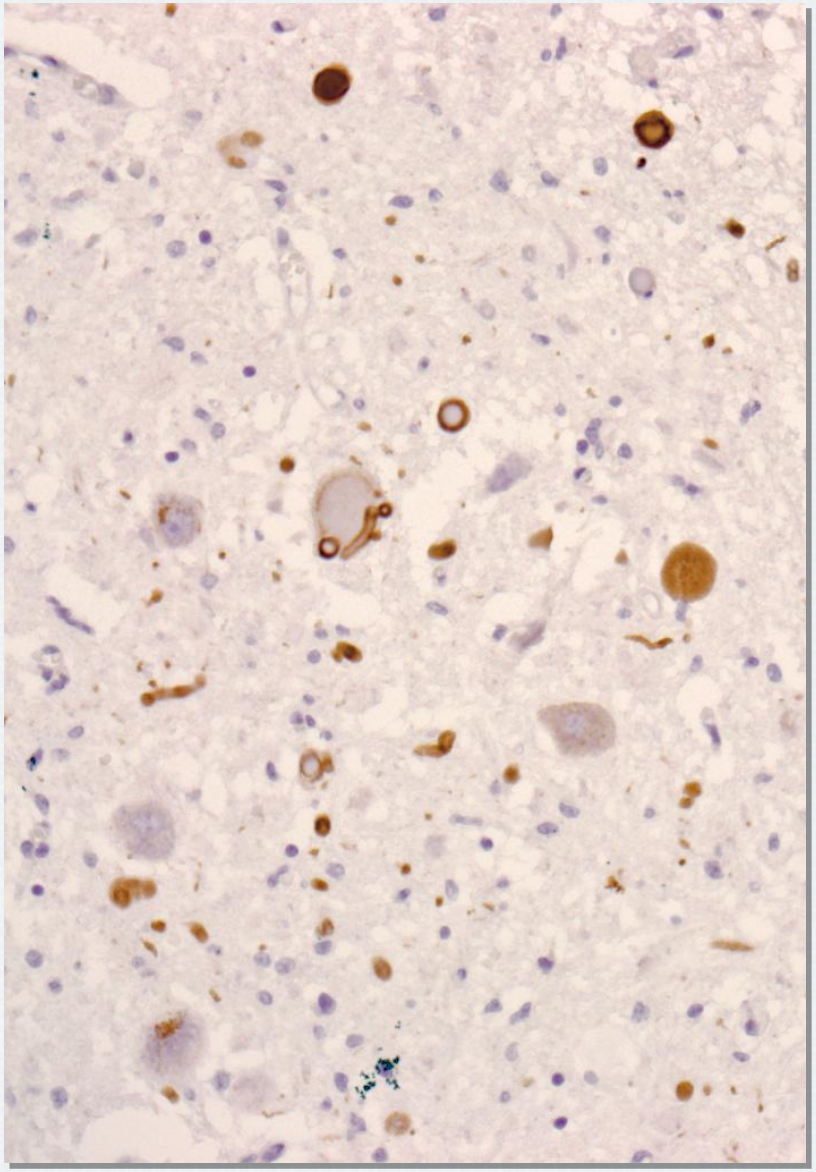

Amígdala

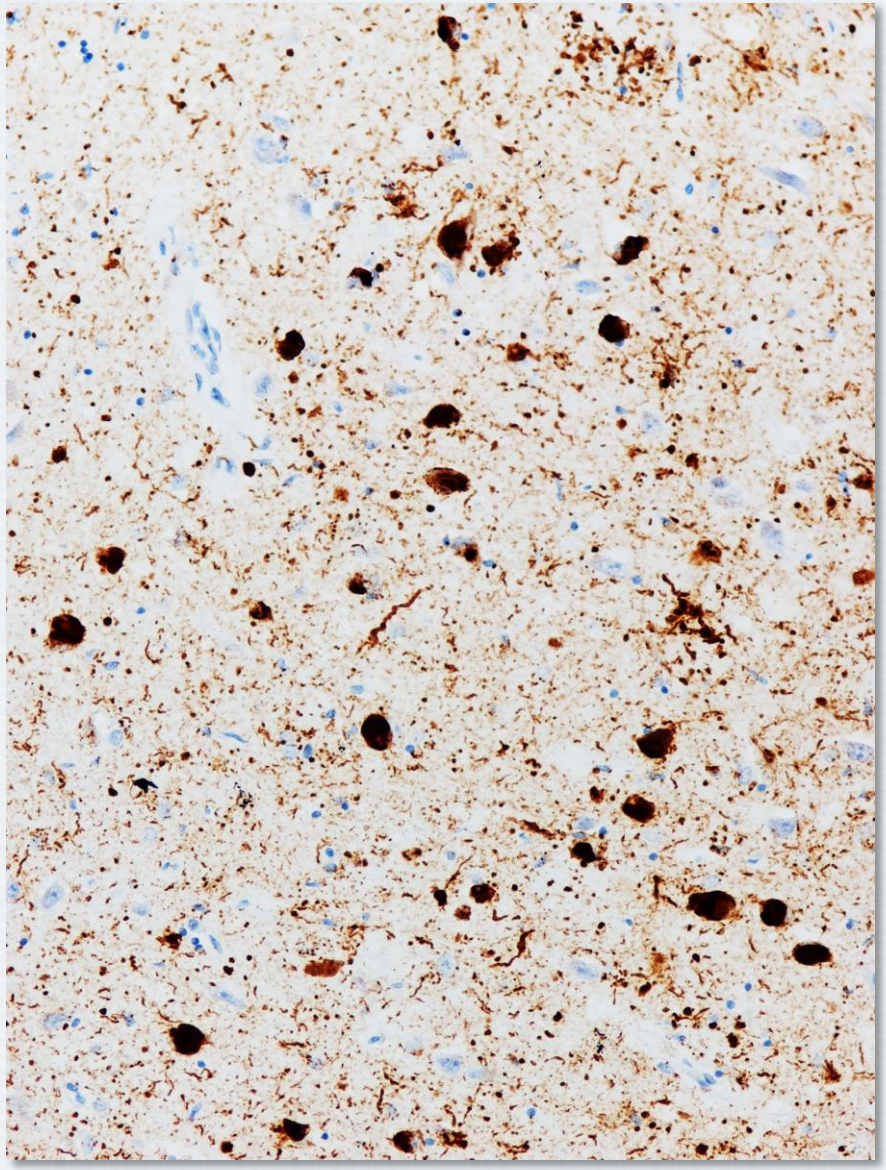

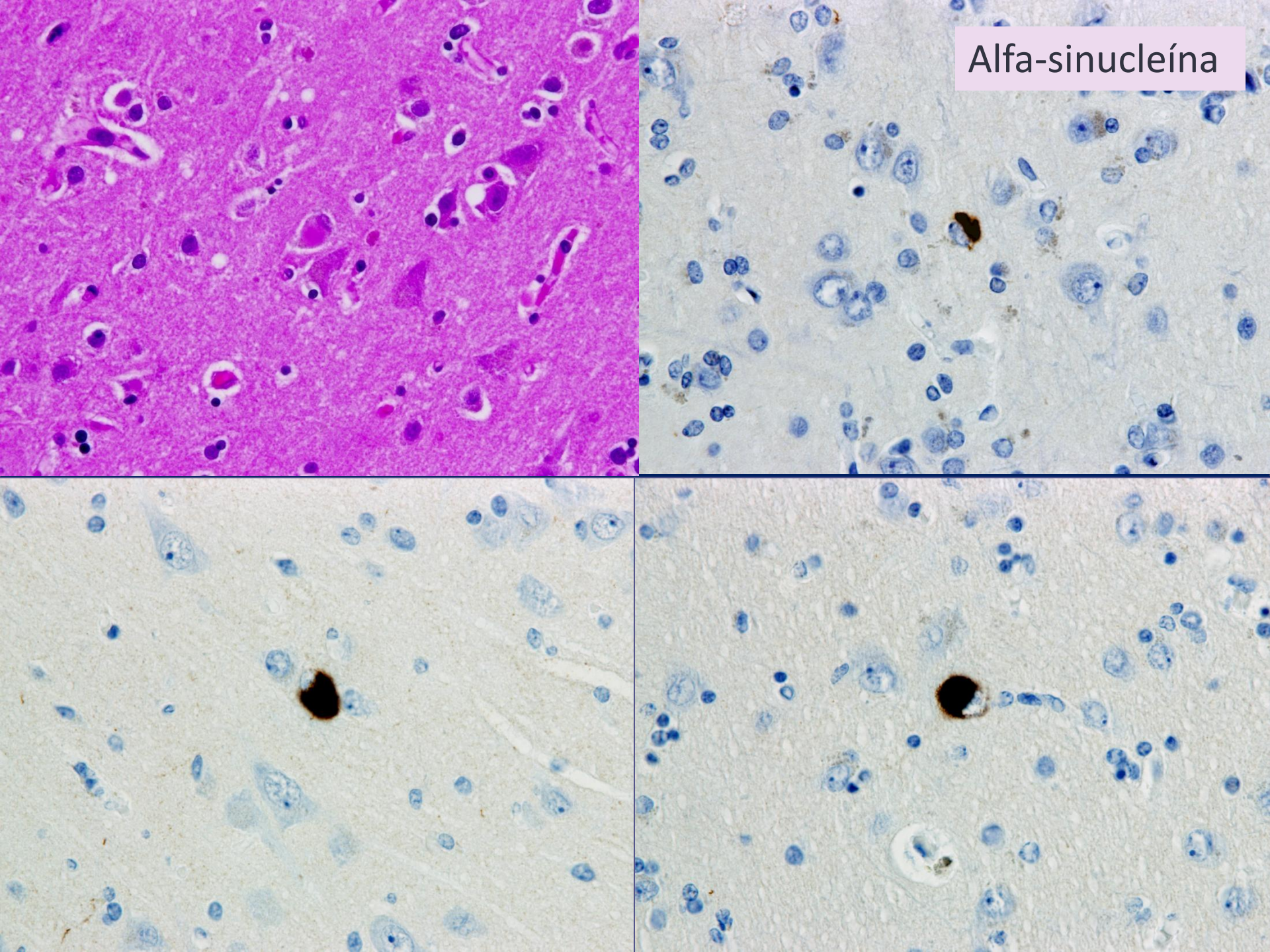
Alfa-sinucleína

Alfa-sinucleína

Córtex cingular

Córtex frontal lateral

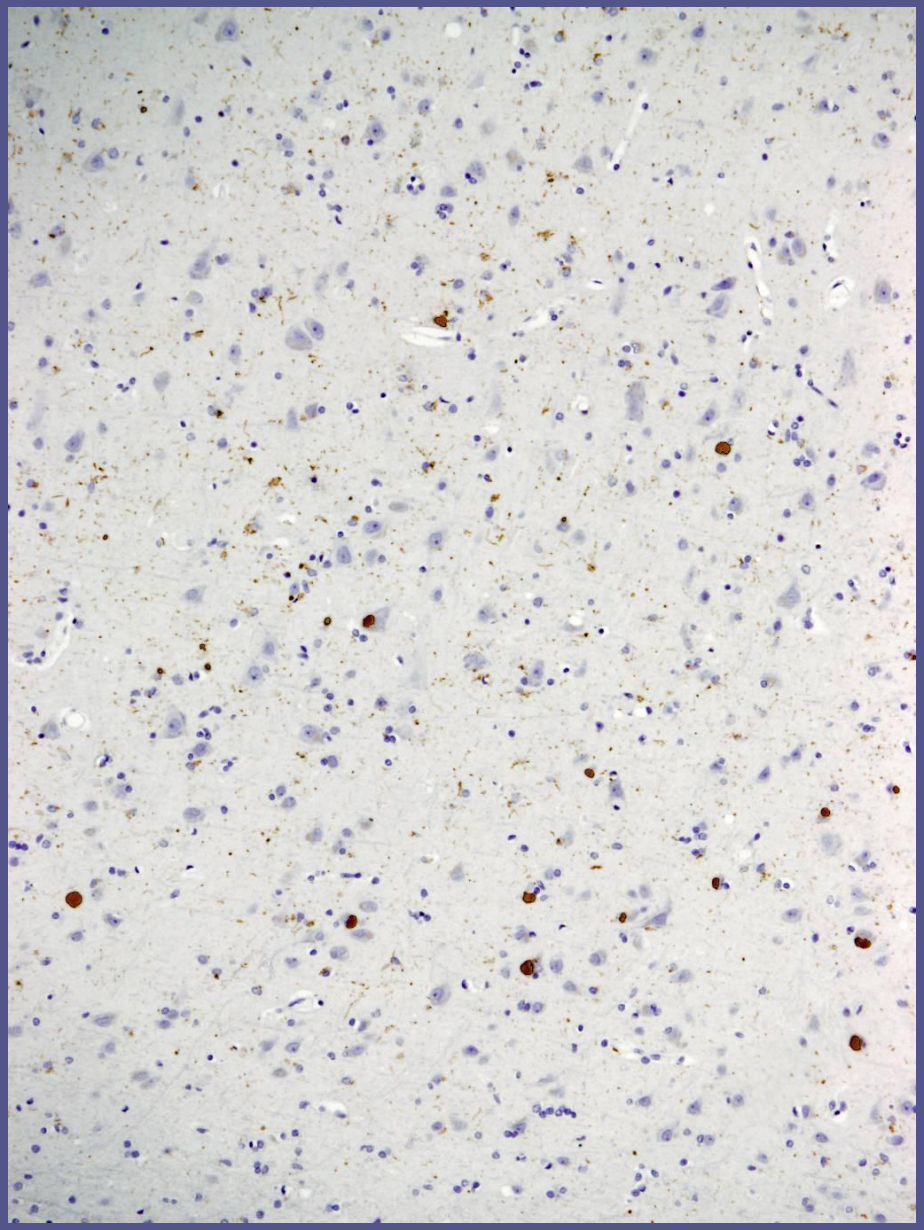

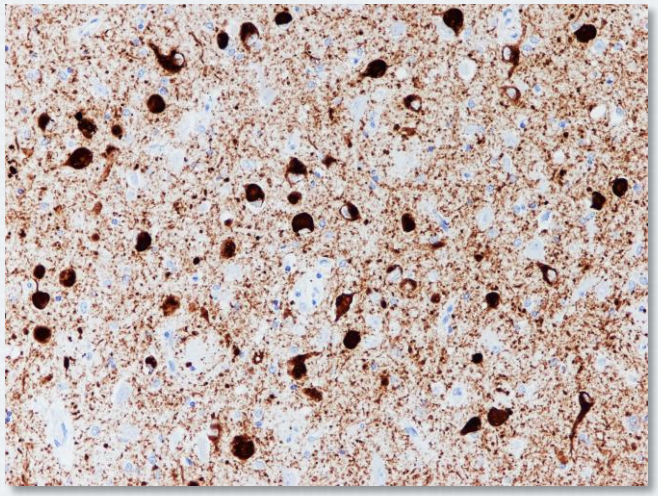

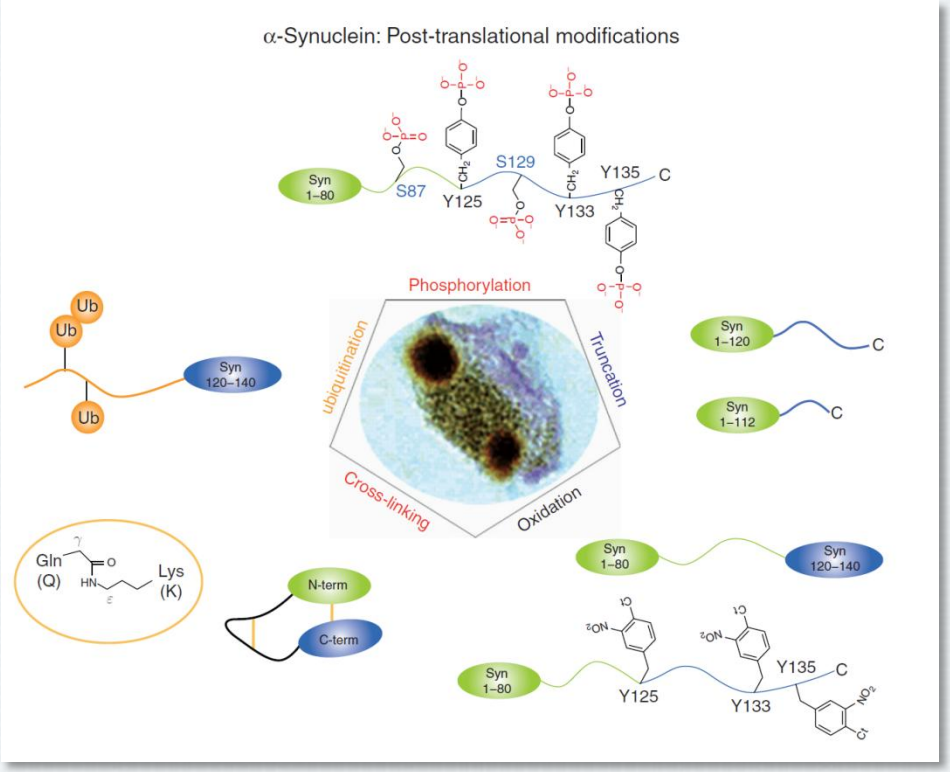

α-sinucleína

Neurofilamentos

Ubiquitina

Sinfilina-1

Torsina A

Componentes del sistema ubiquitina-proteasoma

HSP70

HSP90

Lípidos

Heiko Braak, 1937 -

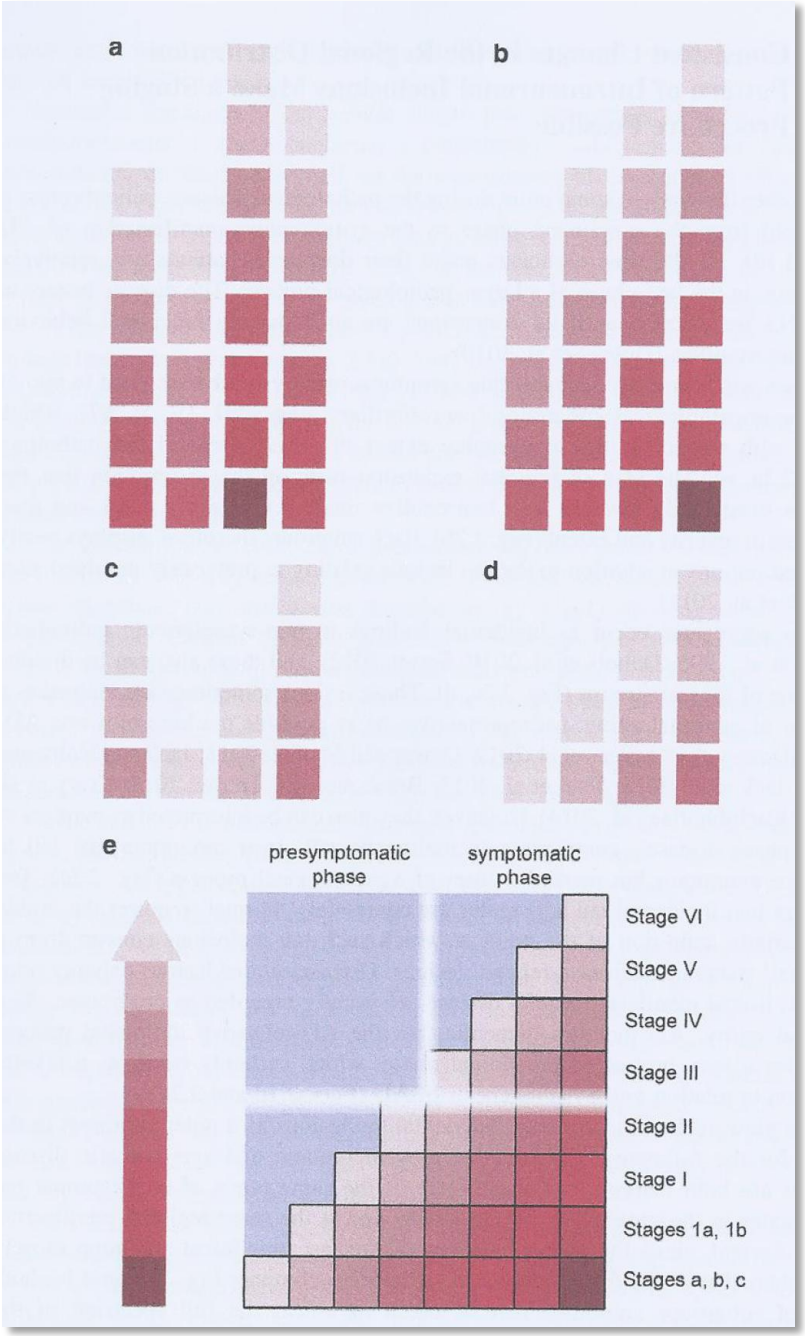

H Braak & K Del Tredici, 2015

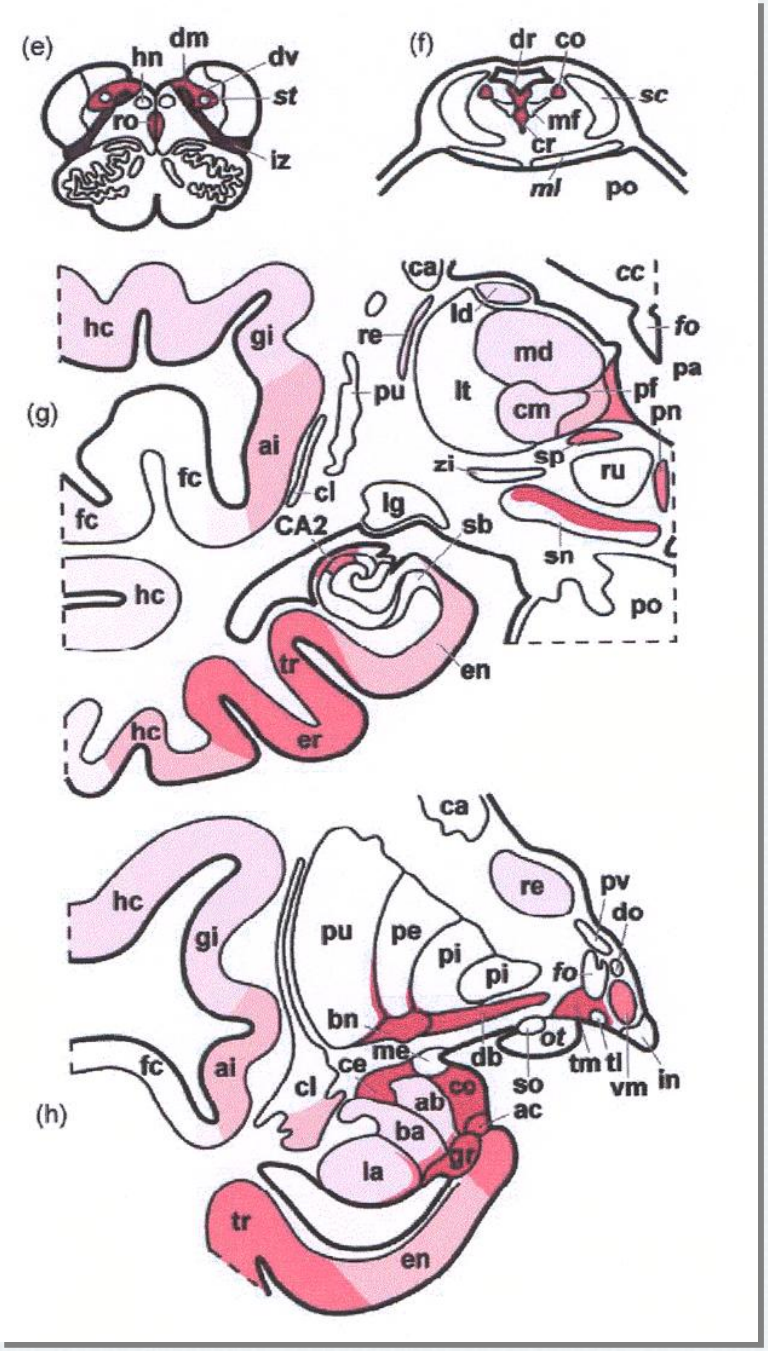

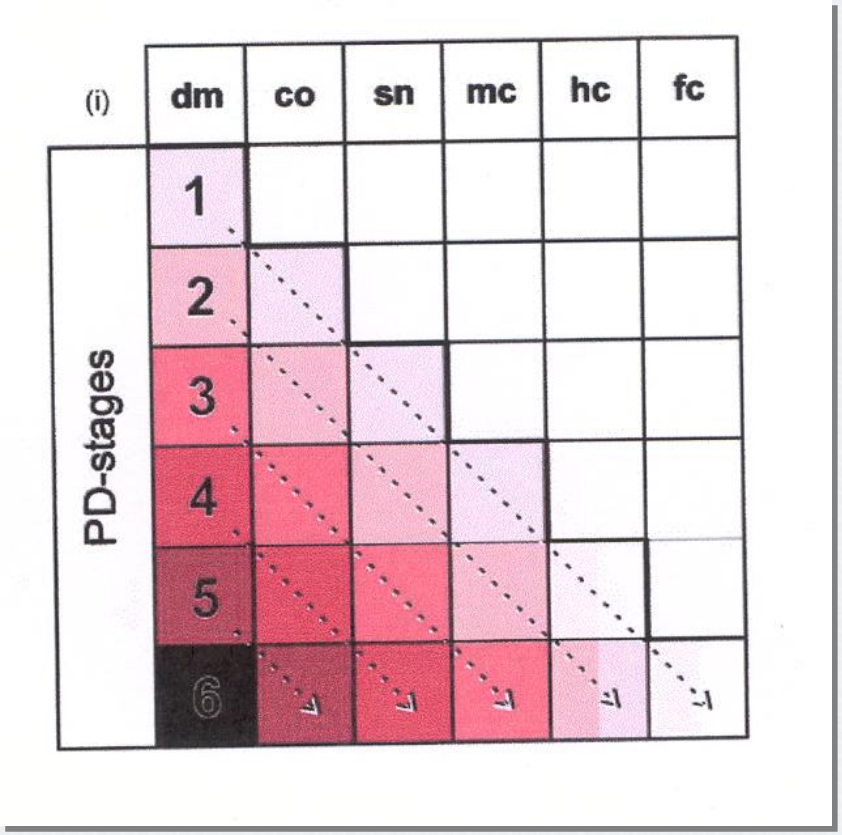

Staging of brain pathology related to sporadic Parkinson's disease

Heiko Braak[a,*], Kelly Del Tredici[a], Udo Rüb[a], Rob A.I. de Vos[b], Ernst N.H. Jansen Steur[b], Eva Braak[a,†]

[a] Department of Clinical Neuroanatomy, J.W. Goethe University, Theodor Stern Kai 7, D-60590 Frankfurt/Main, Germany
[b] Department of Neurology MST Hospital Group and Laboratorium Pathologie Oost Nederland, Burg. Edo Bergsmalaan, 7512 AD Enschede, The Netherlands

Neurobiol Aging, 2003 : 197-211.

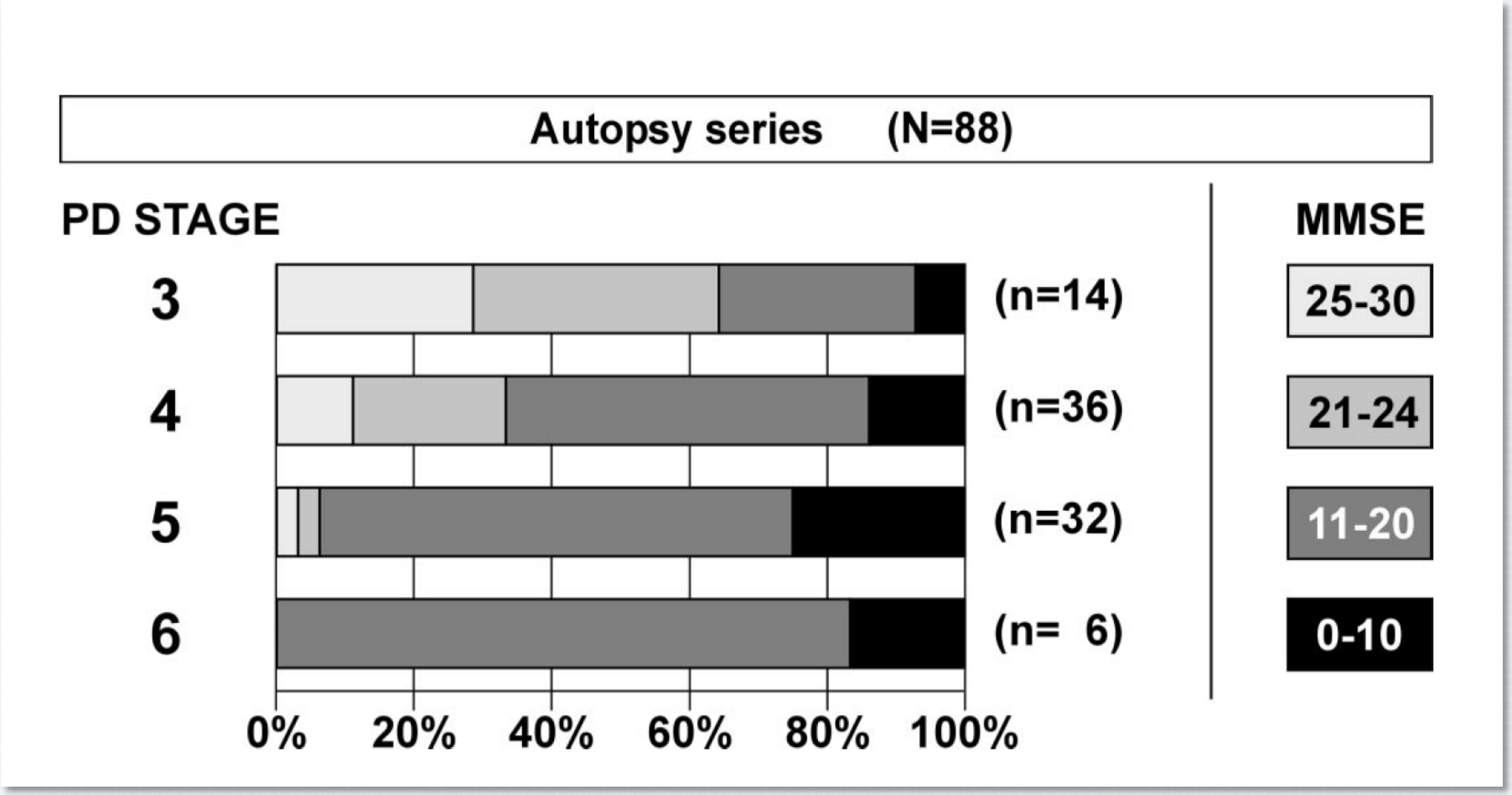

Braak et al., 2005

According to Kosaka[39]*	According to Braak[35–37]
..	• Enteric nervous system • Peripheral autonomic system • Spinal cord
Brainstem Lewy body disease	Braak PD stages 1–2: • Vagal dorsal motor nucleus • Lower raphe nuclei • Locus coeruleus
Transitional Lewy body disease	Braak PD stages 3–4: • Substantia nigra pars compacta • Amygdala, basal nucleus of Meynert • Intralaminar thalamic nuclei • Hippocampal CA2 sector
Diffuse Lewy body disease	Braak PD stages 5–6: • Cingulate cortex • Temporal cortex • Frontal cortex • Parietal cortex

PD=Parkinson's disease. *The same affected areas are assumed for the Kosaka criteria as listed for the Braak criteria.

Table 2: **Anatomical regions susceptible to Lewy pathology, according to two major classification schemes**

Dickson et al., 2009

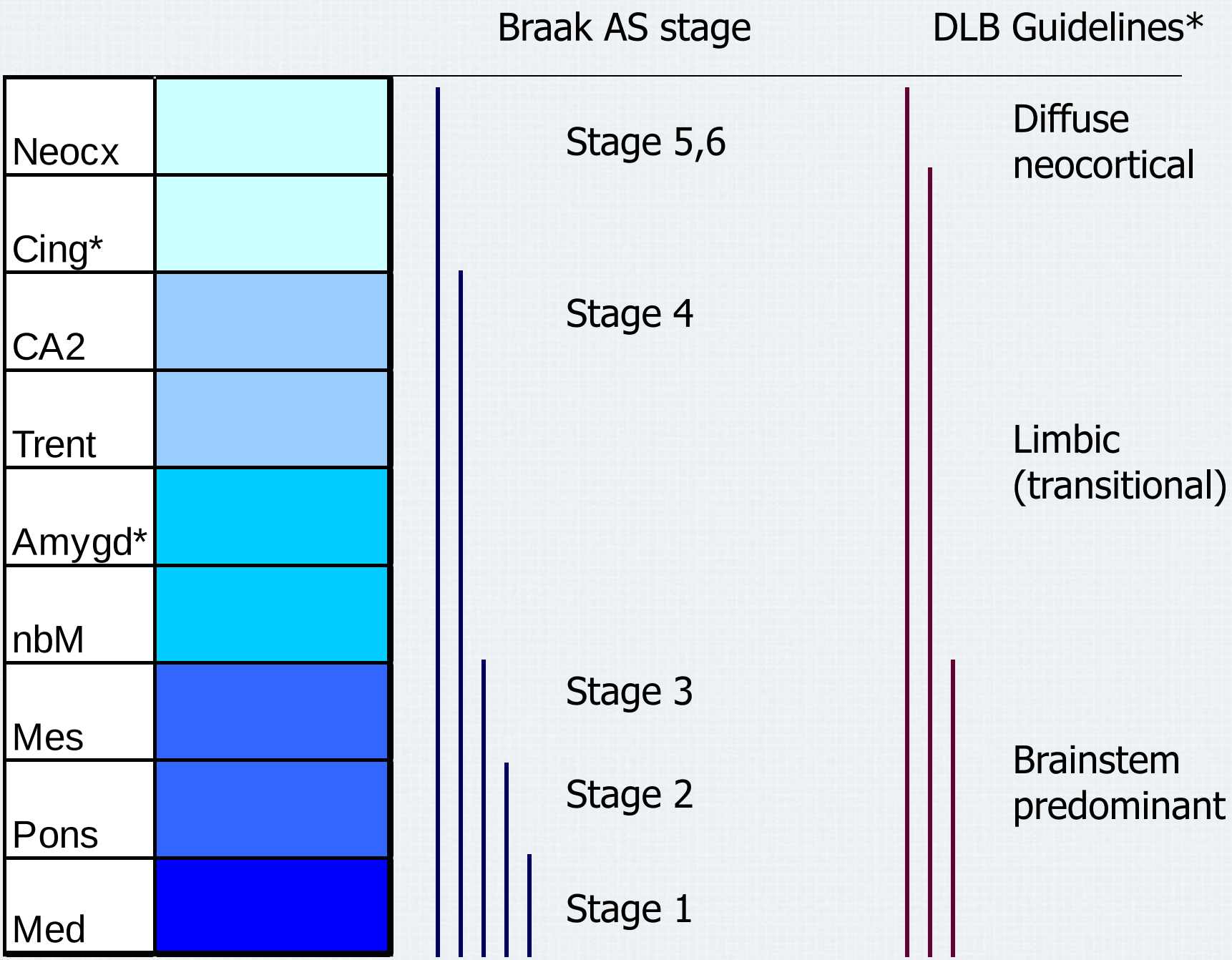
Braak AS stage
DLB Guidelines*
Neocx
Cing*
CA2
Trent
Amygd*
nbM
Mes
Pons
Med
Stage 5,6
Stage 4
Stage 3
Stage 2
Stage 1
Diffuse neocortical
Limbic (transitional)
Brainstem predominant

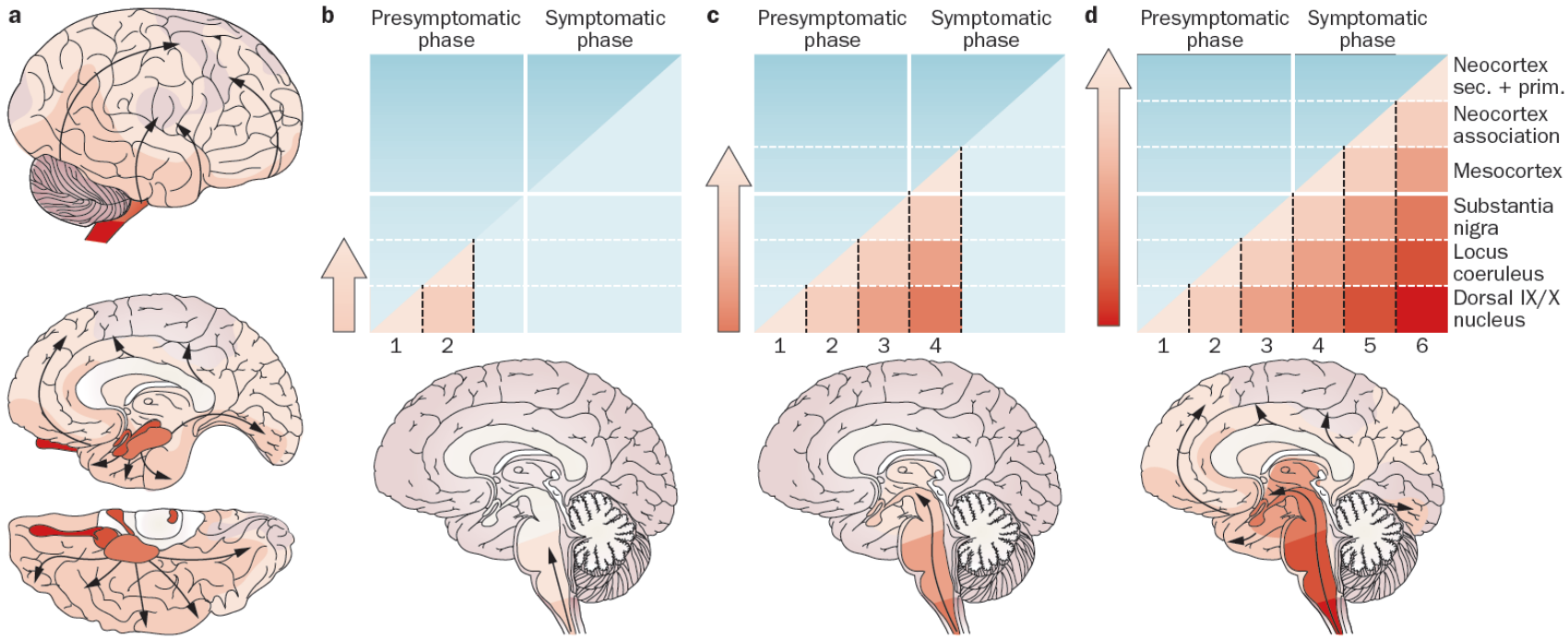

Sampled brain areas	Medulla		Pons		Midbrain	Basal Forebrain		Hippocampus		Gyrus cinguli	Temporal cortex	Frontal cortex	Parietal cortex
Anatomical region	dmV	irx	LC	R	SN	nbM	AC	CA2	TOcx	grey matter	grey matter	grey matter	grey matter
Braak stage	1	1	2	2	3	3	4	3	4	5	5	6	6
McKeith type	BRAINSTEM					LIMBIC						NEOCORTICAL	
Amygdala predominant							AC predominant						
Lesion type requested	LBs and / or LNs						LBs	LNs	LBs				

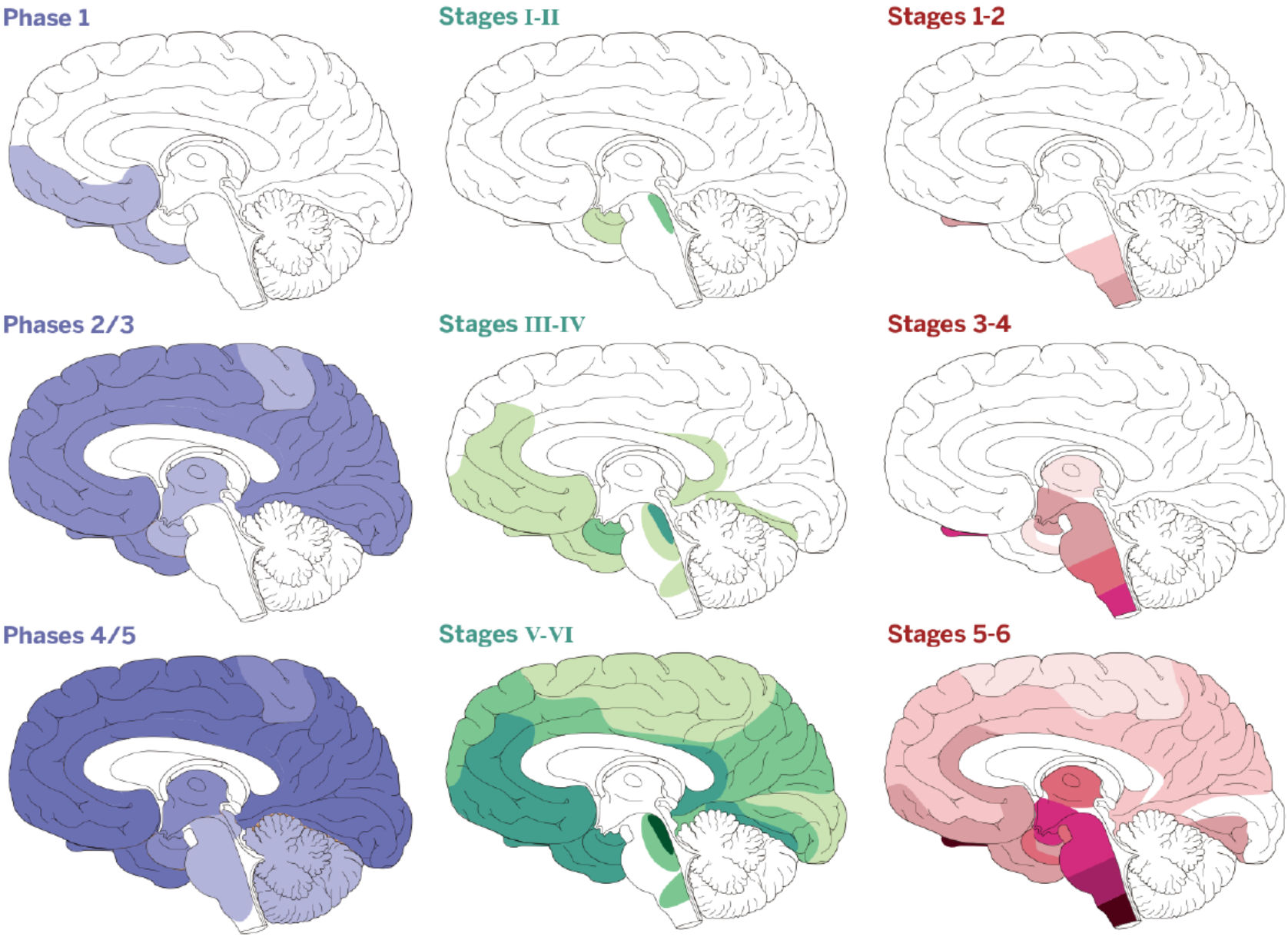

Goedert *et al*., 2015

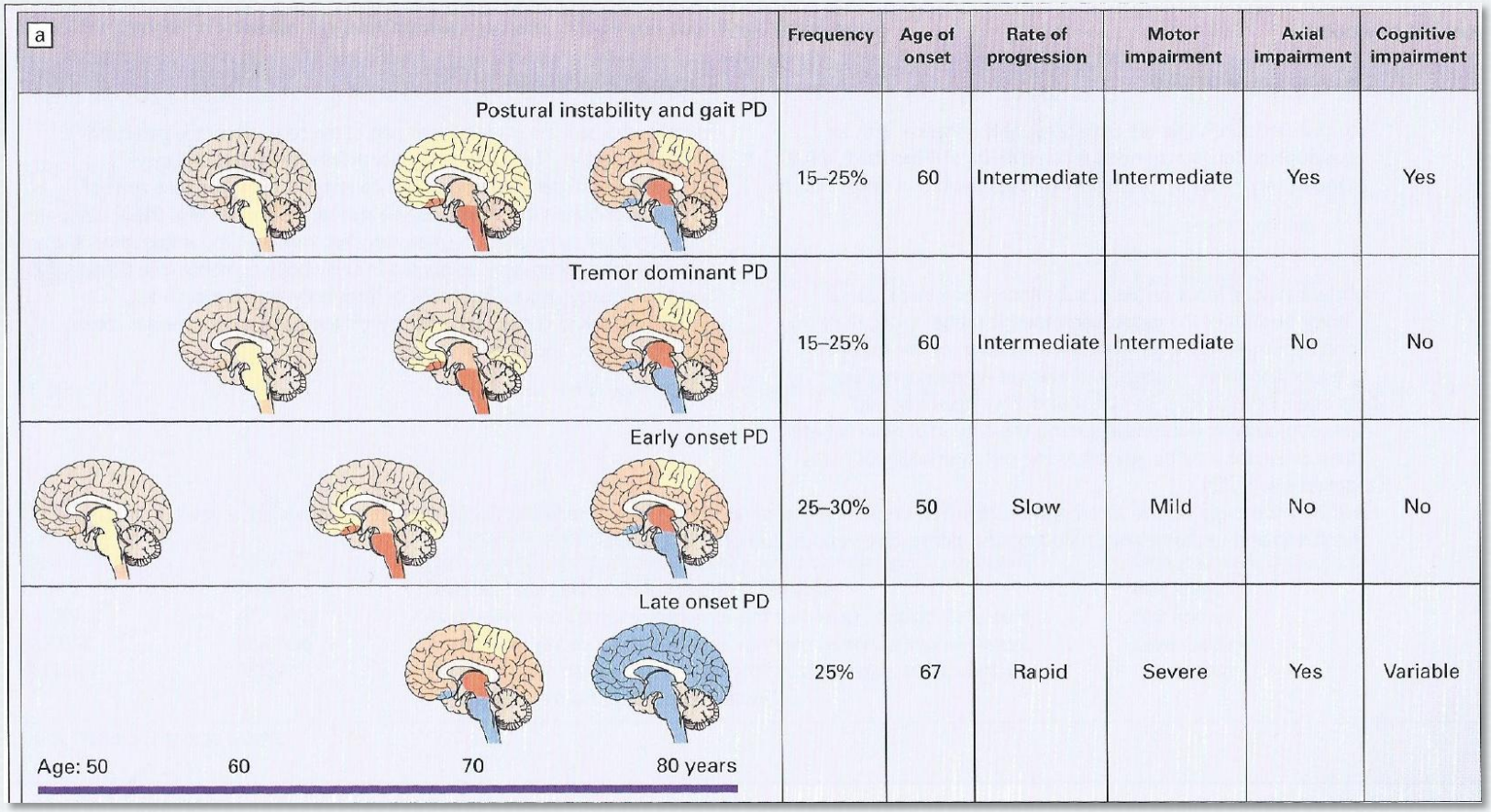

Frequency	Age of onset	Rate of progression	Motor impairment	Axial impairment	Cognitive impairment
15–25%	60	Intermediate	Intermediate	Yes	Yes
15–25%	60	Intermediate	Intermediate	No	No
25–30%	50	Slow	Mild	No	No
25%	67	Rapid	Severe	Yes	Variable

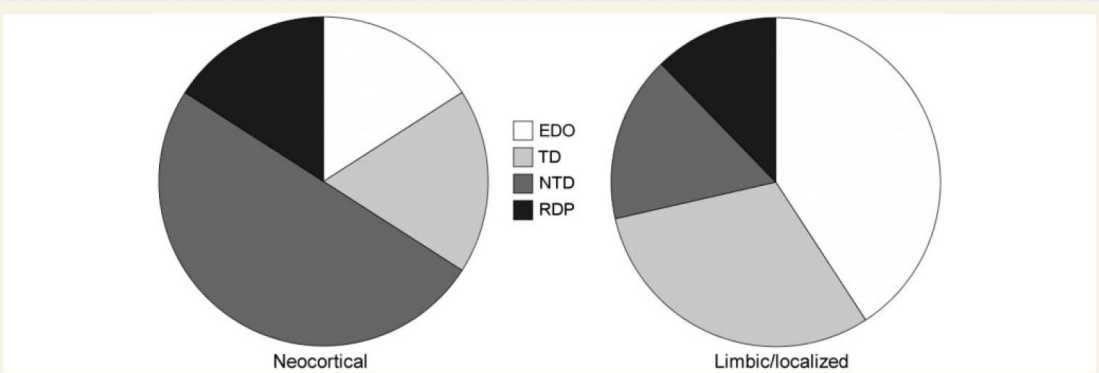

Figure 3 Clinical subtype according to the extent of Lewy body pathology.

Selikhova et al., 2009

nature medicine

Received 14 December 2007; accepted 6 March 2008; published online 6 April 2008; doi:10.1038/nm1747

Lewy body–like pathology in long-term embryonic nigral transplants in Parkinson's disease

Jeffrey H Kordower[1], Yaping Chu[1], Robert A Hauser[2], Thomas B Freeman[3] & C Warren Olanow[4]

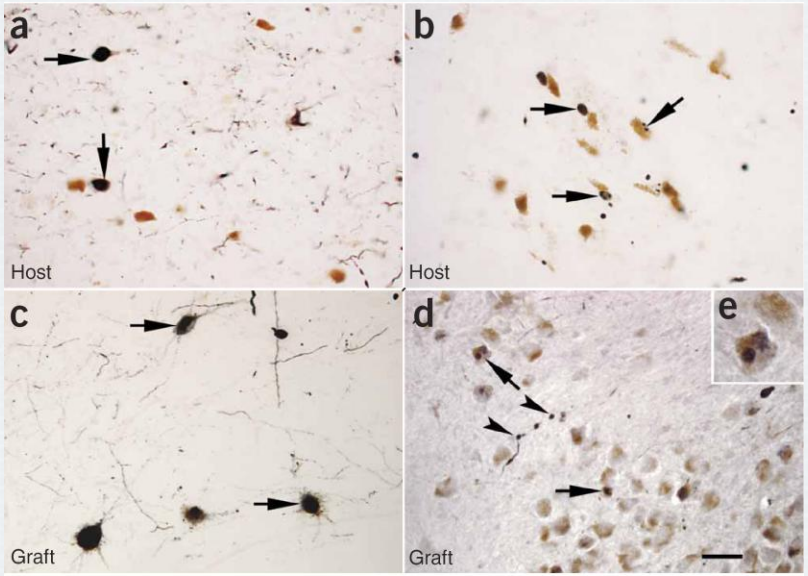

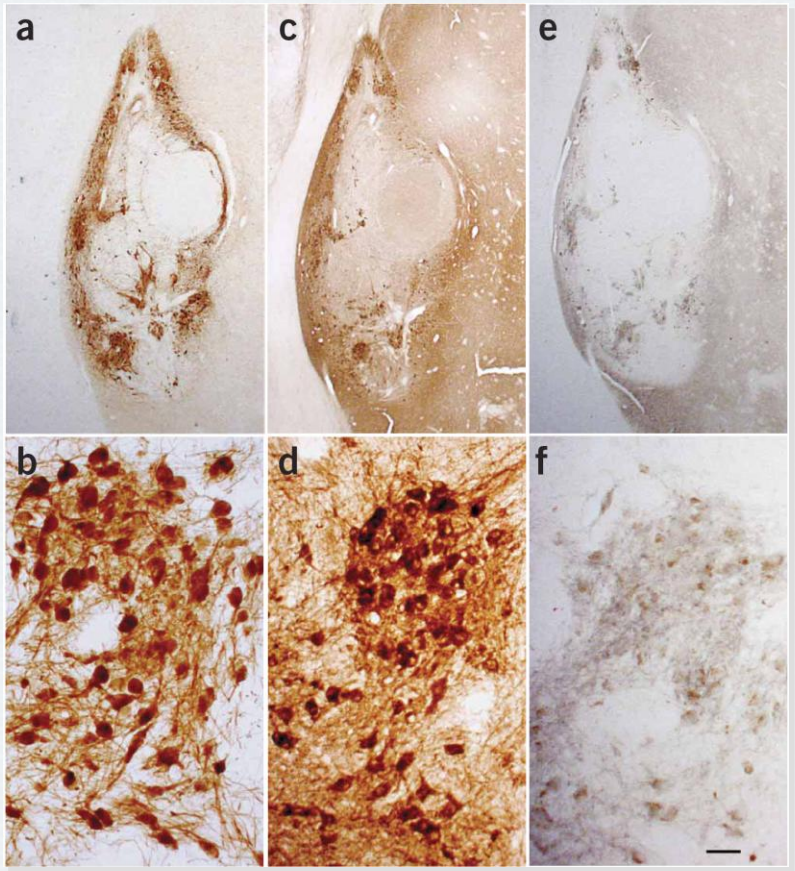

Figure 2 Parkinson's disease–like pathology in long-term nigral grafts. In the nongrafted host's nigra, typical α-synuclein (**a**) and ubiquitin (**b**) neuropathology was observed (arrows). (**c**) Extensive α-synuclein pathology was seen in grafted neurons, including cytoplasmic and aggregated α-synuclein (arrows) as well as α-synuclein neurites. (**d**,**e**) Pathological aggregates of ubiquitin were also seen in grafted neurons (arrows) and fibers (arrowheads). Scale bar, 40 μm. All people studied in this manuscript gave their informed consent to participate in transplant studies approved by the Institutional Review Board at the University of South Florida at Tampa. Proper informed consent was subsequently obtained for brain donation.

Cell

Leading Edge
Perspective

Transmissible Proteins: Expanding the Prion Heresy

Claudio Soto[1,*]
[1]Mitchell Center for Alzheimer's Disease and Related Brain Disorders, Department of Neurology, University of Texas Houston Medical School, Houston, TX 77030, USA
*Correspondence: claudio.soto@uth.tmc.edu
DOI 10.1016/j.cell.2012.05.007

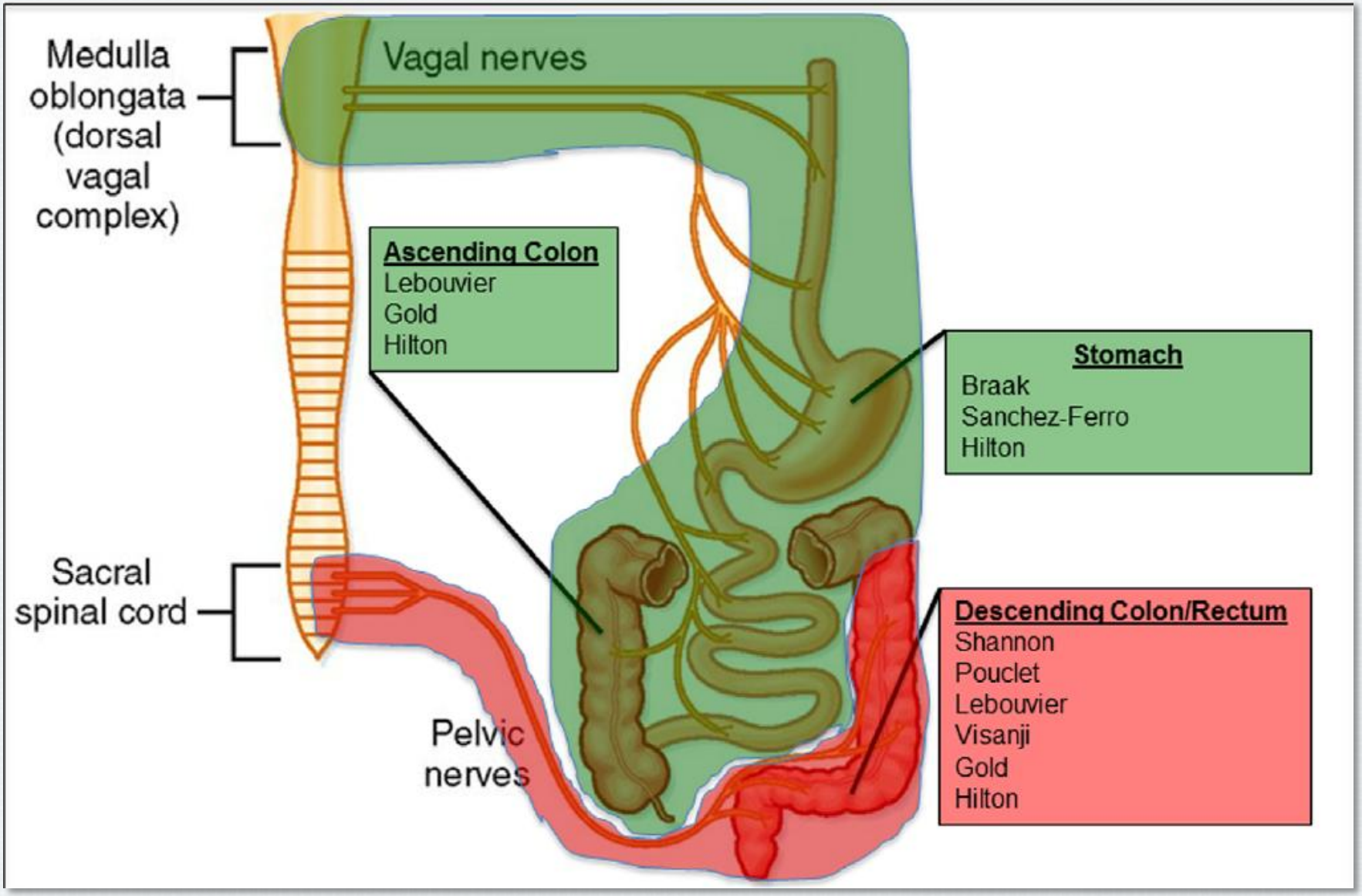

Ruffman *et al*., 2016

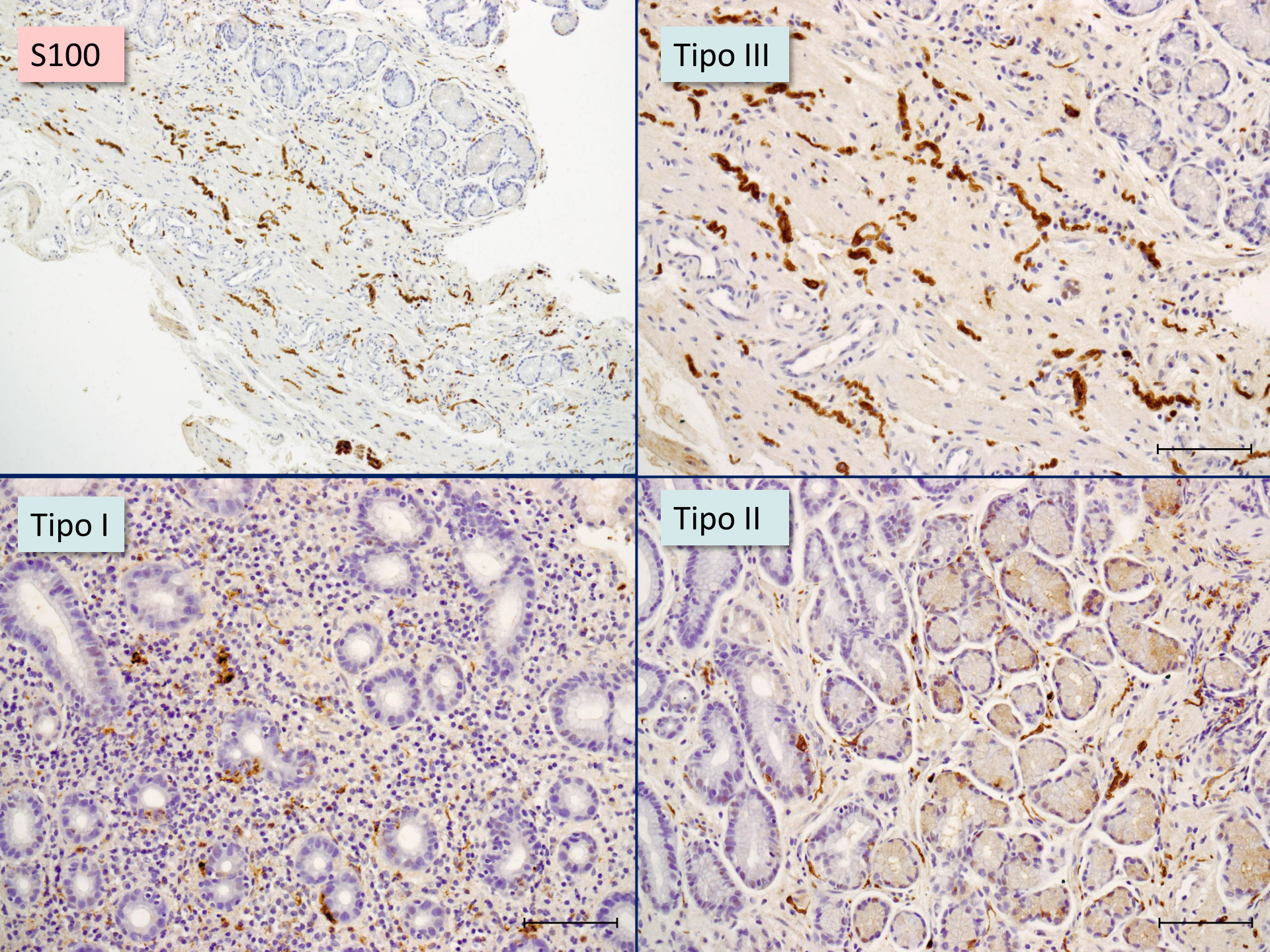
S100
Tipo III
Tipo I
Tipo II

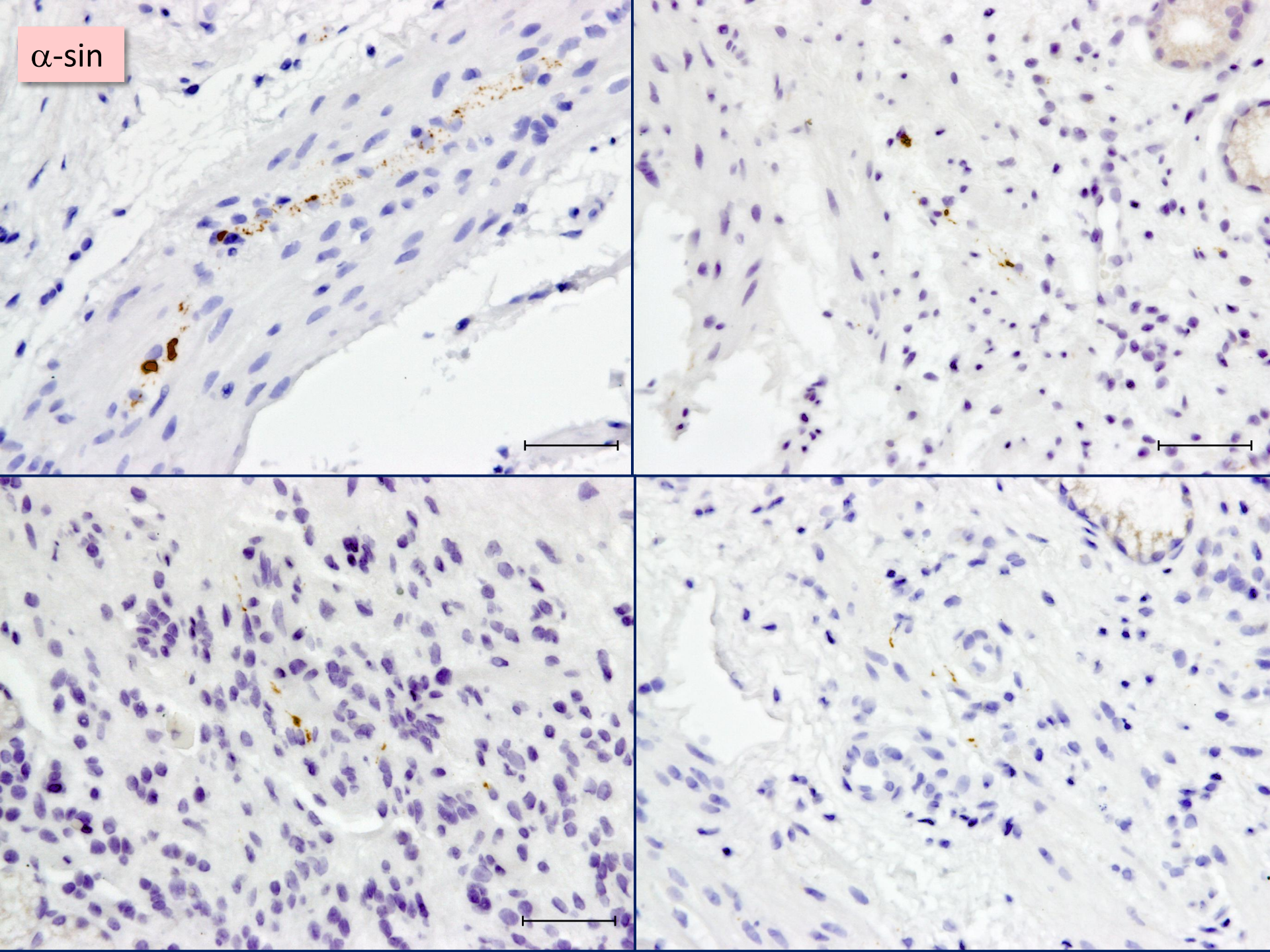
α-sin

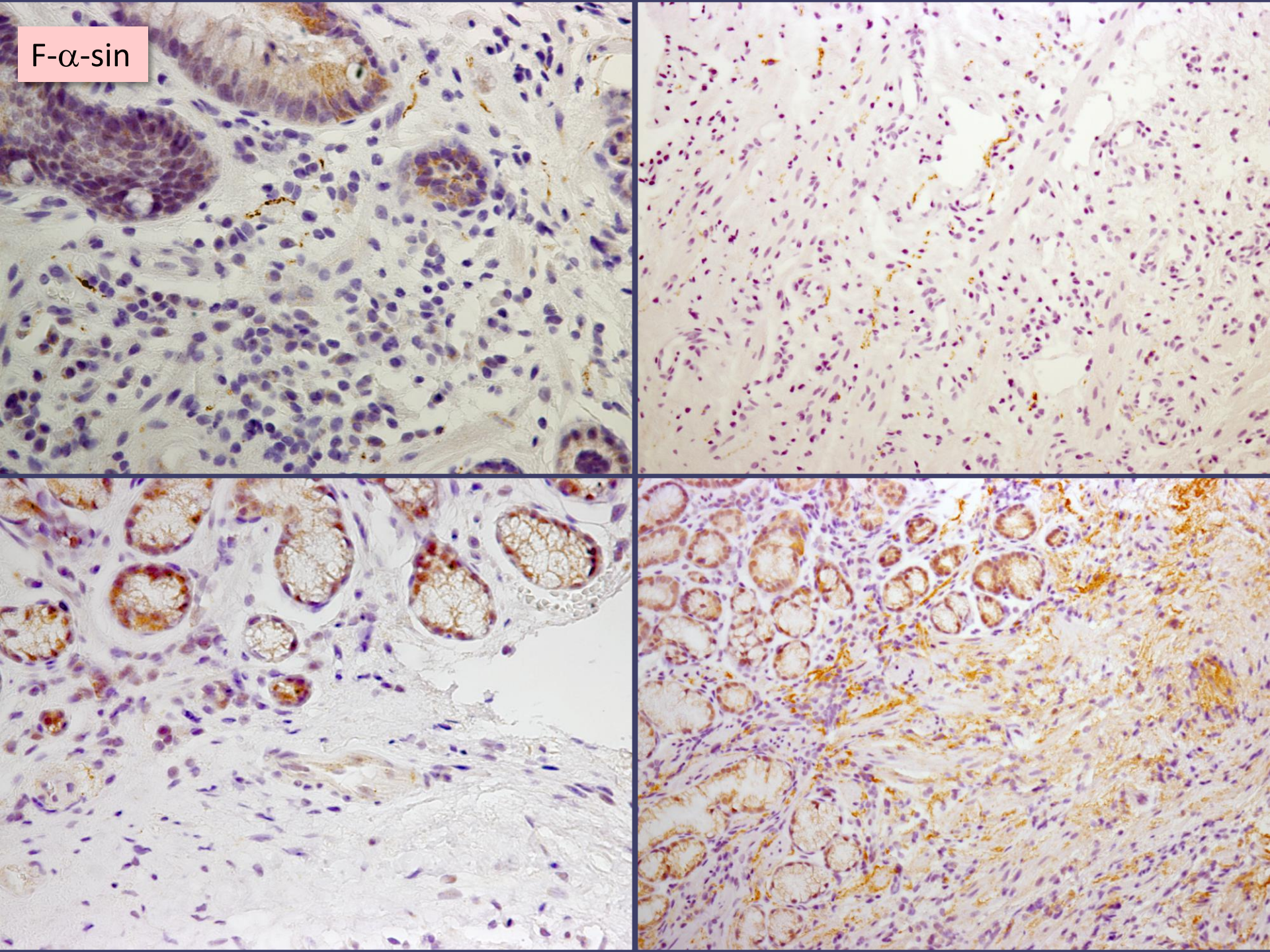
F-α-sin

frontiers in Neuroscience

ORIGINAL RESEARCH
published: 08 March 2016
doi: 10.3389/fnins.2016.00086

Corpora Amylacea of Brain Tissue from Neurodegenerative Diseases Are Stained with Specific Antifungal Antibodies

*Diana Pisa[1], Ruth Alonso[1], Alberto Rábano[2] and Luis Carrasco[1]**

[1] Centro de Biología Molecular "Severo Ochoa," Universidad Autónoma de Madrid, Madrid, Spain, [2] Department of Neuropathology and Tissue Bank, Unidad de Investigación Proyecto Alzheimer, Fundación Centro de Investigación de Enfermedades Neurologicas, Instituto de Salud Carlos III, Madrid, Spain

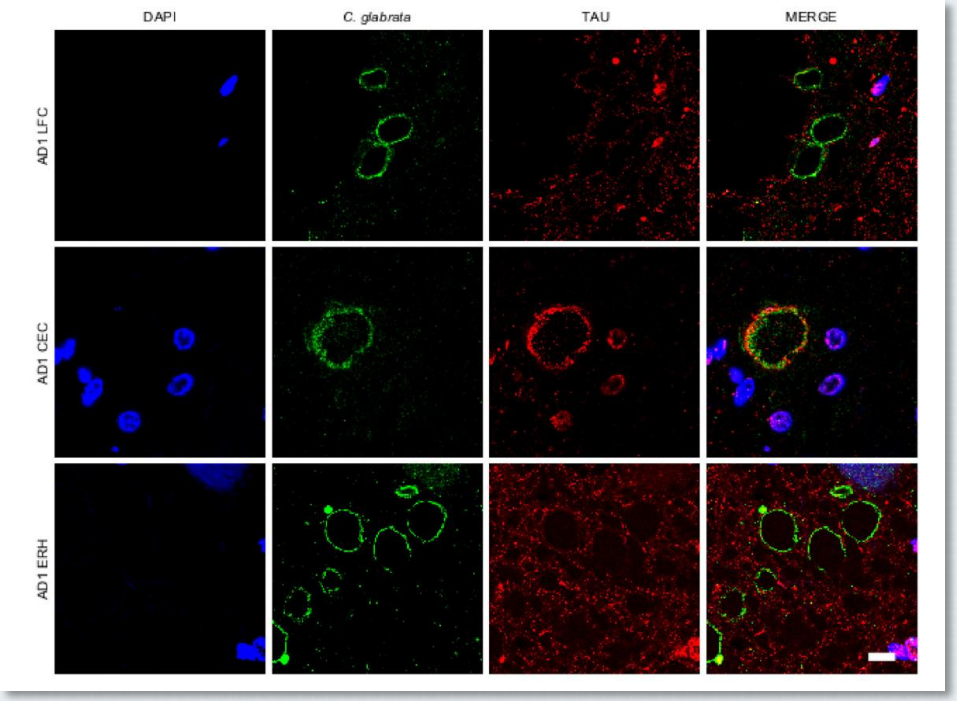

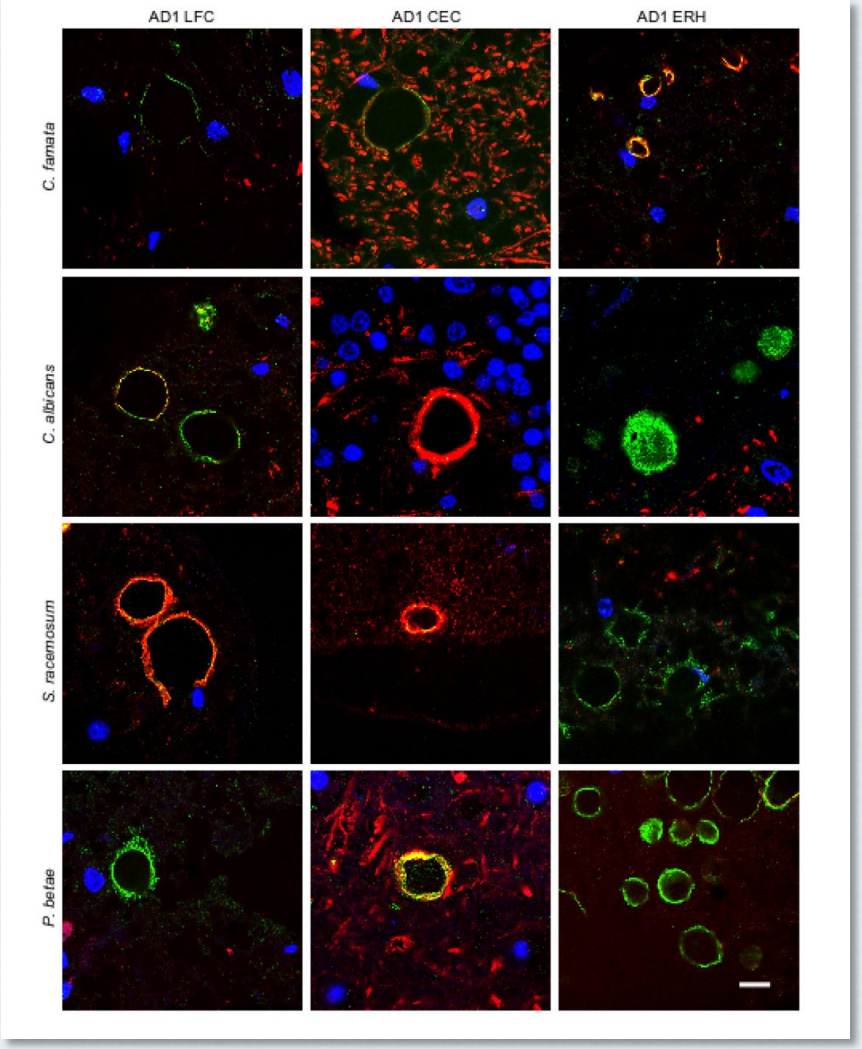

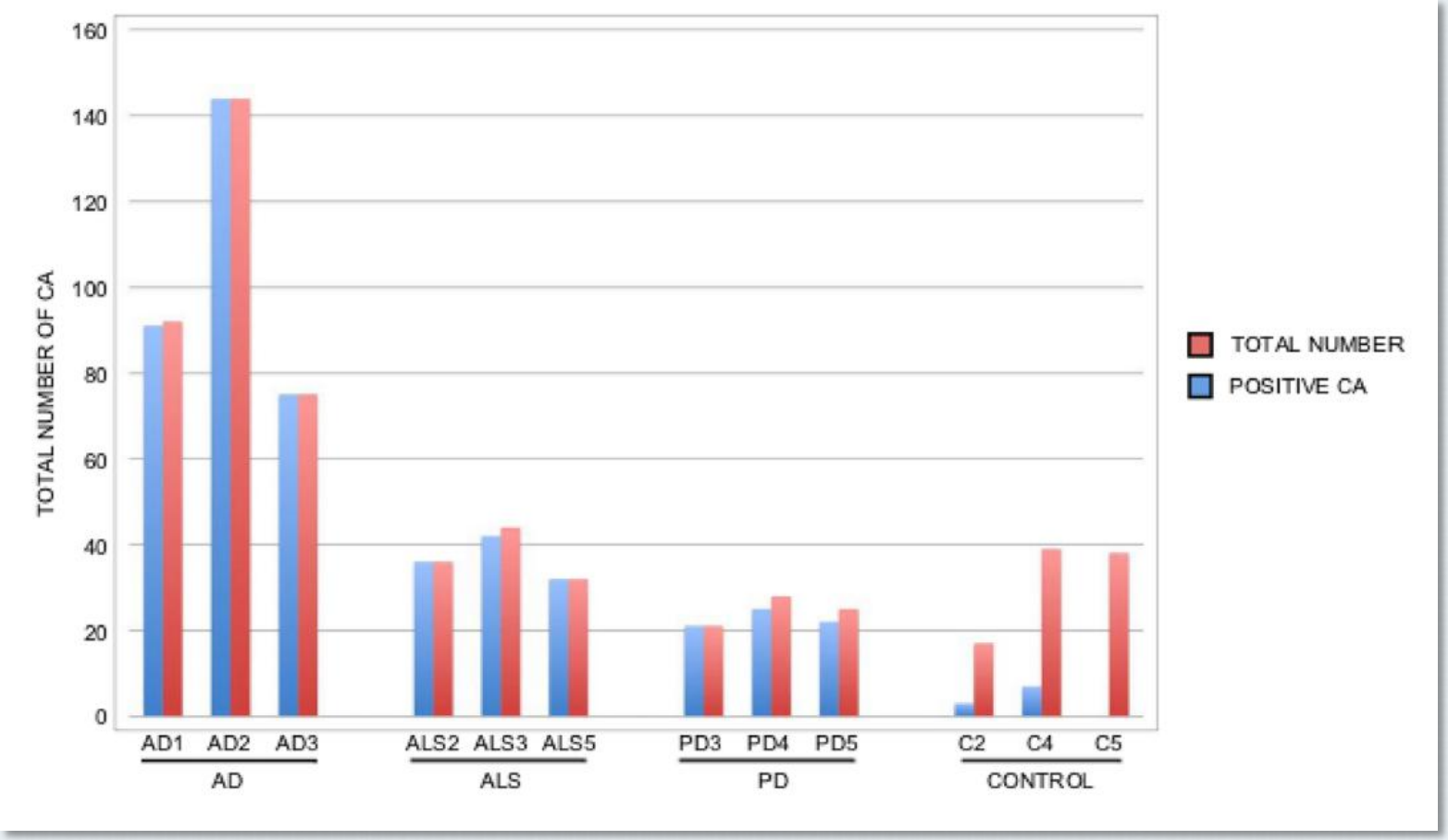
TOTAL NUMBER OF CA
160
140
120
100
80
60
40
20
0
AD1
AD2
AD3
AD
ALS2
ALS3
ALS5
ALS
PD3
PD4
PD5
PD
C2
C4
C5
CONTROL
TOTAL NUMBER
POSITIVE CA

Alzheimer Soria
cien
Fundación Centro Investigación
Enfermedades Neurológicas

¡Gracias!