Guía básica para el diagnóstico histológico de la patología neurodegenerativa.

Alberto Rábano

Banco de Tejidos CIEN
Fundación CIEN, ISCIII

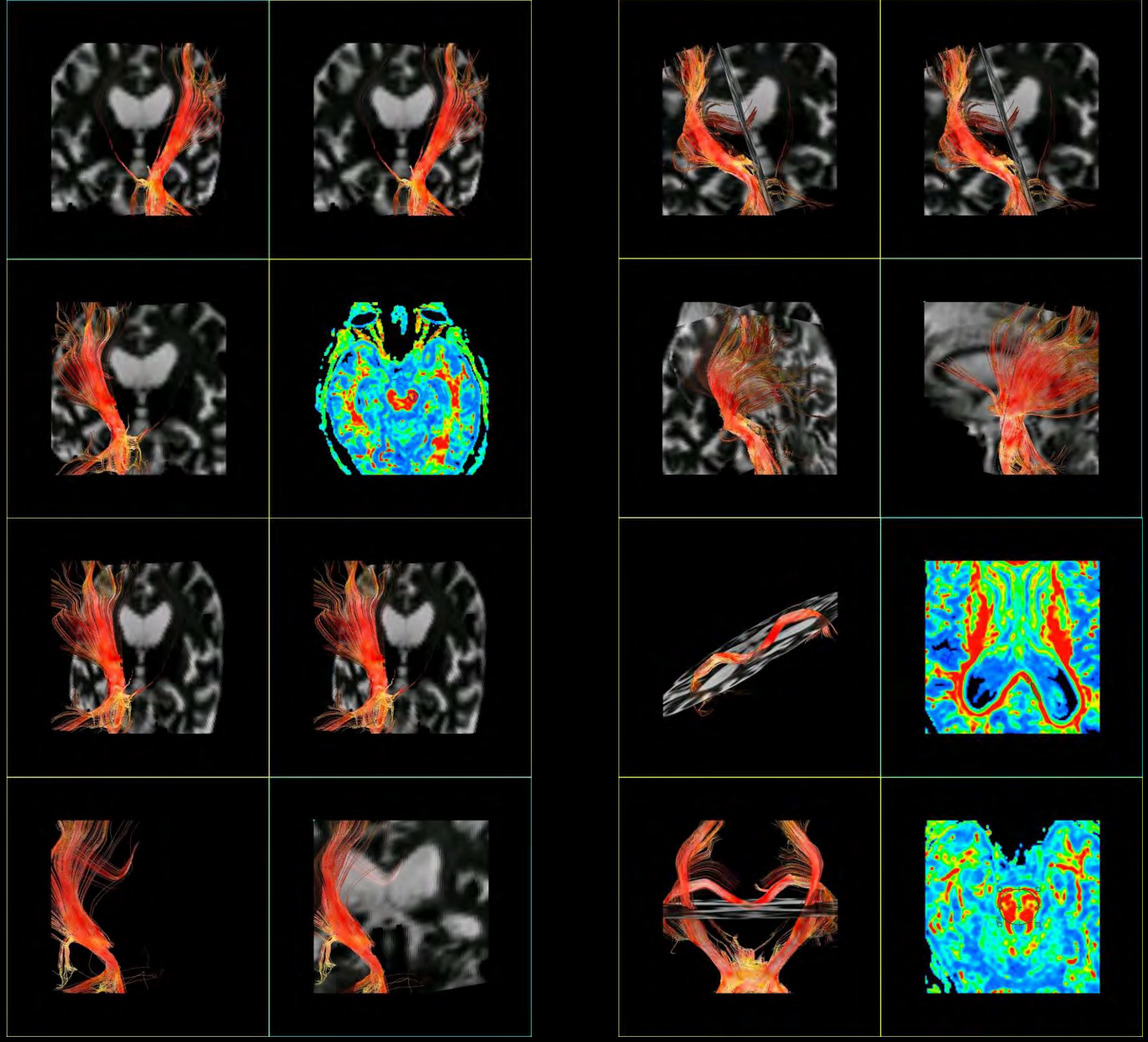

Familia

- Informe NP
- Diagnóstico(s) definitivo(s)
- ¿Enfermedad genética?

Clínicos

- Informe NP
- Correlación C-P
- Formación
- Investigación

Investigadores

- Clasificación del caso
- Clasificación de la muestra
- Información clínica
- Datos de calidad

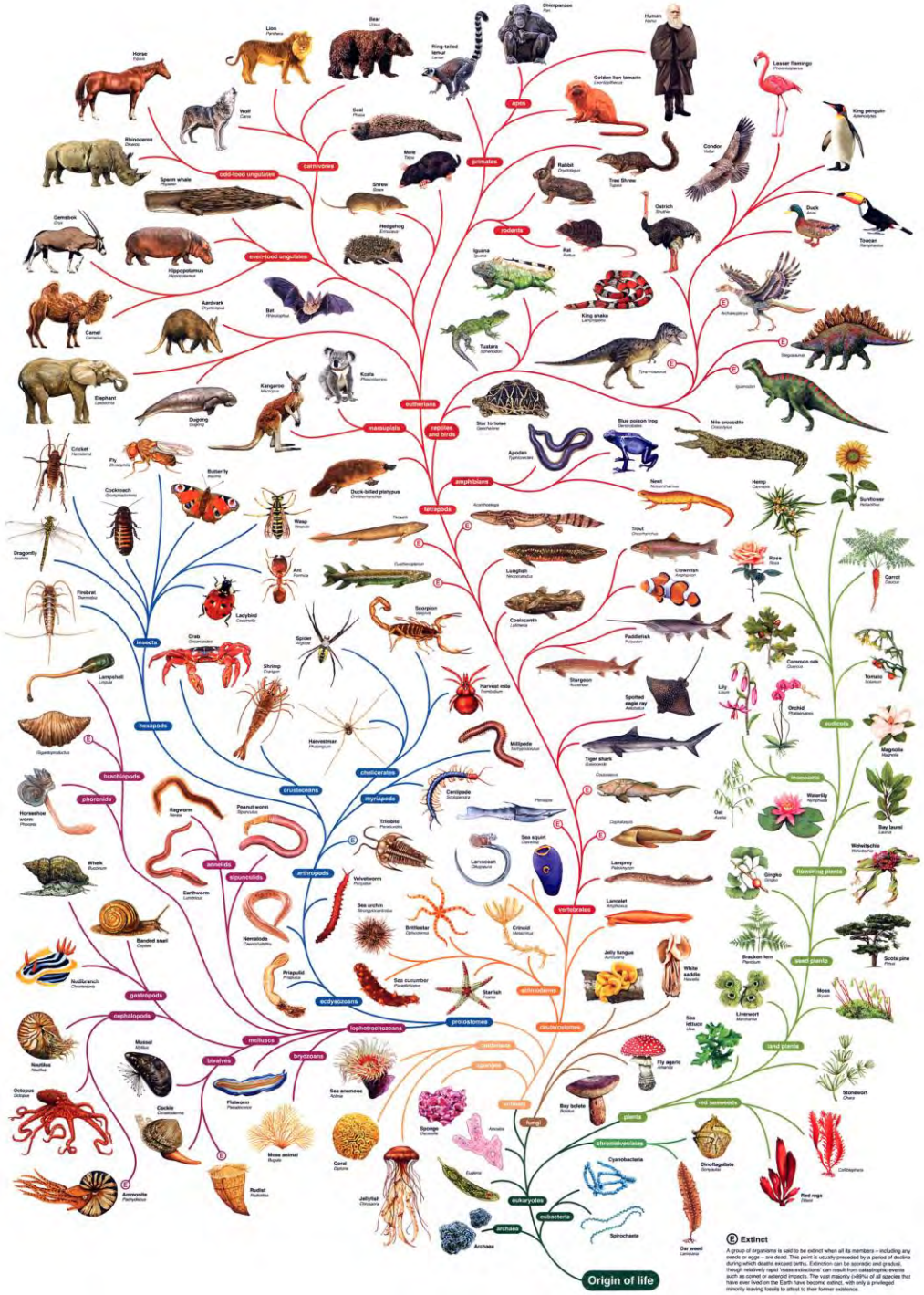

Ⓔ Extinct

A group of organisms is said to be extinct when all its members – including any seeds or eggs – are dead. This point is usually preceded by a period of decline during which deaths exceed births. Extinction can be sporadic and gradual, though relatively rapid 'mass extinctions' can result from catastrophic events such as comet or asteroid impacts. The vast majority (>99%) of all species that have ever lived on the Earth have become extinct, with only a privileged minority leaving fossils to attest to their former existence.

Human disease network (Loscalzo J et al. *Mol Syst Biol*. 2007, 3: 124.)

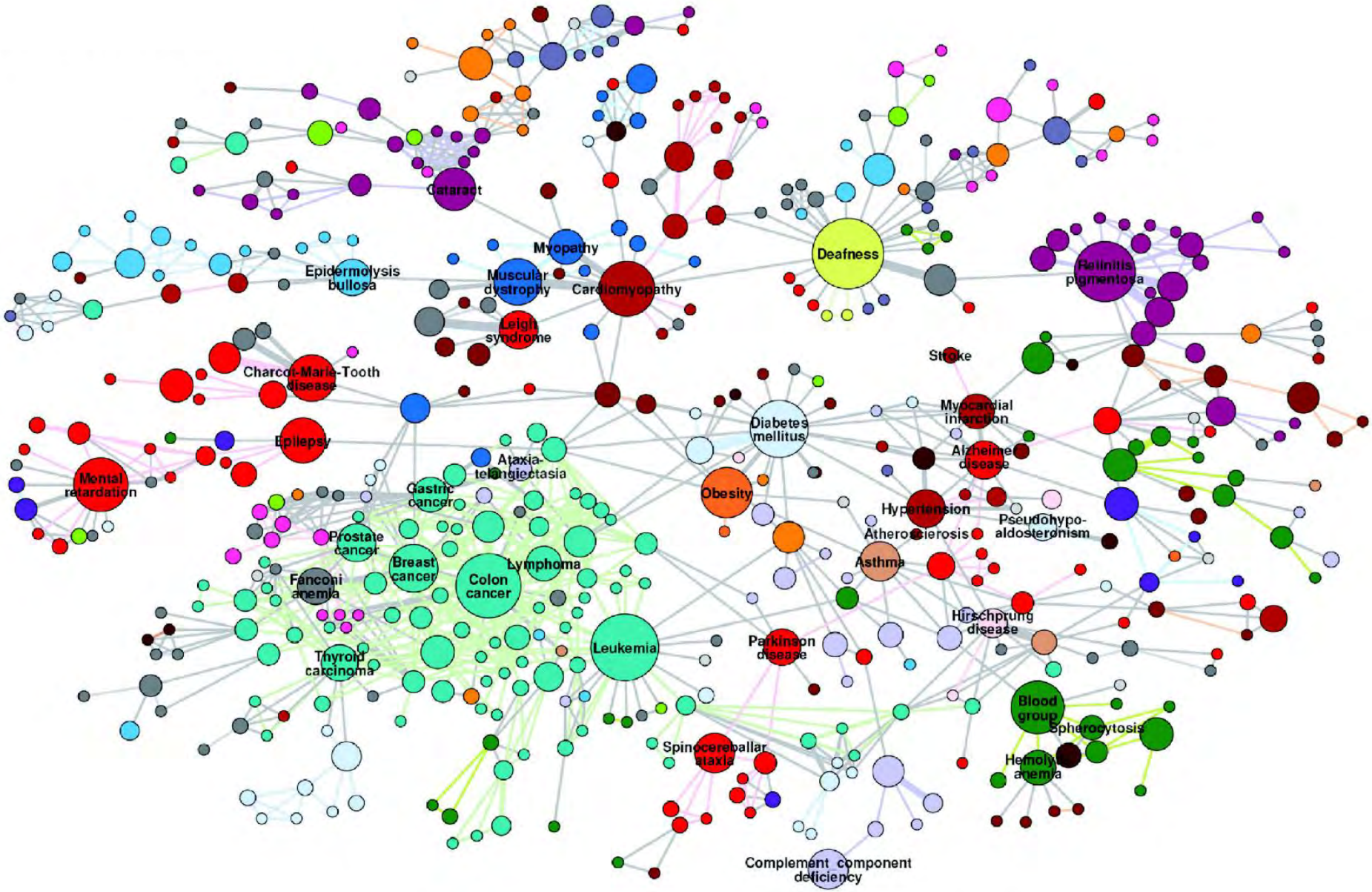

Diagnóstico y clasificación:

- Alzheimer
- Enfermedades priónicas
- Patología de Lewy
- Taupatías
- Patología TDP

Table 1. Classification of major neurodegenerative disorders

	Disorder	Anatomy	Major clinical feature
Amyloidoses			
Aβ	Alzheimer disease	Corticolimbic	Dementia
ABri	Familial British dementia	Corticolimbic & cerebellar	Dementia & ataxia
PrP	Creutzfeldt-Jakob disease	Cortical & basal ganglia	Dementia & movement disorder
	Gerstmann-Straussler-Scheinker	Cortical & Cerebellar	Ataxia & dementia
Tauopathies			
4R	Progressive supranuclear palsy	Basal ganglia & brainstem	Parkinsonism
	Corticobasal degeneration	Cortical & basal ganglia	Focal cortical syndrome & parkinsonism
	Argyrophilic grain disease	Limbic	Amnestic cognitive impairment
3R	Pick's disease	Corticolimbic	Dementia & focal cortical syndromes
3R+4R	Tangle predominant dementia	Limbic	Dementia
	Guam Parkinson dementia complex	Cortex & brainstem	Dementia & parkinsonism
Synucleinopathies			
	Parkinson disease	Brainstem	Parkinsonism
	Dementia with Lewy bodies	Corticolimbic & brainstem	Dementia & parkinsonism
	Multiple system atrophy	Basal ganglia, brainstem & cerebellum	Parkinsonism & ataxia
TDP-43 proteinopathies			
	Amyotrophic lateral sclerosis	Motor neurons	Spasticity & weakness
	Frontotemporal lobar degeneration with ubiquitinated inclusions	Cortex & basal ganglia	Dementia & focal cortical syndromes

Cuestiones previas:

- ¿Enfermedad o patología?
- ¿Probabilidad o certeza?
- ¿Lesiones específicas o inespecíficas?

Hallazgos patológicos en enfermedades neurodegenerativas

	Positivos	Negativos	Reactivos
Específicos			
Inespecíficos			

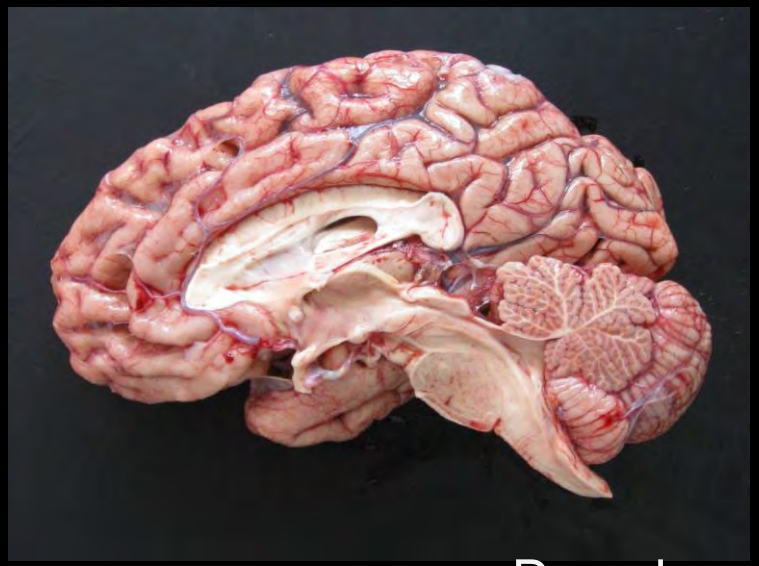

Derecho → Congelación

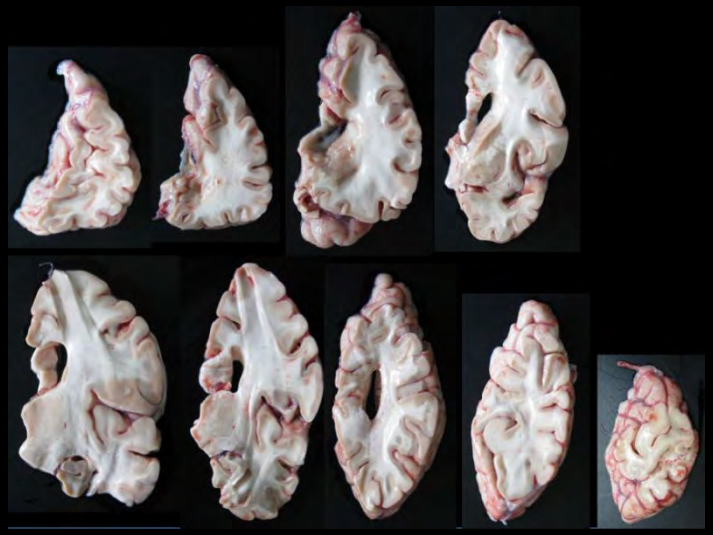

Izquierdo → Neuropatología

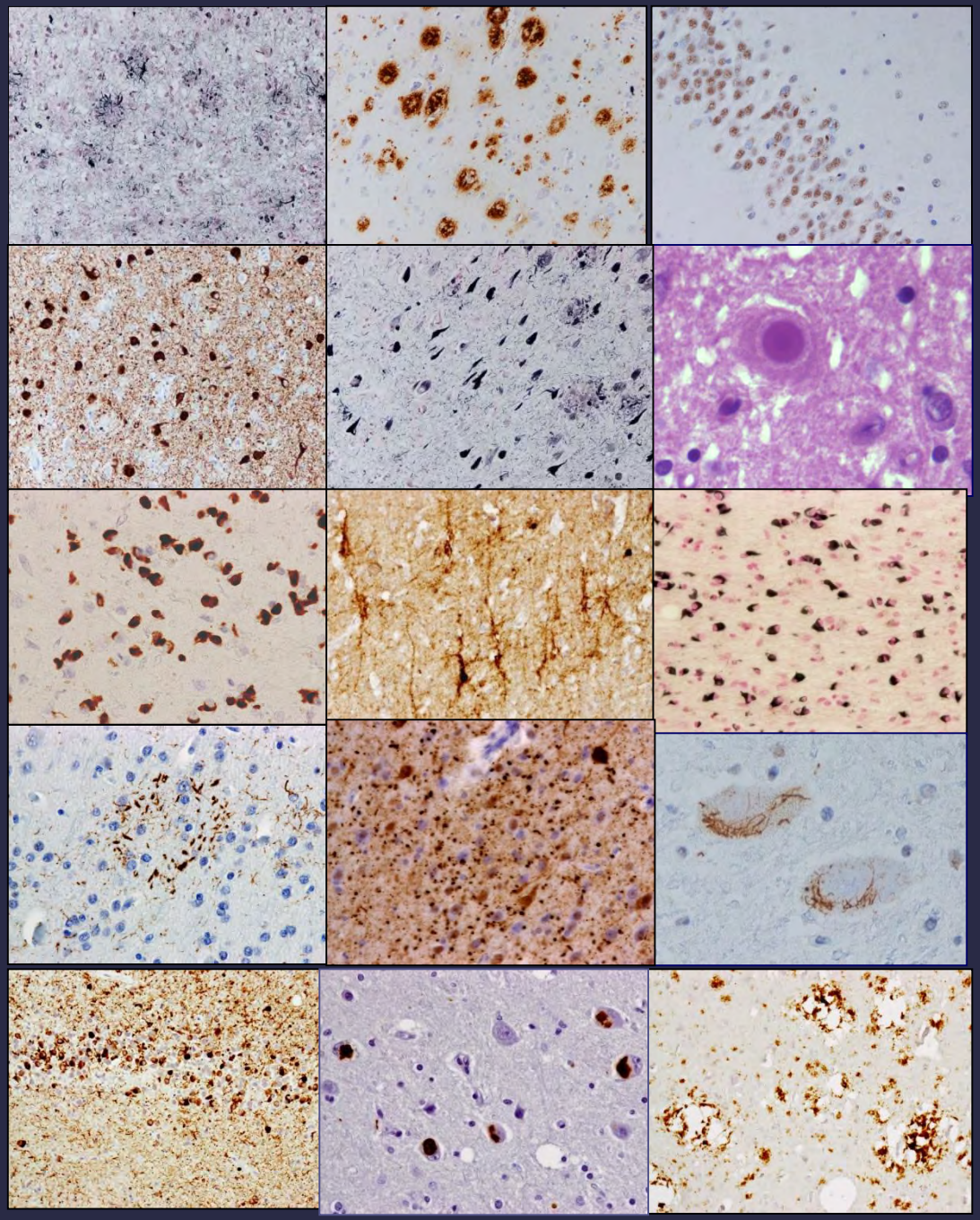

Diagnóstico neuropatológico principal (criterios de consenso)

Diagnósticos neuropatológicos combinados

Grados, Estadios

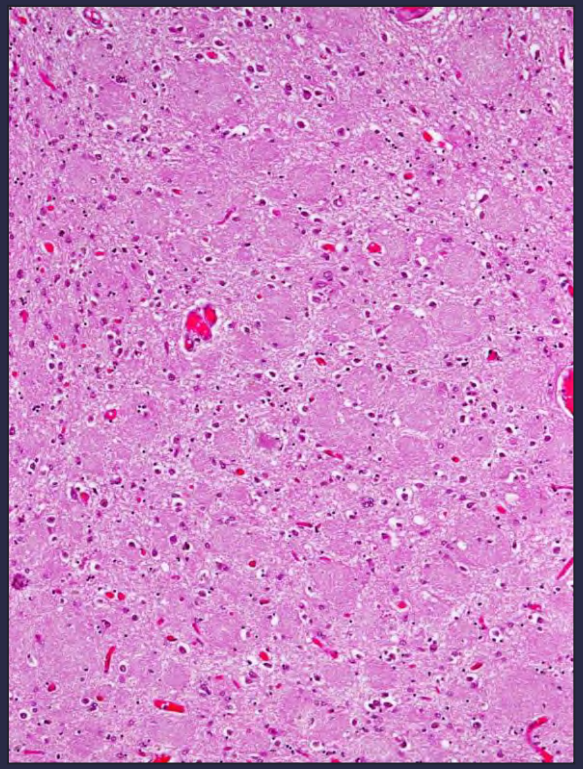

Hematoxilina
– eosina

(Rutina)

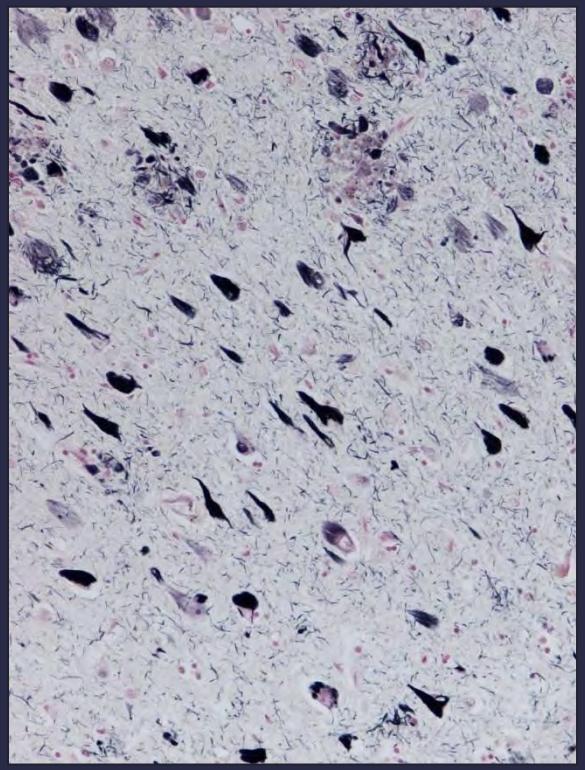

Gallyas

(Plata)

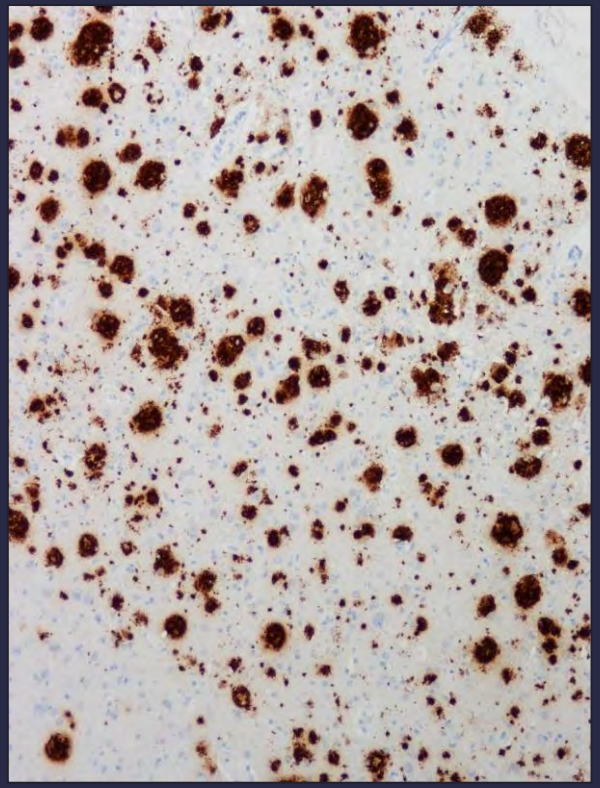

Beta-amiloide

(Inmunohistoquímica)

Region	AD Neuropathologic Change			LBD	VBI and HS
	A Stain for Aβ/amyloid plaques [57]	B Stain for NFTs [14,15]	C Stain for NPs [41]	Stain for LBs	H&E
Medulla including DMV				1°: IHC or H&E[a]	VBI
Pons including LC				1°: IHC or H&E[a]	VBI
Midbrain including SN	3°: if 2° is +			1°: IHC or H&E[a]	VBI
Cerebellar cortex and dentate n.	3°: if 2° is +				VBI
Thalamus and subthalamic n.[b]					MVL
Basal ganglia at level of AC with basal nucleus of Meynert[b]	2°: if 1° is +	Consider[c]			MVL
Hippocampus and EC[b]	2°: if 1° is +[d]	Yes	Consider[c]	2°: IHC in at least one if 1° +	HS
Cingulate, anterior					VBI
Amygdala				1°: IHC[a]	VBI
Middle frontal gyrus[b]	1°[d]	Yes	Yes	2°: IHC in at least one if 1° +	MVL
Superior and middle temporal gyri[b]	1°[d]	Yes	Yes		MVL
Inferior parietal lobule[b]	1°[d]	Yes	Yes		MVL
Occipital cortex (BA 17 and 18)[b]	Consider[c]	Yes	Consider[c]		MVL
WM at ACA, MCA, and PCA watershed					Consider[c]

Montine *et al.* Acta Neuropathol (2012) 123:1–11

Bloque-área	Técnicas para diagnóstico neuropatológico						
	H/E	Beta-A	Tau AT100	A-sin	Ubiq	TDP-43	Solocr
Bulbo olfatorio	■						
Córtex órbitofrontal	■						
Córtex frontal (CERAD)	■	■	■	■			
Córtex cingular anterior	■			■			
Córtex prerrolándico	■						
Córtex parietal (CERAD)	■	■	■				
Córtex temporal (CERAD)	■	■	■	■			
Córtex insular anterior	■		■				
Córtex occipital lateral	■						
Córtex c. calcarina	■		■				
Amígdala	■		■	■			
Hipocampo anterior	■		■		■	■	
Hipocampo, cuerpo	■	■			■	■	
Sust. blanca periventr.	■						■
N. caudado (cabeza)	■						
N. lenticular	■	■					
Hipotálamo	■		■				
Tálamo	■						
Mesencéfalo	■	■	■	■			
Protuberancia	■			■			
Bulbo raquídeo	■			■			
Médula cerical	■						
Médula espinal	■						
Vermis cerebeloso	■						
Hemisferio cerebeloso	■	■					

Patología de tipo Alzheimer

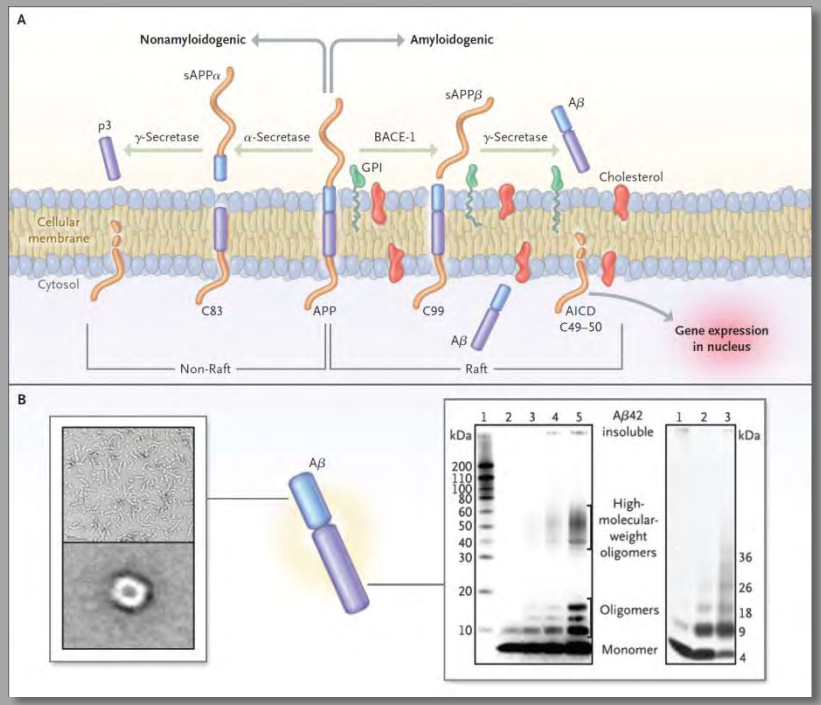

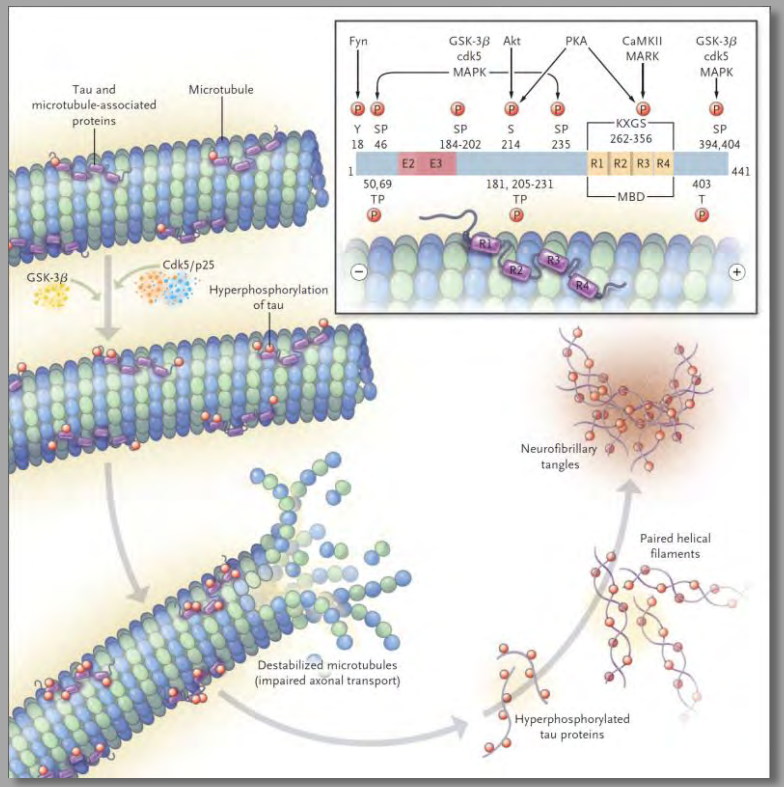

E. DE PARKINSON

E. DE ALZHEIMER

Córtex parietal CERAD, Beta-amiloide

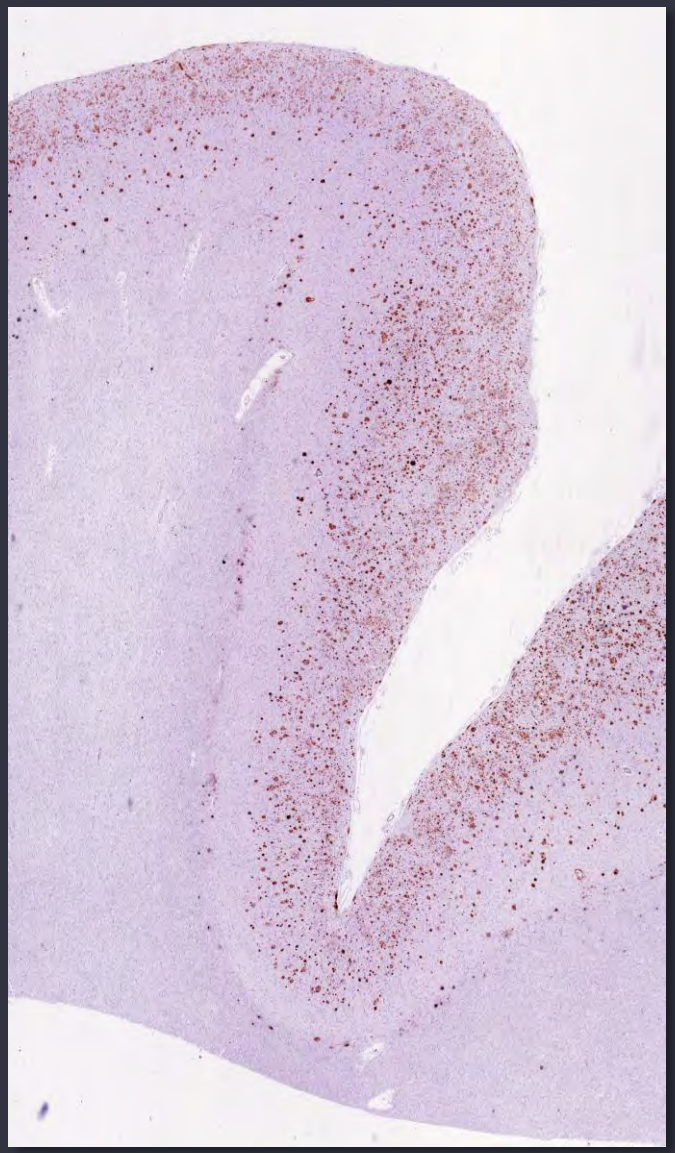

Córtex temporal CERAD, Tau AT100

PLACAS DIFUSAS

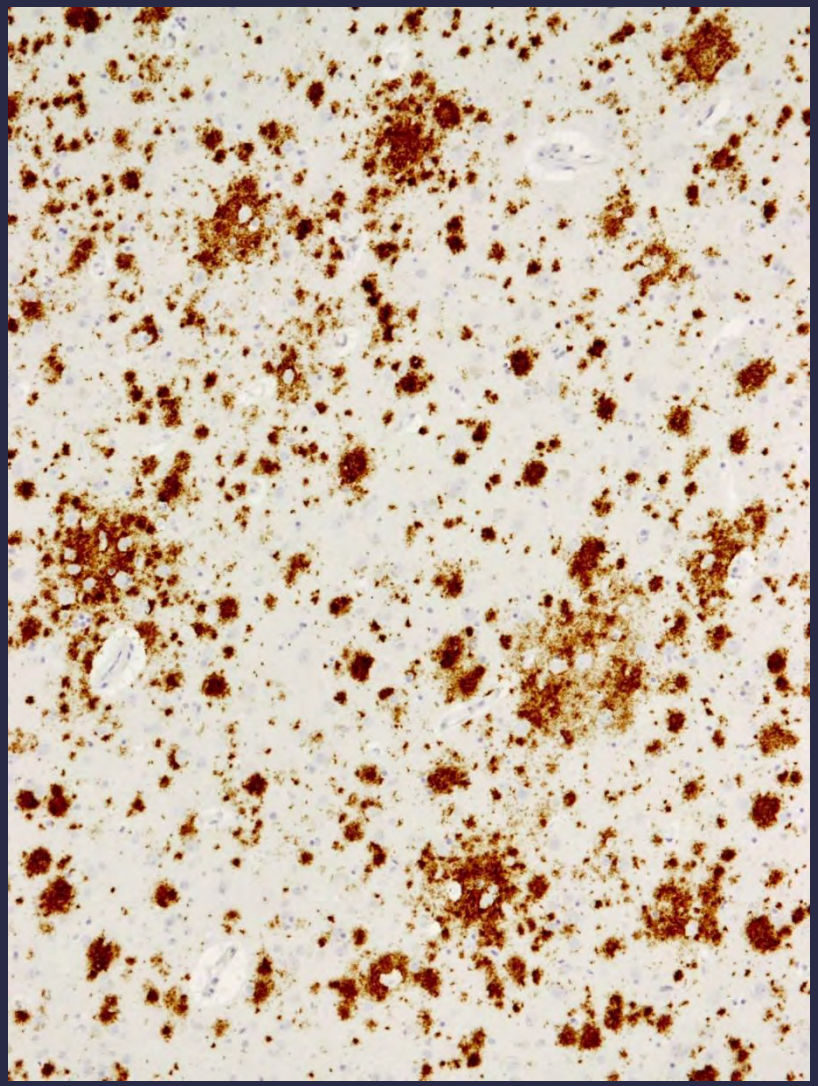

PLACAS NEURÍTICAS

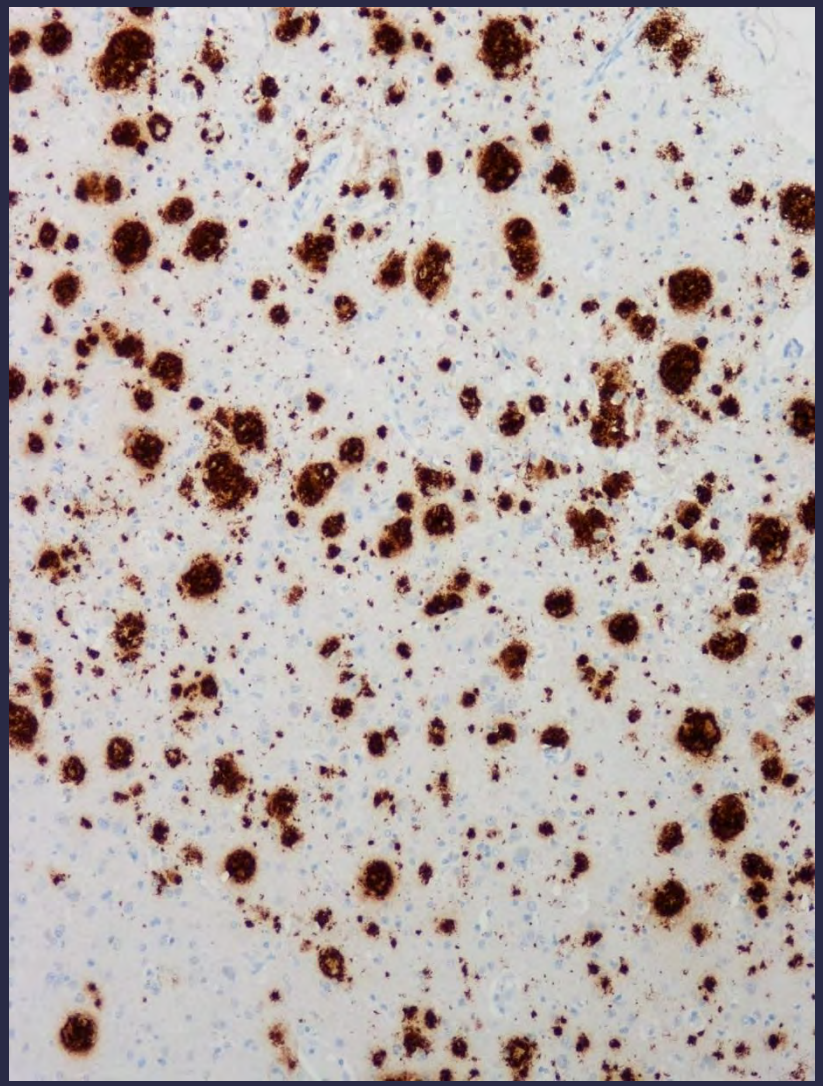

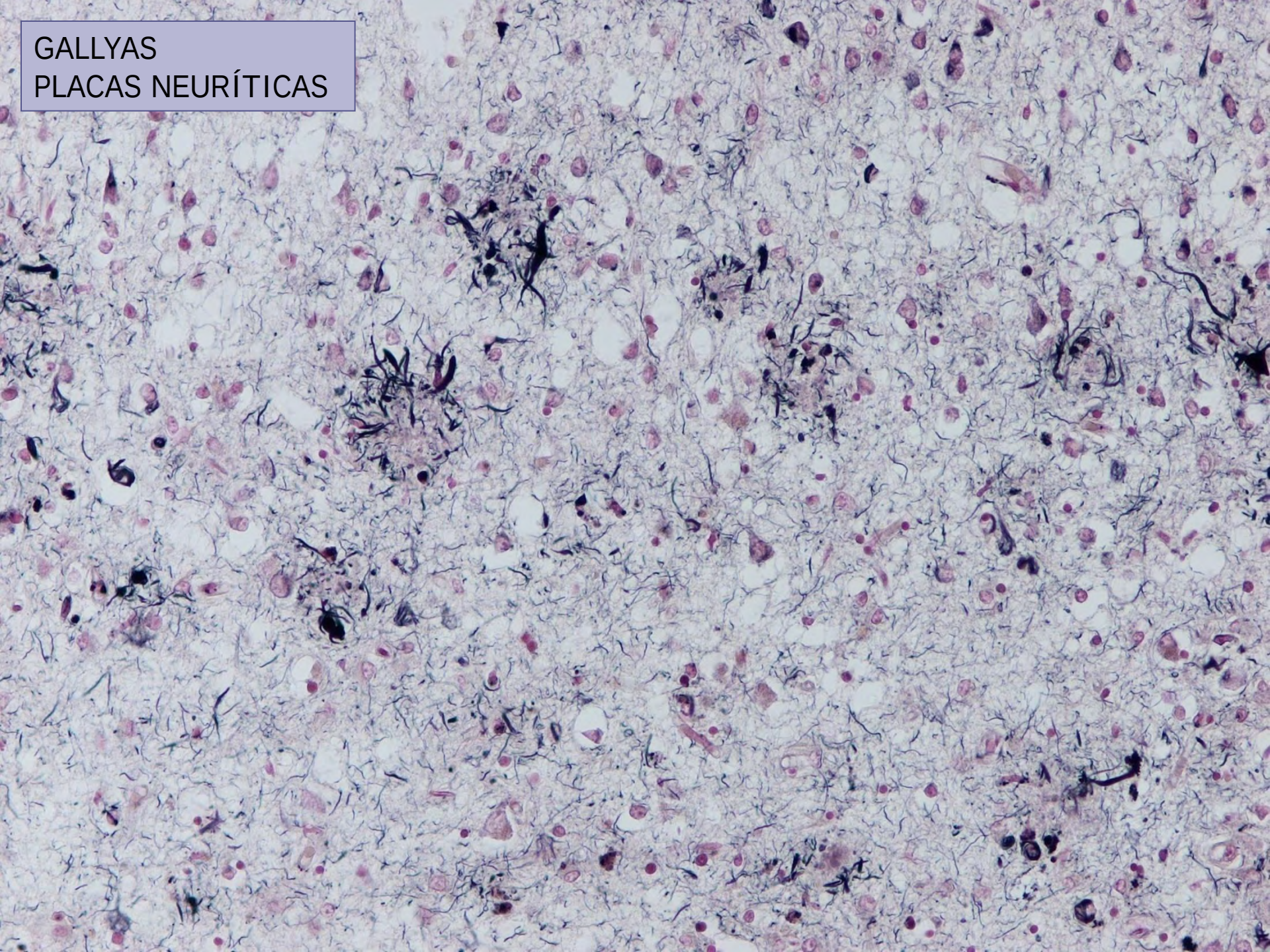
GALLYAS
PLACAS NEURÍTICAS

GALLYAS
OVILLOS NEUROFIBRILARES

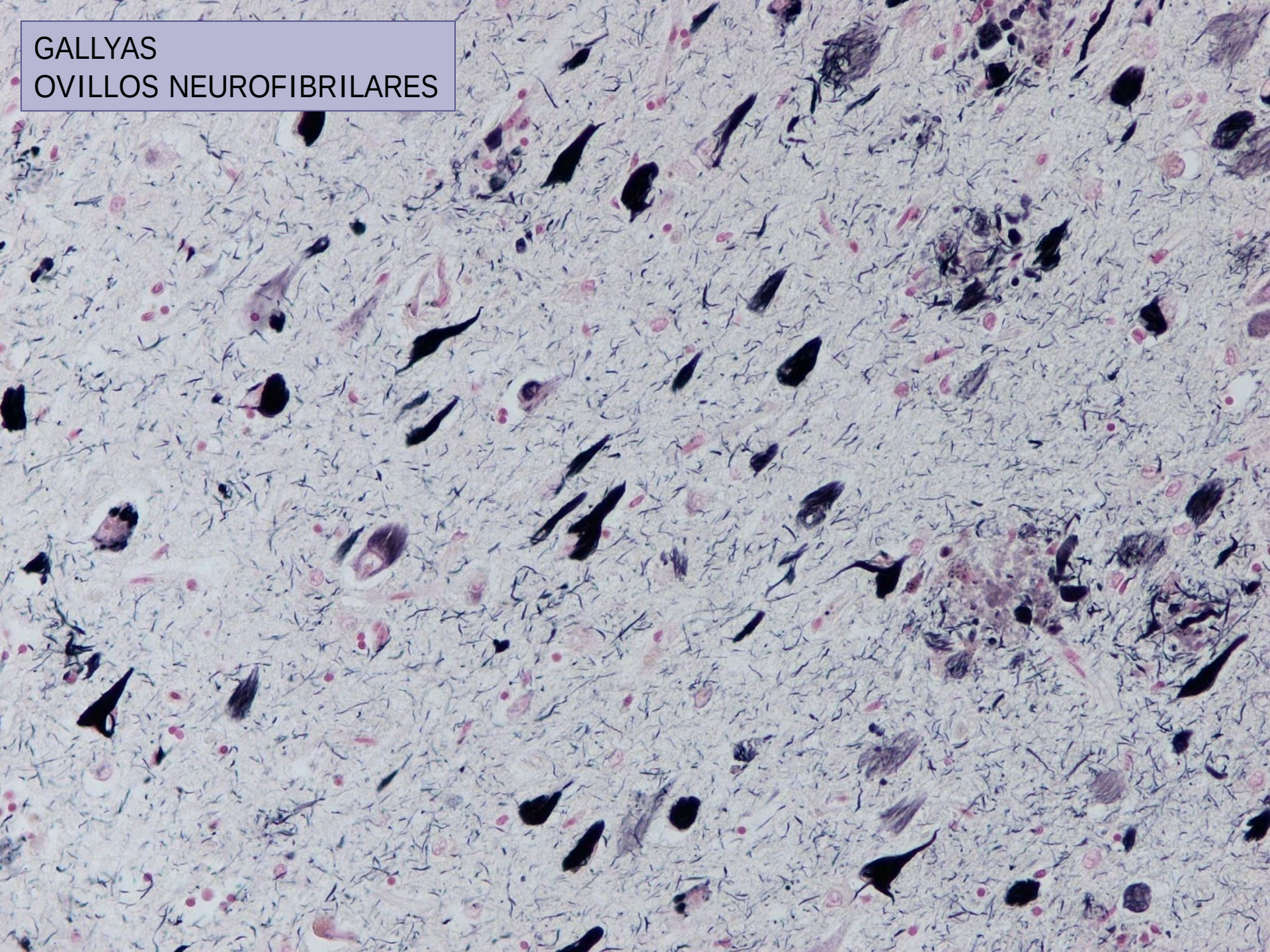

ELSEVIER

Alzheimer's & Dementia 8 (2012) 1–13

Alzheimer's & Dementia

Featured Articles

National Institute on Aging–Alzheimer's Association guidelines for the neuropathologic assessment of Alzheimer's disease

Bradley T. Hyman[a], Creighton H. Phelps[b], Thomas G. Beach[c], Eileen H. Bigio[d], Nigel J. Cairns[e,f], Maria C. Carrillo[g], Dennis W. Dickson[h], Charles Duyckaerts[i], Matthew P. Frosch[j], Eliezer Masliah[k,l], Suzanne S. Mirra[m], Peter T. Nelson[n], Julie A. Schneider[o,p,q], Dietmar Rudolf Thal[r], Bill Thies[g], John Q. Trojanowski[s], Harry V. Vinters[t,u], Thomas J. Montine[v,*]

Acta Neuropathol (2012) 123:1–11
DOI 10.1007/s00401-011-0910-3

CONSENSUS PAPER

National Institute on Aging–Alzheimer's Association guidelines for the neuropathologic assessment of Alzheimer's disease: a practical approach

Thomas J. Montine · Creighton H. Phelps · Thomas G. Beach · Eileen H. Bigio · Nigel J. Cairns · Dennis W. Dickson · Charles Duyckaerts · Matthew P. Frosch · Eliezer Masliah · Suzanne S. Mirra · Peter T. Nelson · Julie A. Schneider · Dietmar Rudolf Thal · John Q. Trojanowski · Harry V. Vinters · Bradley T. Hyman

Se reconoce que los cambios neuropatológicos de la EA pueden darse en ausencia (aparente) de trastorno cognitivo.

Se recomienda el uso de un score "ABC" para la evaluación de los cambios neuropatológicos de EA, que incorpora (A) la evaluación histológica de los depósitos de beta-amiloide, el estadiaje de los ovillos neurofibrilares (B), y la puntuación de placas neuríticas (C).

Se recomienda una evaluación más detallada de otras patologías asociadas, como la enfermedad de cuerpos de Lewy, la patología vascular, la esclerosis del hipocampo, y las inclusiones inmunorreactivas para TDP-43.

Score ABC para cambio neuropatológico de EA.

Table 2 "ABC" score for AD neuropathologic change

"A"	Thal Phase for Aβ plaques [57]	"B"	Braak and Braak NFT stage [14,15]	"C"	CERAD neuritic plaque score [41]
0	0	0	None	0	None
1	1 or 2	1	I or II	1	Sparse
2	3	2	III or IV	2	Moderate
3	4 or 5	3	V or VI	3	Frequent

Ejemplo:
Cambio neuropatológico de EA: A1 B2 C3

Fases de depósito de beta-amiloide (modificadas a partir de Thal *et al.*, 2002).

Cold Spring Harb Perspect Med 2011;1:a006189

Block	Region	Phase of Aβ aggregation				
		1	2	3	4	5
Frontal cortex Occipital cortex Hippocampus	Grey matter Grey matter Adjacent temporal cx grey matter	**One or more regions with Aβ**	+/–	+/–	+/–	+/–
	Molecular layer of the dentate gyrus CA4 CA1 Remnants of entorhinal area	–	**One or more regions with Aβ**	+/–	+/–	+/–
Basal forebrain	Hypothalamus Amygdaloid nuclei Nucleus basalis of Meynert	–	–	**One or more regions with Aβ**	+/–	+/–
Midbrain	Central grey Substantia nigra	–	–	–	**One or more regions with Aβ**	+/–
Cerebellum	Molecular cell layer					**With Aβ**

Acta Neuropathol (2009) 117:309–320

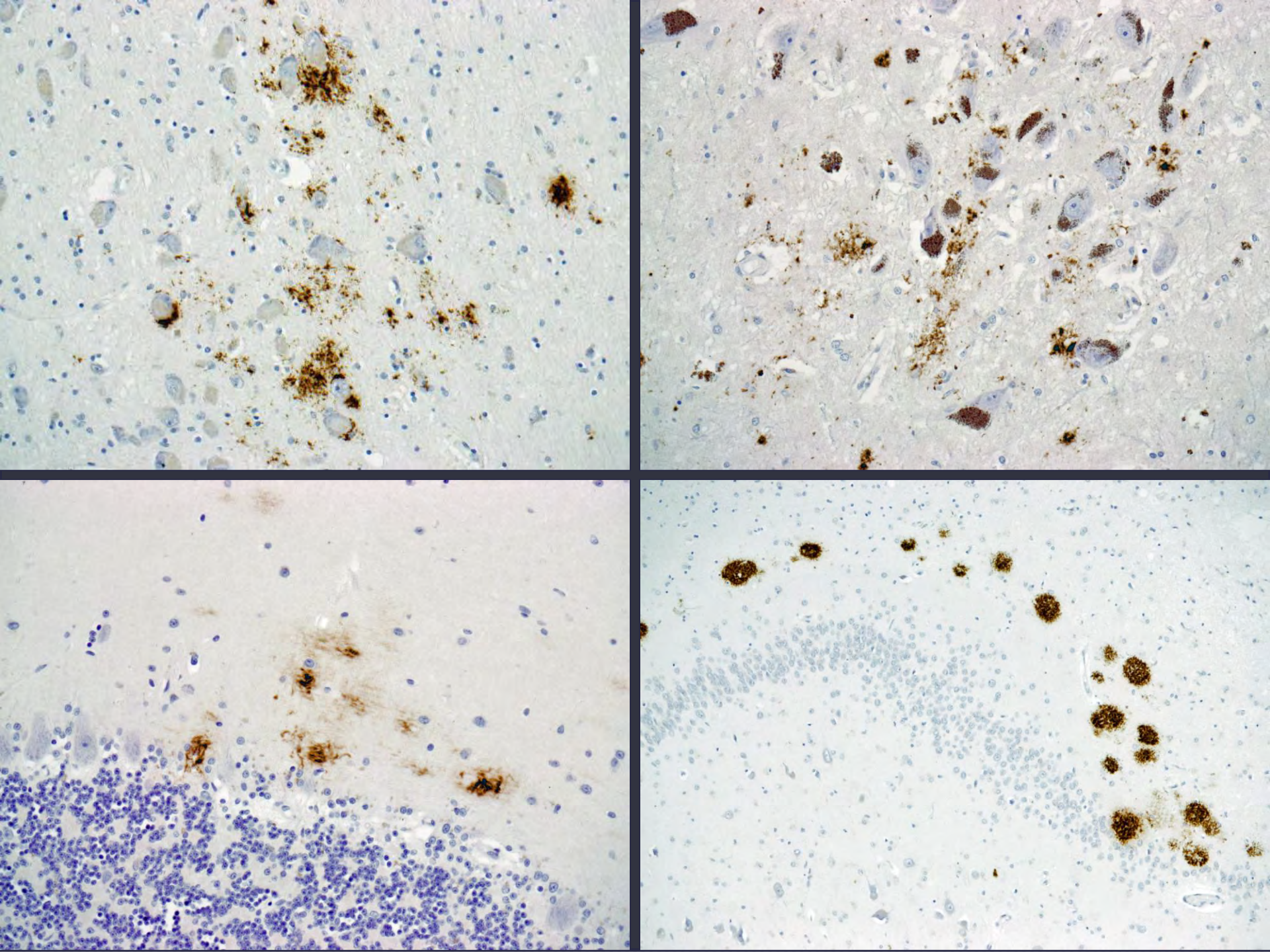

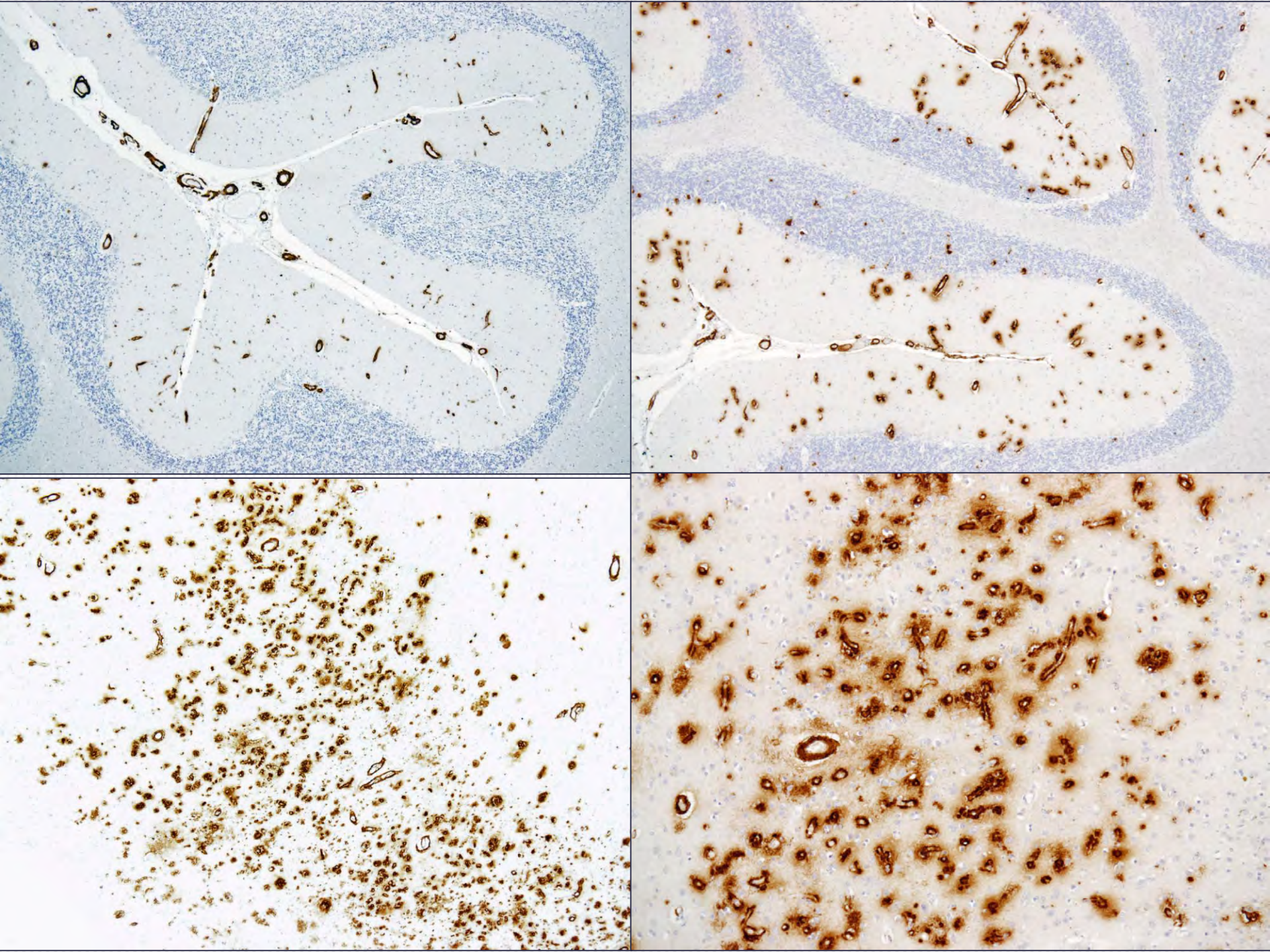

Protocolo CERAD

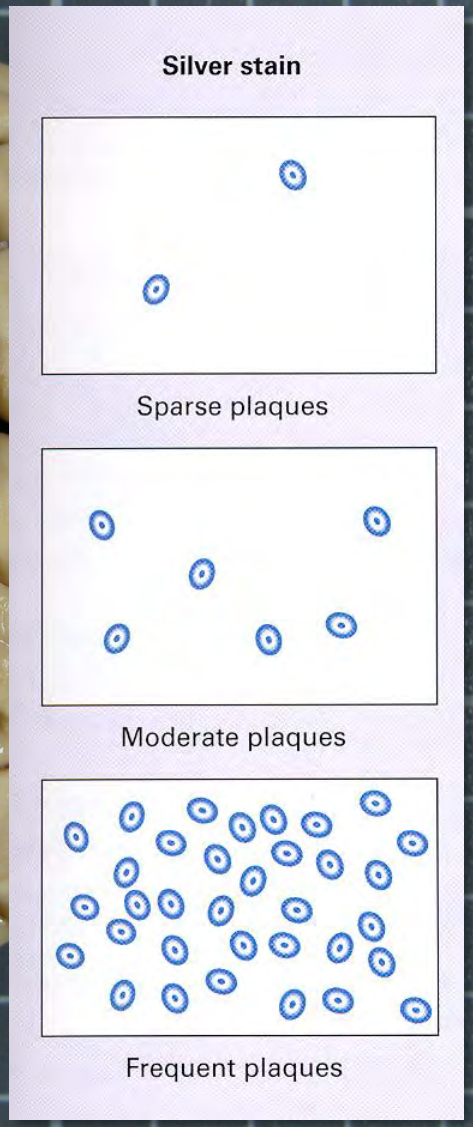

Estadios de Braak & Braak

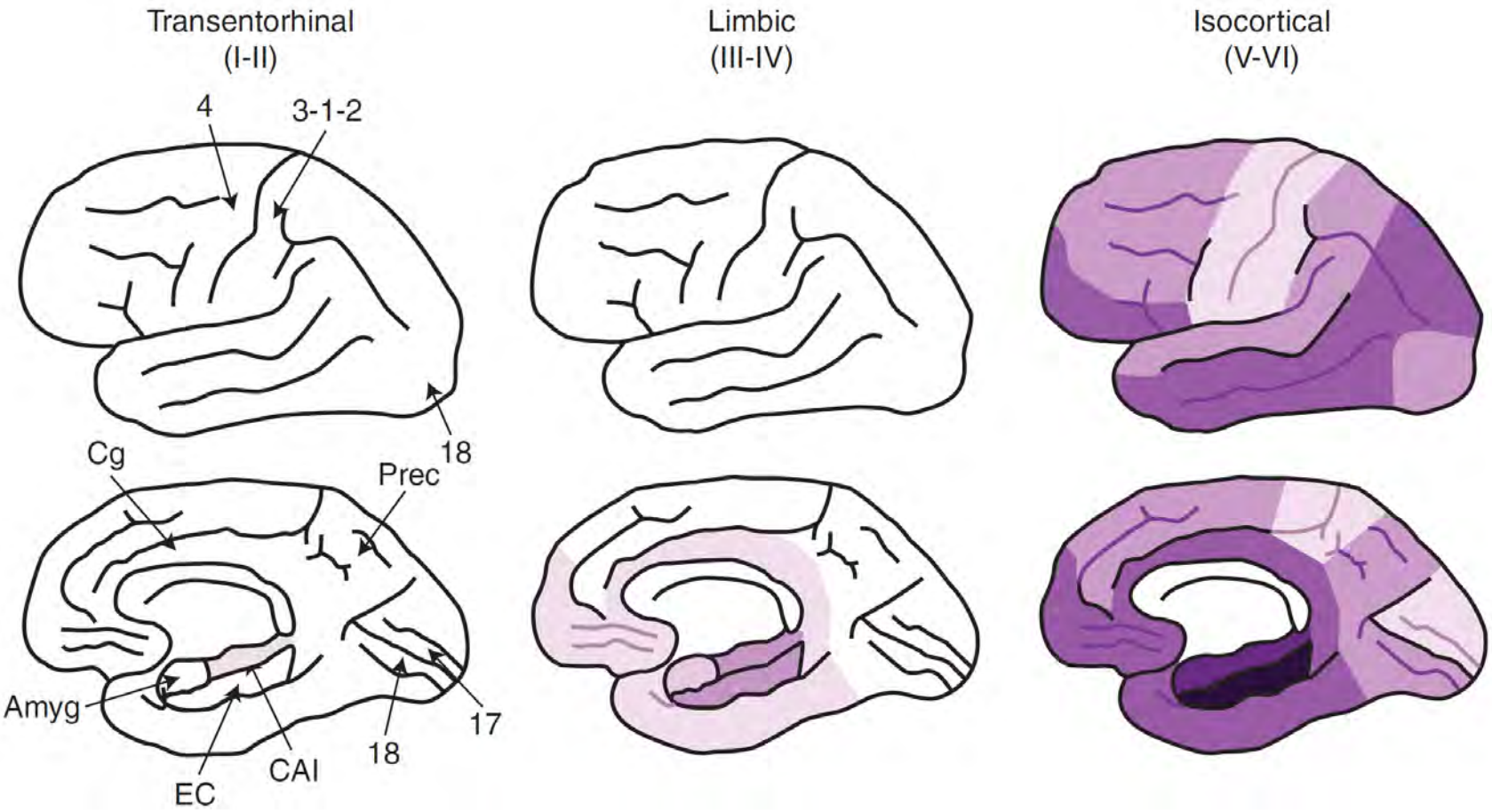

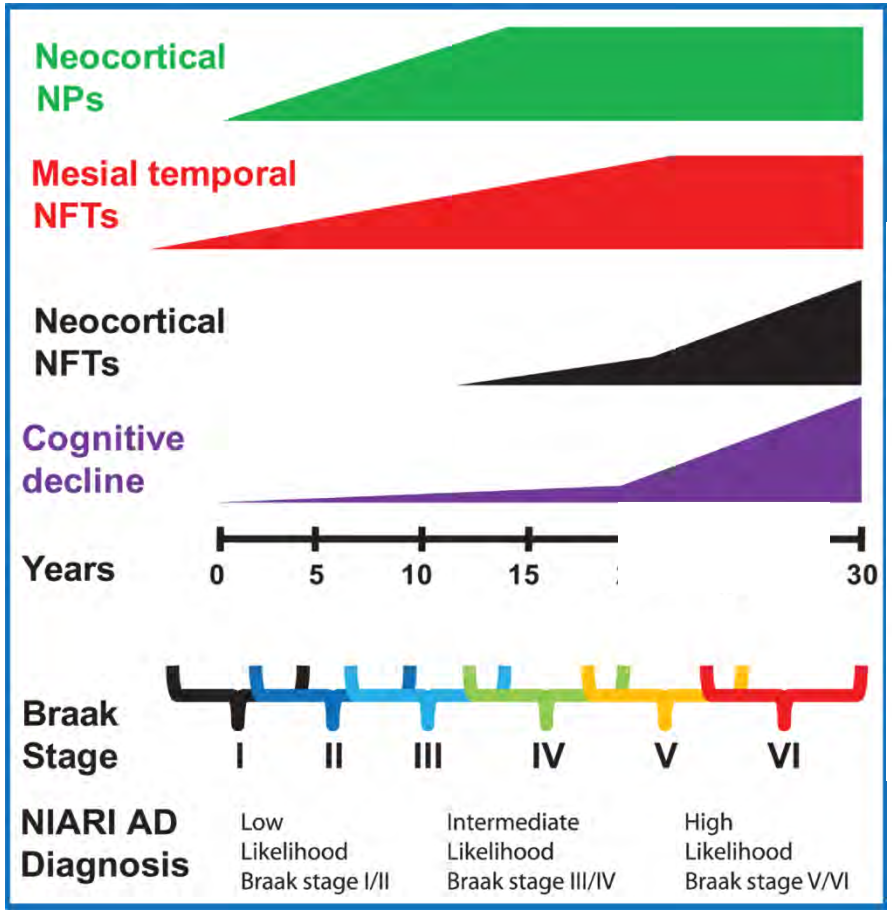

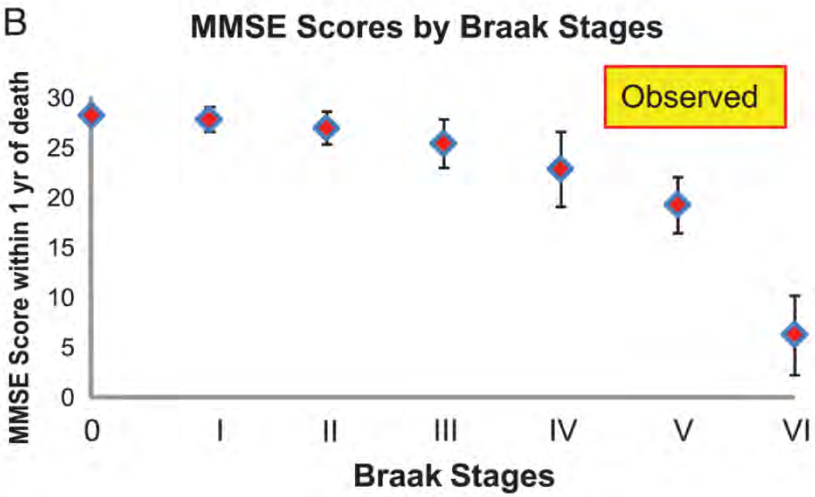

Nelson *et al.*, J Neuropathol Exp neurol. 2009; 68(1): 1-14.

Table 3 "ABC" score for level of AD neuropathologic change

AD neuropathologic change		B[a]		
A[b]	C[c]	0 or 1	2	3
0	0	Not[d]	Not[d]	Not[d]
1	0 or 1	Low	Low	Low[e]
	2 or 3[f]	Low	Intermediate	Intermediate[e]
2	Any C	Low[g]	Intermediate	Intermediate[e]
3	0 or 1	Low[g]	Intermediate	Intermediate[e]
	2 or 3	Low[g]	Intermediate	High

ELSEVIER

Neurobiology of Aging xx (2011) xxx

NEUROBIOLOGY OF AGING

www.elsevier.com/locate/neuaging

Preclinical AD Workgroup staging: pathological correlates and potential challenges

Gregory A. Jicha[a,b,c,*], Erin L. Abner[b,c], Frederick A. Schmitt[a,b,c], Richard J. Kryscio[b,c,d], Kathryn P. Riley[b,c], Gregory E. Cooper[a,b,c], Nancy Stiles[b,c], Marta S. Mendiondo[b,c,d], Charles D. Smith[a,b,e], Linda J. Van Eldik[b,c,e], Peter T. Nelson[b,c,f,*]

[a] Neurology, University of Kentucky College of Medicine, Lexington, KY, USA
[b] Sanders-Brown Center on Aging, University of Kentucky College of Medicine, Lexington, KY, USA
[c] University of Kentucky Alzheimer's Disease Center, University of Kentucky College of Medicine, Lexington, KY, USA
[d] Departments of Biostatistics, University of Kentucky College of Medicine, Lexington, KY, USA
[e] Anatomy and Neurobiology, University of Kentucky College of Medicine, Lexington, KY, USA
[f] Pathology, University of Kentucky College of Medicine, Lexington, KY, USA

Received 12 October 2010; received in revised form 15 February 2011; accepted 24 February 2011

Operational Research Criteria for Defining Preclinical AD

Source: Preclinical AD Workgroup

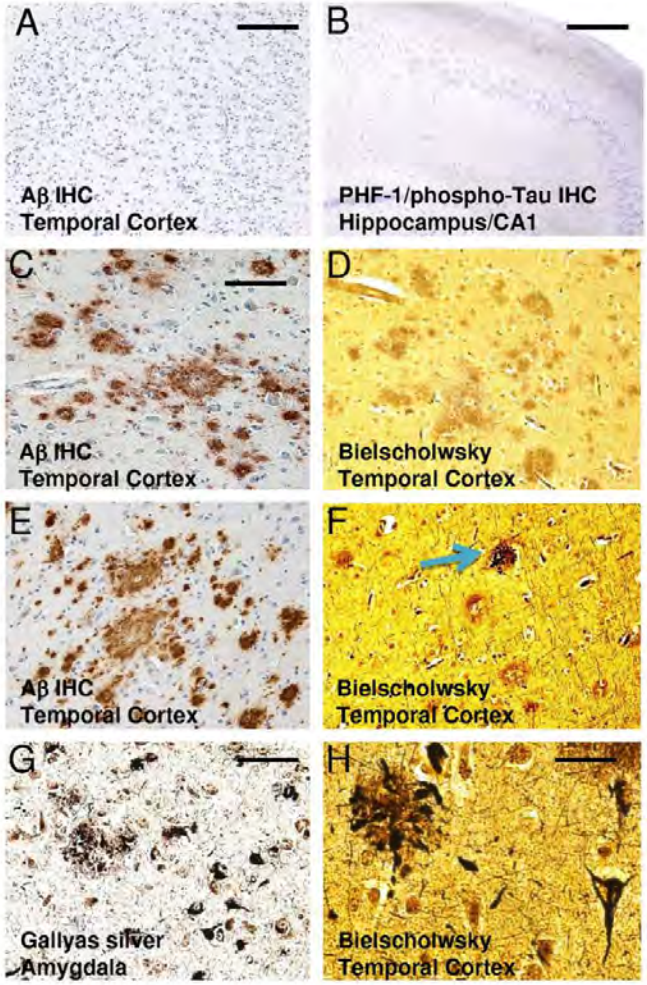

Stage 0 = No cerebral amyloidosis detected

Stage 1 = Asymptomatic cerebral amyloidosis

Stage 2 = Evidence of amyloid positivity + presence of one or more additional AD markers

Stage 3 = Amyloid positivity + markers of neurodegeneration + very early cognitive symptoms

Cognitively intact individuals (N=126) grouped by pathology

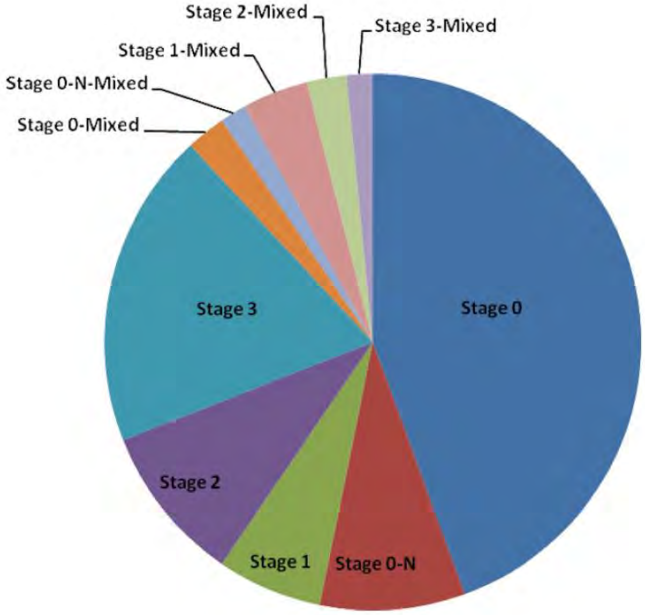

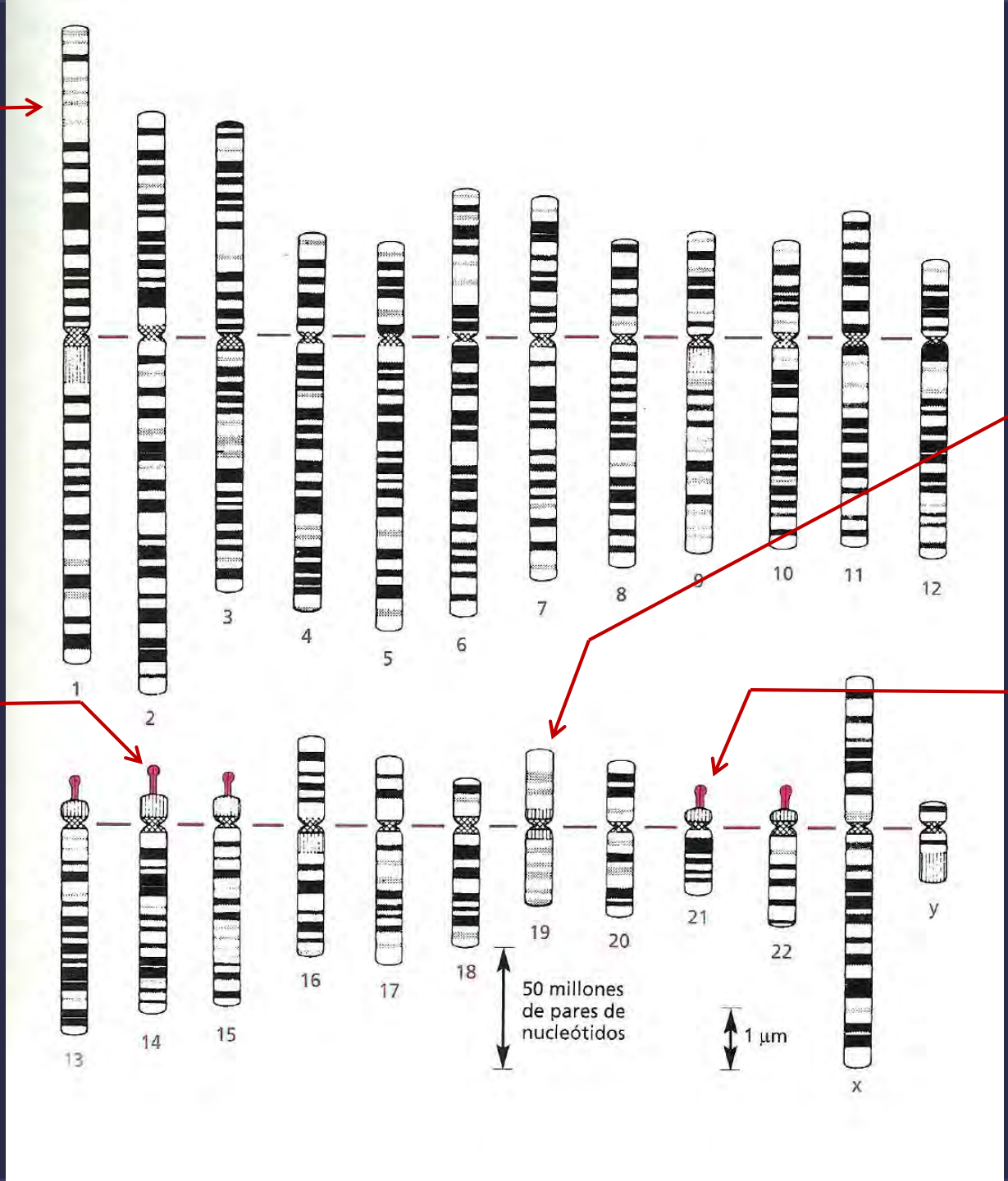
PSEN2
APOE
PSEN1
APP
1
2
3
4
5
6
7
8
9
10
11
12
13
14
15
16
17
18
19
20
21
22
x
y
50 millones
de pares de
nucleótidos
1 µm

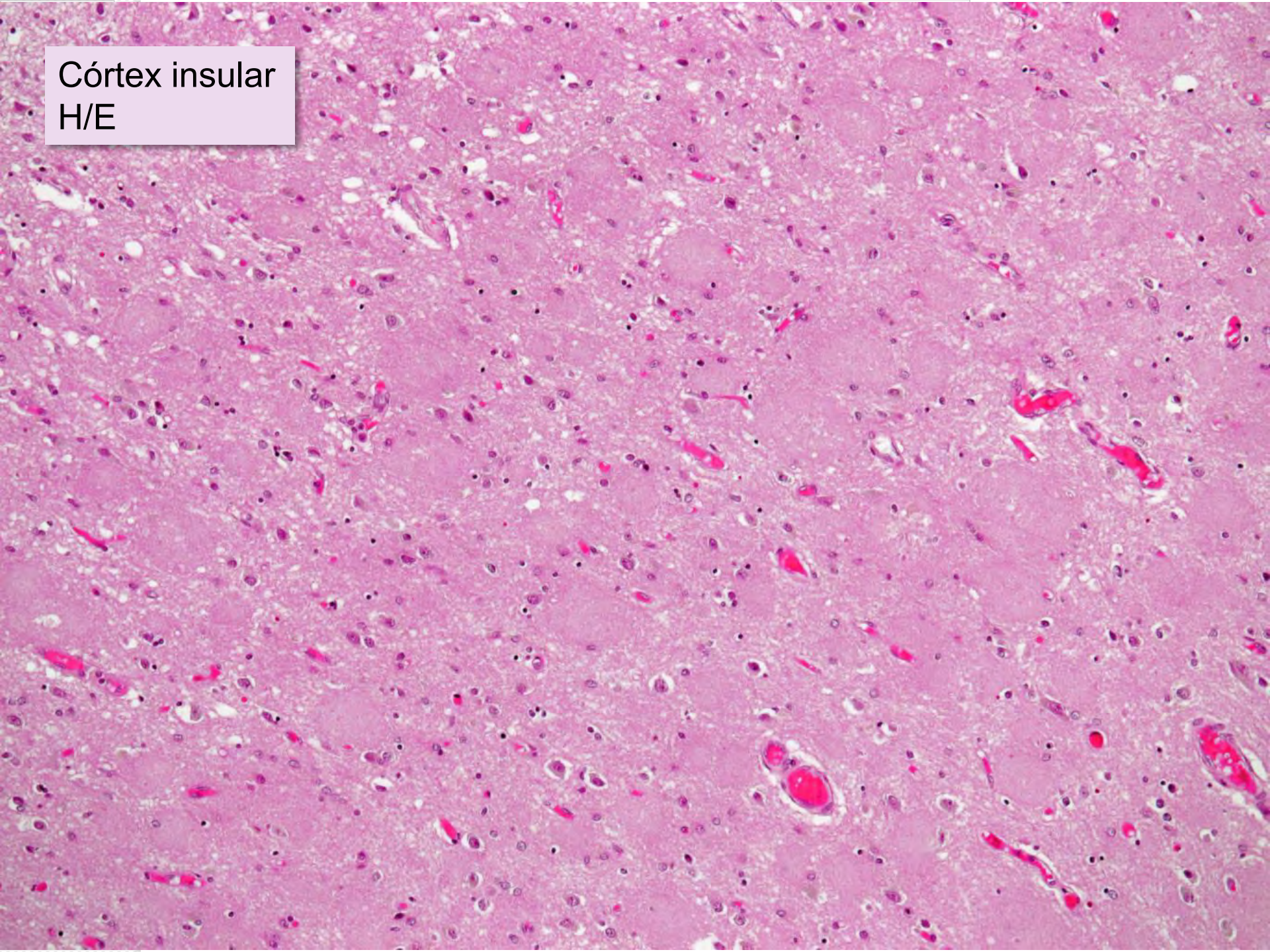
Córtex insular
H/E

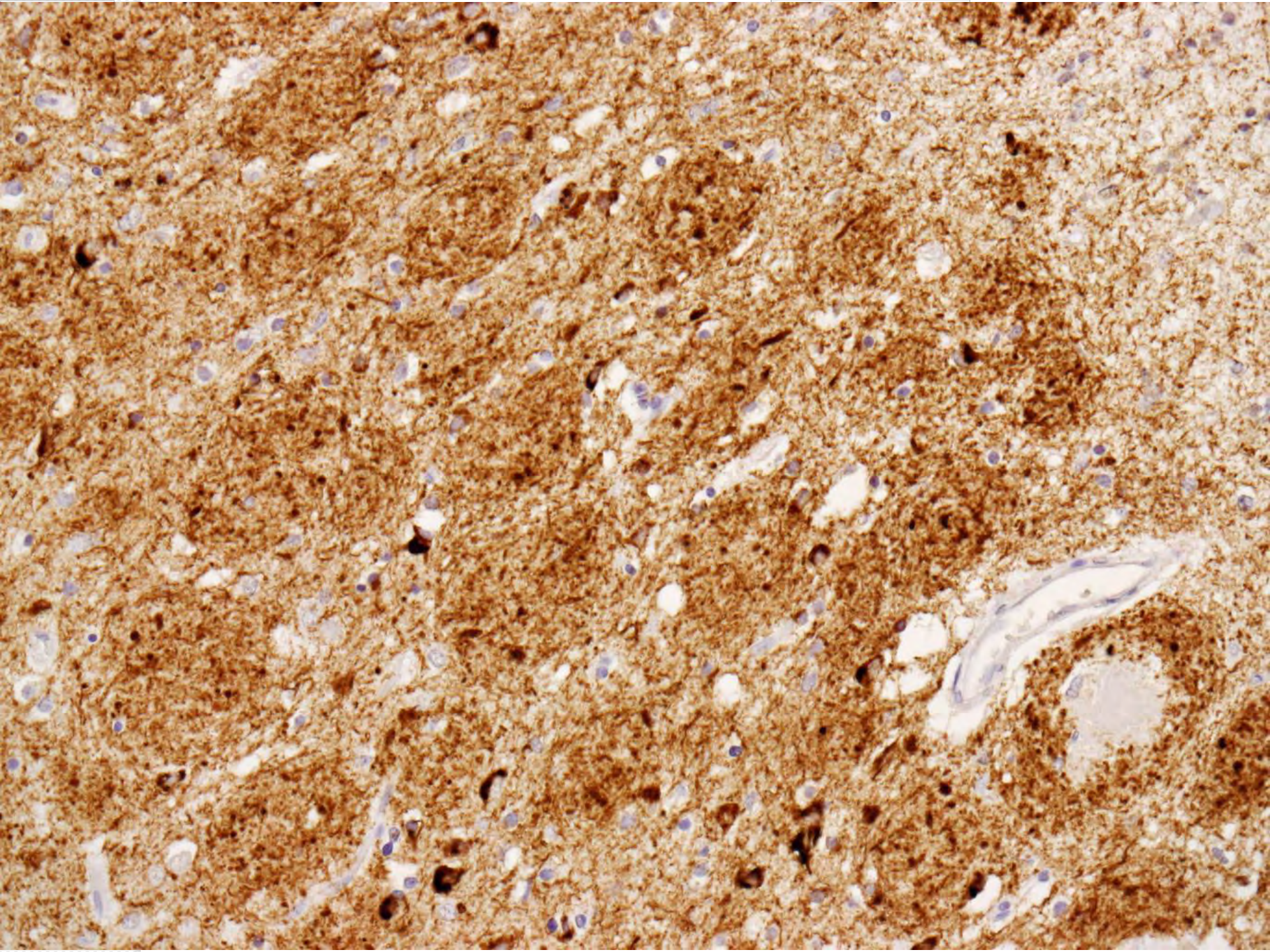

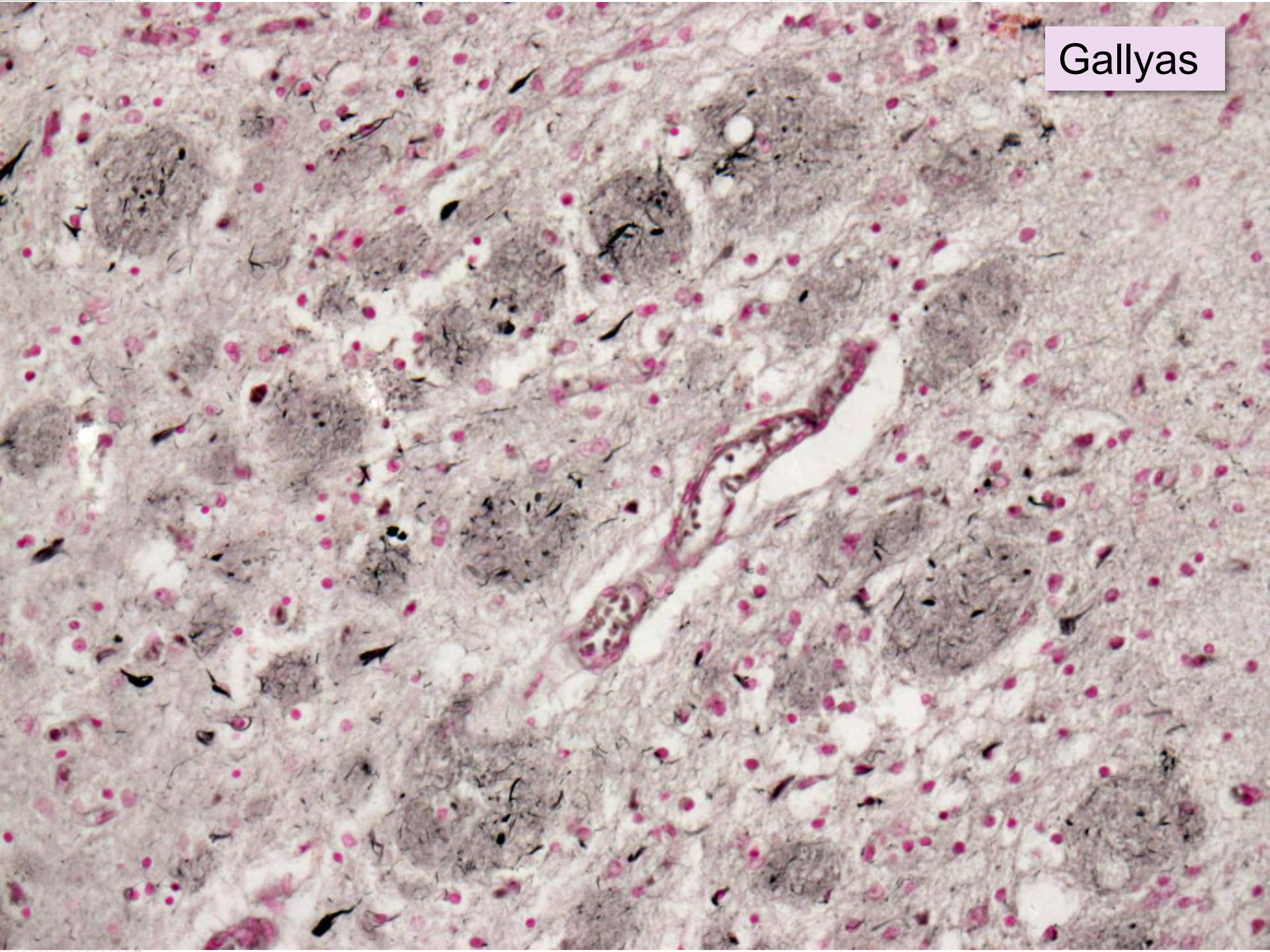
Gallyas

Neuropathologically defined subtypes of Alzheimer's disease with distinct clinical characteristics: a retrospective study

Melissa E Murray, Neill R Graff-Radford, Owen A Ross, Ronald C Petersen, Ranjan Duara, Dennis W Dickson

Lancet Neurol 2011; 10: 785–96

Summary

Background Neurofibrillary pathology has a stereotypical progression in Alzheimer's disease (AD) that is encapsulated

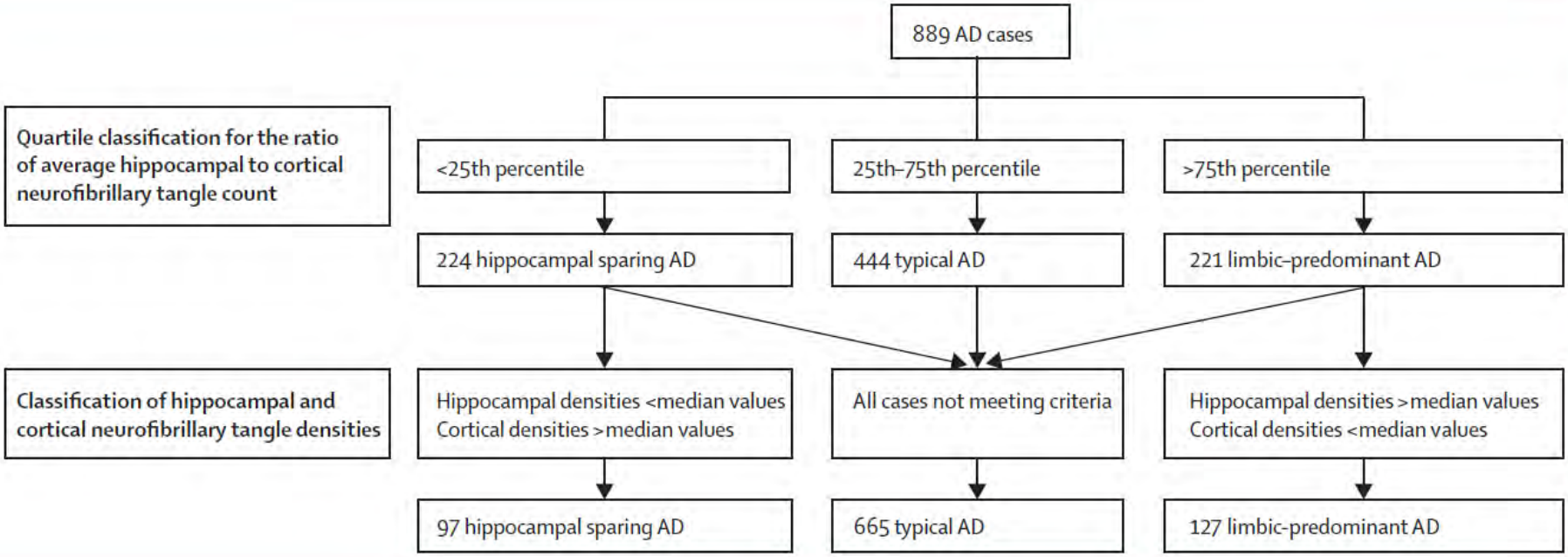

	Hippocampal sparing AD (n=97)	Typical AD (n=665)	Limbic-predominant AD (n=127)	p value	
				Overall	Hippocampal AD *vs* typical
Demographic characteristics					
Age at death (years)	72 (10)	79 (9)	86 (6)	<0·001†	<0·001
Women	36 (37%)	368 (55%)	87 (69%)	<0·001‡	0·001
Education (years)	15 (3)	14 (3)	14 (3)	0·14†	0·24
Post-mortem findings					
Lewy body pathology	11/97 (11%)	172/665 (26%)	33/127 (26%)	0·007‡	0·017	0·002	0·54
Clinical findings¶					
Age at onset (years)	63 (10)	69 (10)	76 (7)	<0·001†	<0·001	<0·001	<0·001
Disease duration (years)	8 (3)	9 (4)	10 (4)	0·009†	0·008	0·004	0·56
Atypical clinical presentation	27/91 (30%)	102/606 (17%)	7/113 (6%)	<0·001‡	0·005	<0·001	0·006
Mini-mental state examination‖							
Initial score	20 (15 to 25)	23 (15 to 26)	23 (18 to 28)	0·64§	0·61	0·36	0·56
Final score	7 (2 to 13)	11 (6 to 16)	15 (8 to 19)	0·08§	0·07	0·045	0·23
Longitudinal decline	−4·8 (−8·3 to −3·1)	−2·8 (−4·4 to −1·5)	−1·4 (−2·8 to −0·8)	0·009§	0·017	0·002	0·054

Data are mean (SD), n (%), median (IQR), or n/N (%). AD=Alzheimer's disease. TDP-43=TAR DNA binding protein 43. *Pairwise comparisons were done with the *t* test for mean values and Mann-Whitney rank sum test for median values. †ANOVA test. ‡χ^2 test. §ANOVA test on ranked data. ¶Score assessed within 3 years of symptom onset (initial) or death (final). ‖After clinical history was reviewed, a subset of cases had clinical data available for hippocampal sparing AD (n=97), typical AD (n=232), and limbic-predominant AD (n=127), respectively: 43, 160, and 46 had data for mini-mental state examination recorded at one visit or more; and 18, 52, and 18 had data for longitudinal mini-mental state examination (recorded at three visits or more).

Table 1: **Characteristics of patients by AD subtype**

Neuropathologically defined subtypes of Alzheimer's disease with distinct clinical characteristics: a retrospective study

Melissa E Murray, Neill R Graff-Radford, Owen A Ross, Ronald C Petersen, Ranjan Duara, Dennis W Dickson

Lancet Neurol 2011; 10: 785–96

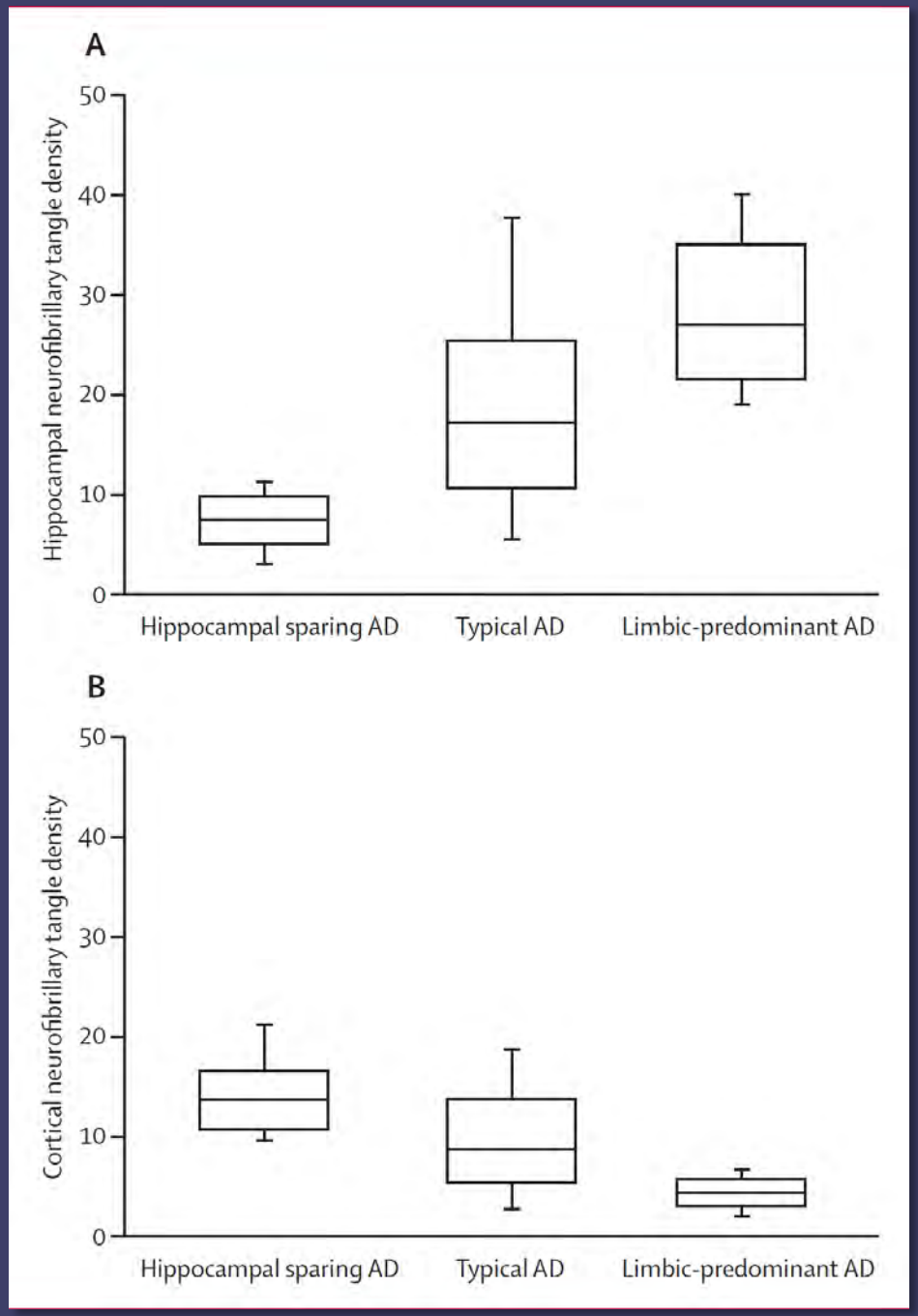

Densidad de ONF en hipocampo

Densidad de ONF en córtex

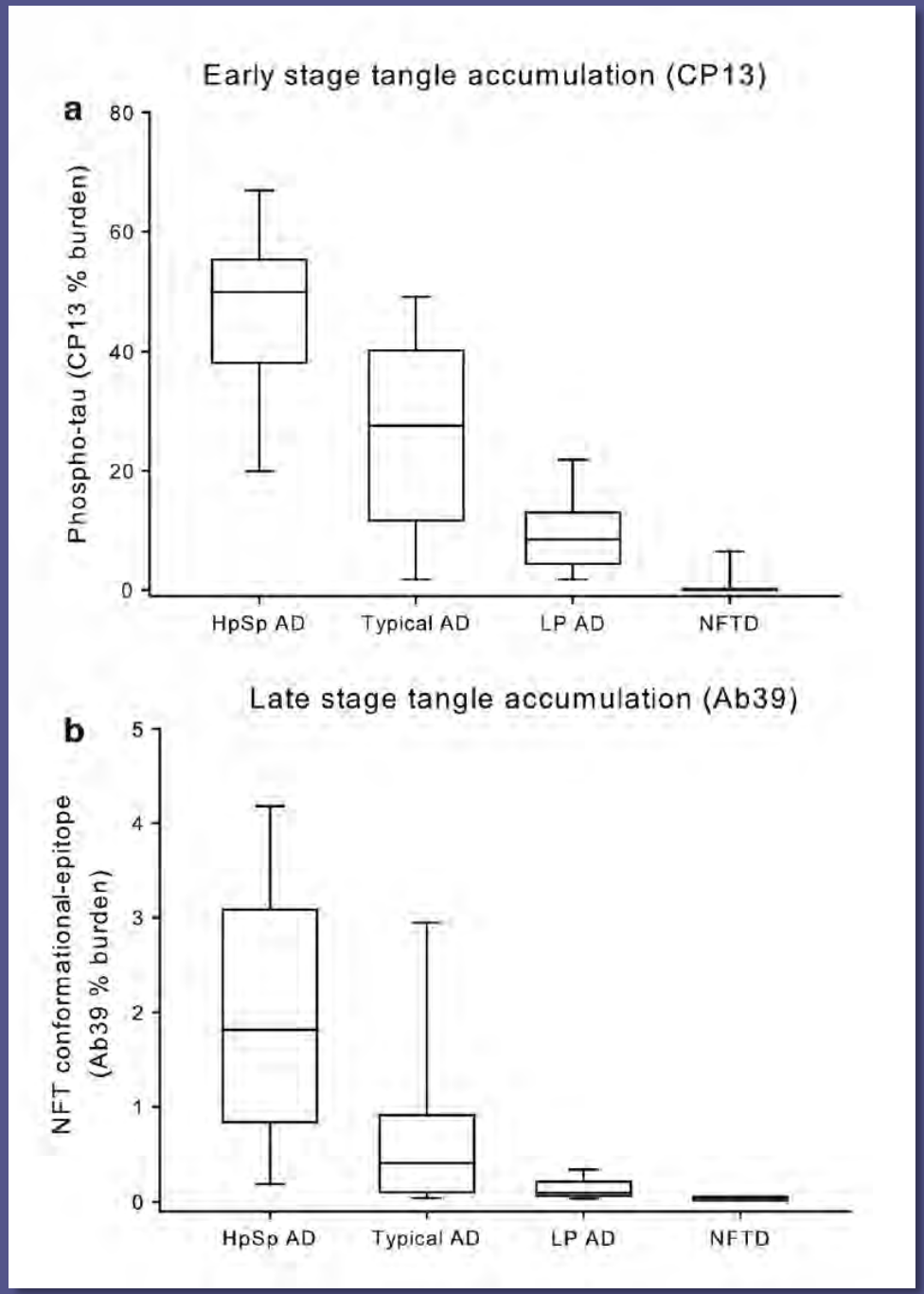

Janocko *et al*. Acta Neuropathol. 2012; 124(5): 681–692.

00.2 2

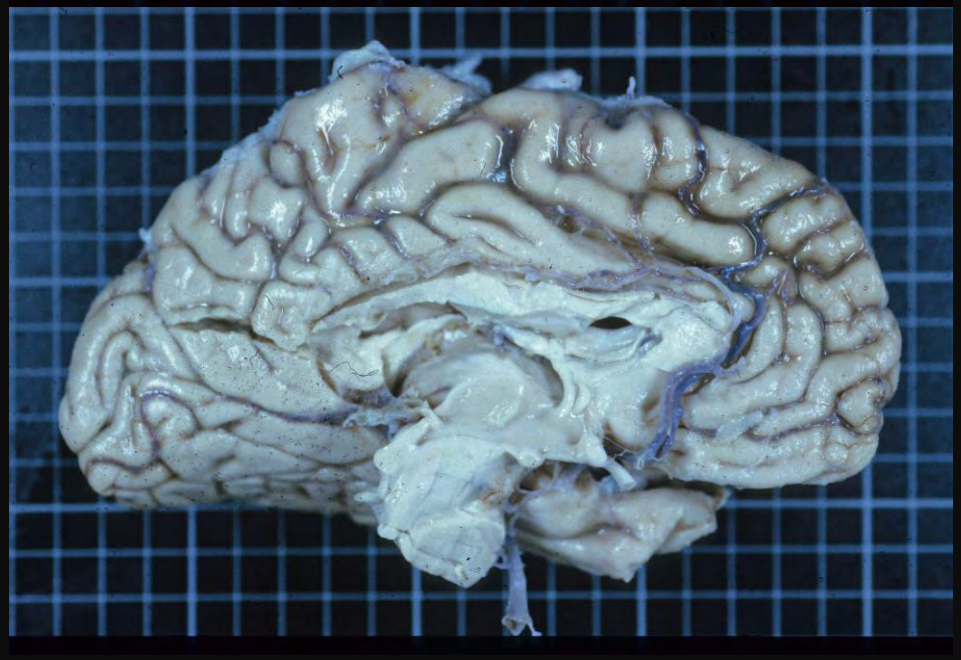

Clinically concordant variations of Alzheimer pathology in aphasic versus amnestic dementia

Tamar Gefen,[1,2] Katherine Gasho,[1] Alfred Rademaker,[1,3] Mona Lalehzari,[1] Sandra Weintraub,[1,2,4] Emily Rogalski,[1] Christina Wieneke,[1] Eileen Bigio,[1,4] Changiz Geula[1,*] and M.-Marsel Mesulam[1,2,4,*]

Brain 2012: 135; 1554–1565

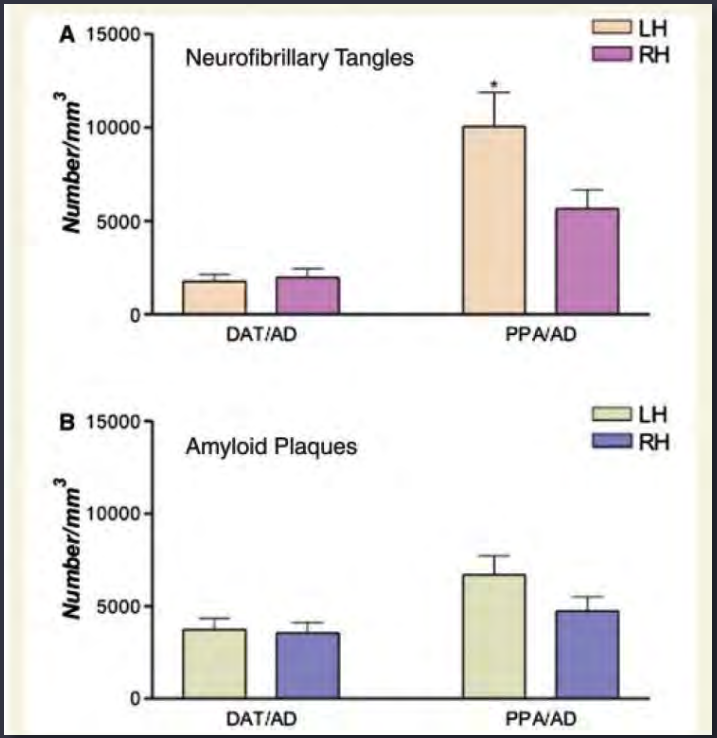

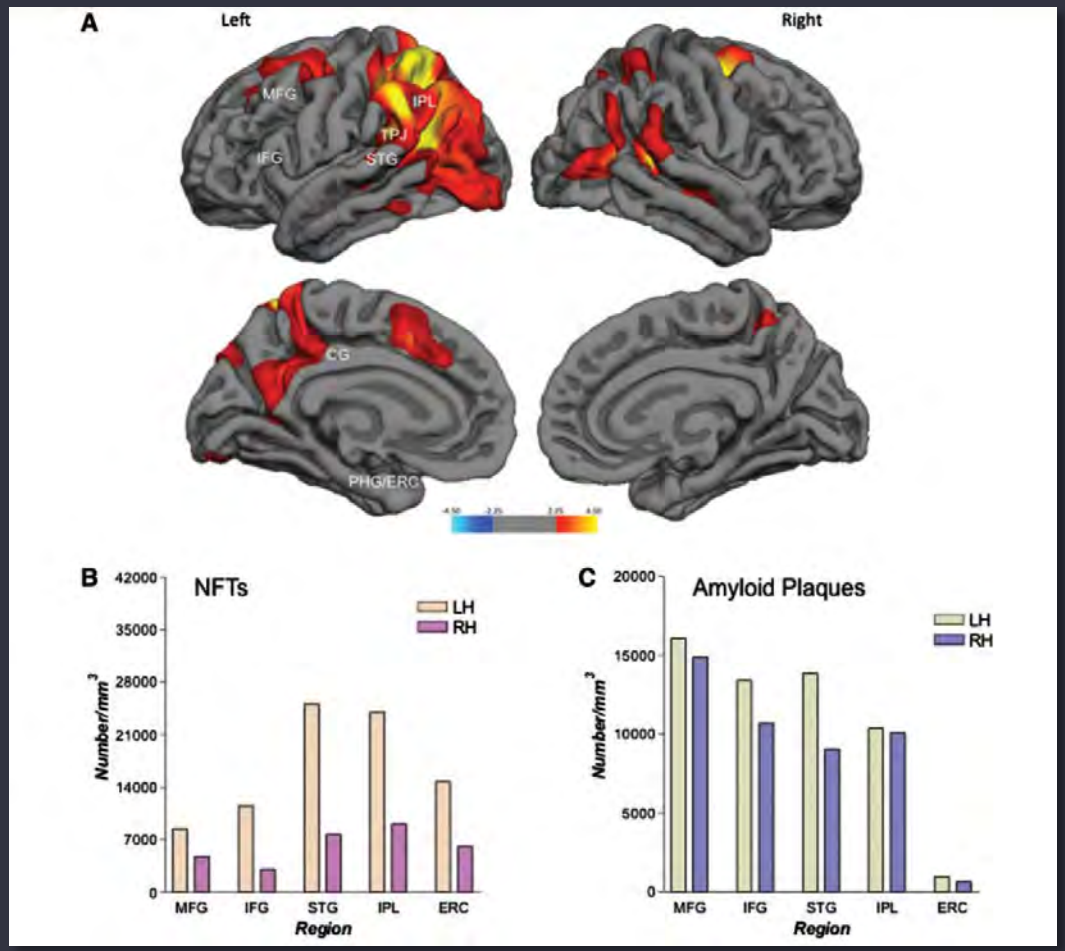

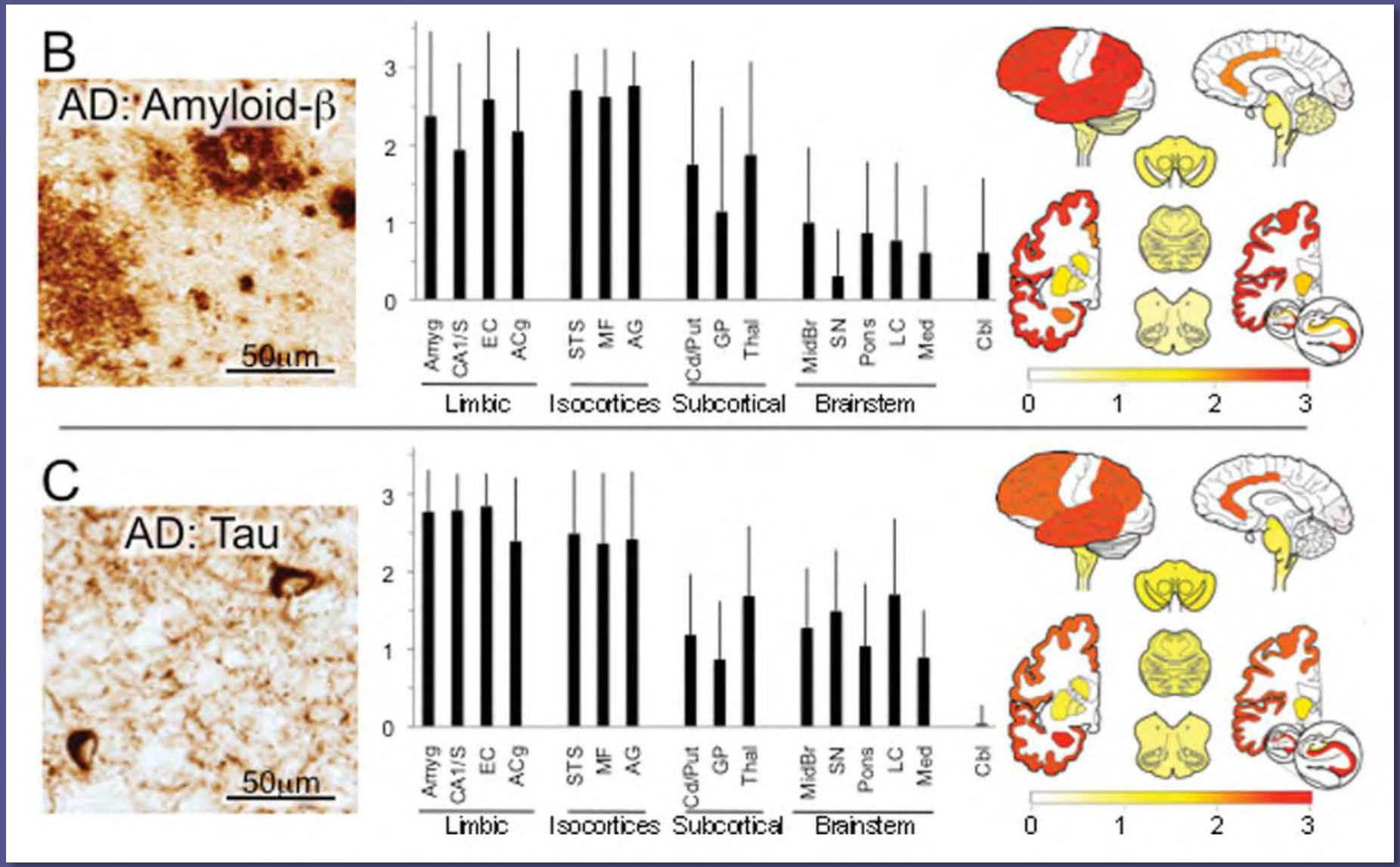

Arnold SE *et al.*, J Comp Neurol. 2013 521: 4339-55

MEDICINE

Prion-Like Behavior of Amyloid-β

Jungsu Kim and David M. Holtzman

Can certain neurodegenerative diseases be transmitted between humans by an infectious agent? The discovery that protein particles called prions can enter healthy mammals, including humans, and trigger a cascade of endogenous protein misfolding associated with bovine spongiform encephalopathy ("mad cow disease") and Creutzfeldt-Jakob disease, certainly demonstrates this in prion diseases. Remarkably, neuronal proteins such as tau, α-synuclein, and polyglutamine aggregates, which are causally implicated in the neurodegenerative disorders Alzheimer's disease, Parkinson's disease, and Huntington's disease, respectively, can be released from donor cells and taken up by neighboring acceptor cells. Moreover, treatment with exogenous misfolded neuronal proteins, such as tau, can trigger the misfolding and aggregation of their properly folded endogenous counterparts in host cells and animals (*1*). Besides prions, there is yet no evidence that other neurodegenerative diseases associ-

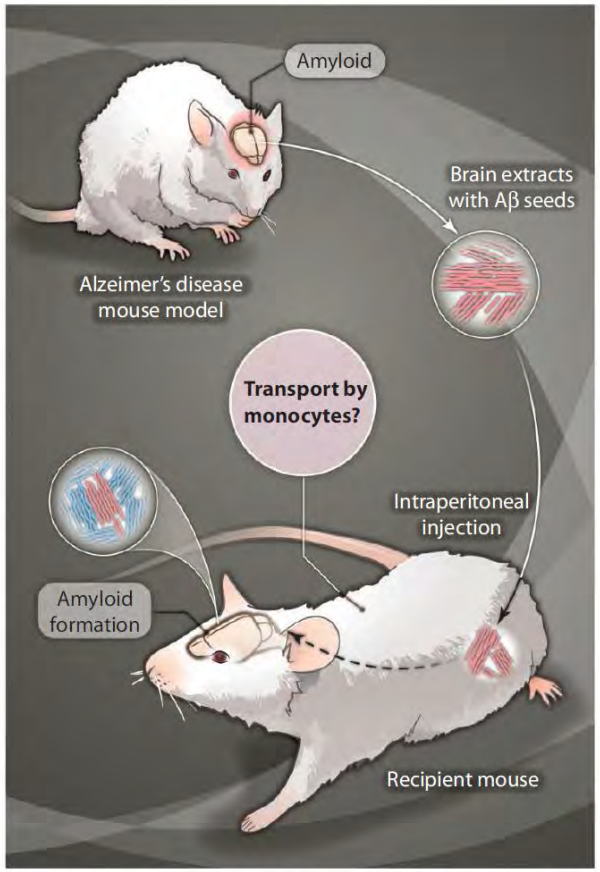

Amyloid transmission. Injection of mouse brain extract containing Aβ seeds (similar to those found in the Alzheimer's disease brain) into the peritoneal cavity of mice (that are genetically engineered to develop amyloid plaques) accelerates Aβ deposition in the host brain. The transport mechanism from peripheral tissue to the brain is unclear.

Cell

Leading Edge
Perspective

Transmissible Proteins: Expanding the Prion Heresy

Claudio Soto[1,*]
[1]Mitchell Center for Alzheimer's Disease and Related Brain Disorders, Department of Neurology, University of Texas Houston Medical School, Houston, TX 77030, USA
*Correspondence: claudio.soto@uth.tmc.edu
DOI 10.1016/j.cell.2012.05.007

Stanley B. Prusiner (1942)

Premio Nobel de Fisiología o Medicina
1997

"for his discovery of Prions - a new biological principle of infection".

Proteína priónica celular (PrP^C)

	Previous nomenclature
Familial	
Phenotype	
CJD	Unchanged
Fatal familial insomnia	Not described
Gerstmann-Sträussler-Scheinker disease	Unchanged
Heterogeneous or mixed phenotype	Unchanged
Sporadic	
Phenotype	
CJD 129MM1 and CJD 129MV1*†	Myoclonic and Heidenhain¶
CJD 129VV1	Not described
CJD 129MM2	Not described
CJD 129MV2	Cerebellar or ataxic
CJD 129VV2	Cerebellar or ataxic
Fatal insomnia‡	Thalamic
Variably protease-sensitive prionopathy§	Not described
Acquired by infection	
Phenotype	
Kuru	Unchanged
Variant CJD	Not described
Iatrogenic CJD	Unchanged

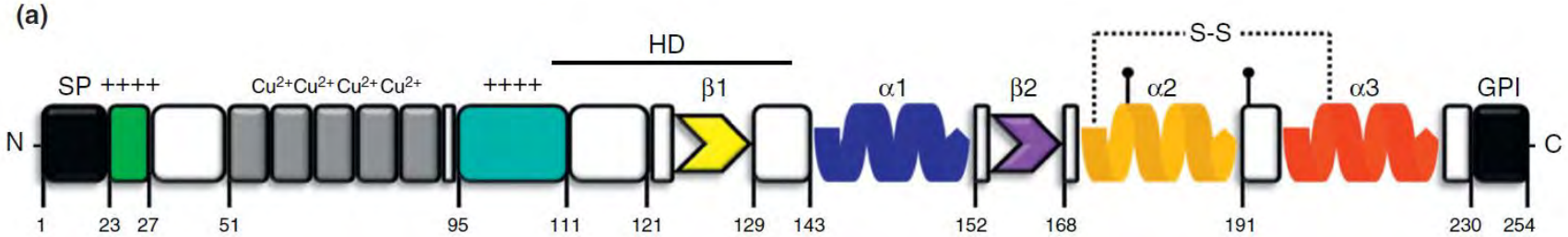

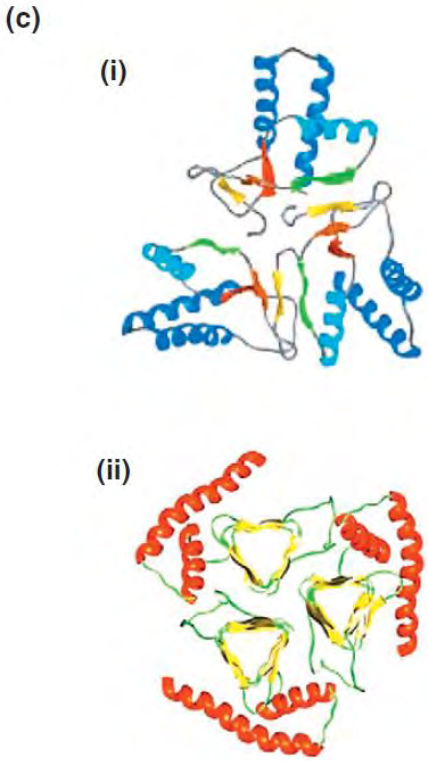

TRENDS in Neurosciences



ECJ transmitida

X

PrP^{C}

α

β

PrP^{Sc}

β

PrP infecciosa ?

PrP tóxica ?

β β β β β
β β β β β

ECJ de tipo esporádico

?

ECJ de origen genético

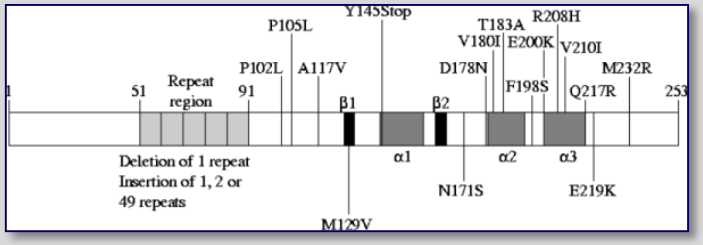

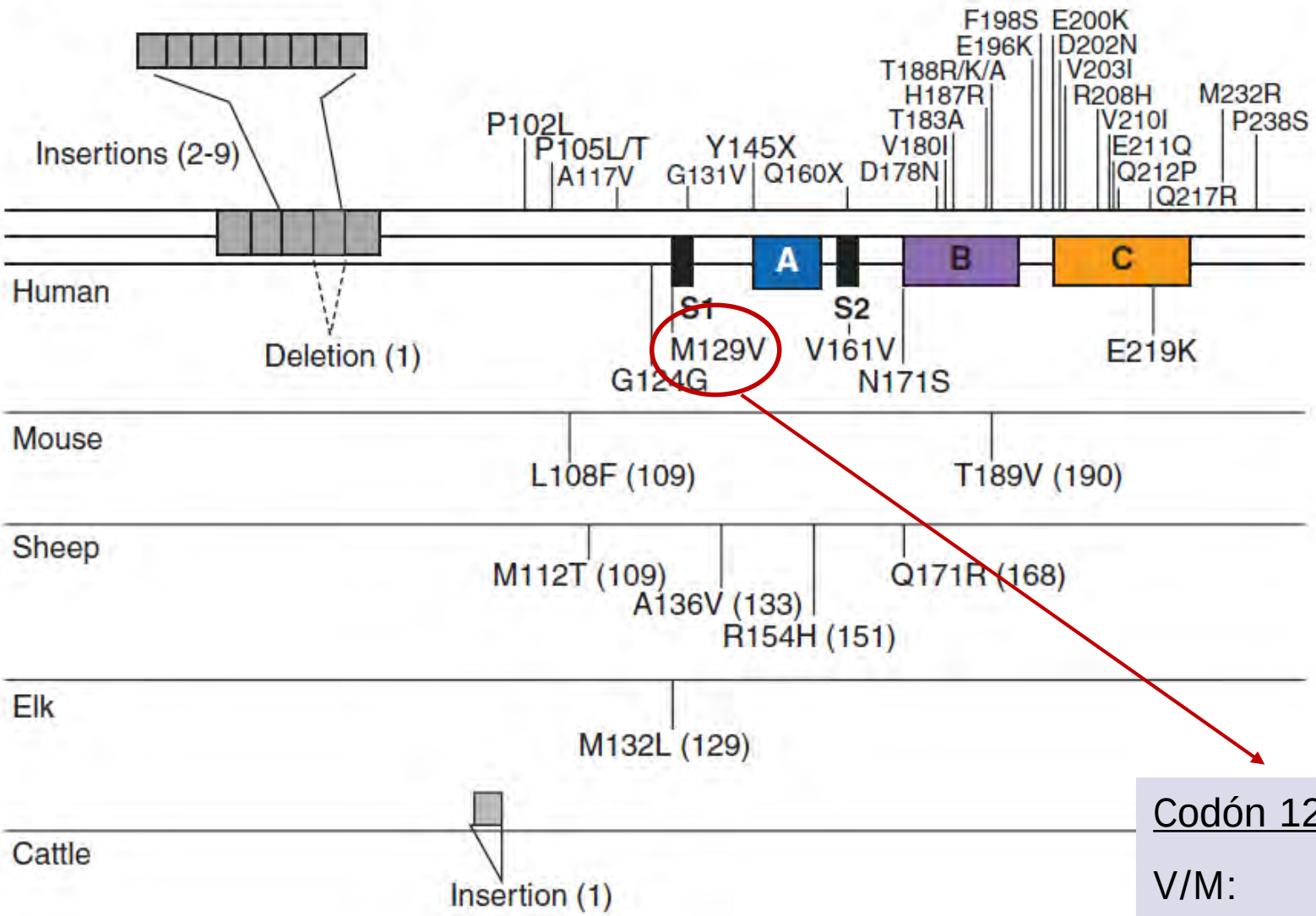

Codón 129:

V/M: 52%
M/M: 36%
V/V: 12%

A

Codon 129 genotypes and their prevalence in sCJD

B

Pairing of the 129 genotype with PrP^{Sc} type

C

PrP^{Sc} types 1 and 2 with their sites of cleavage

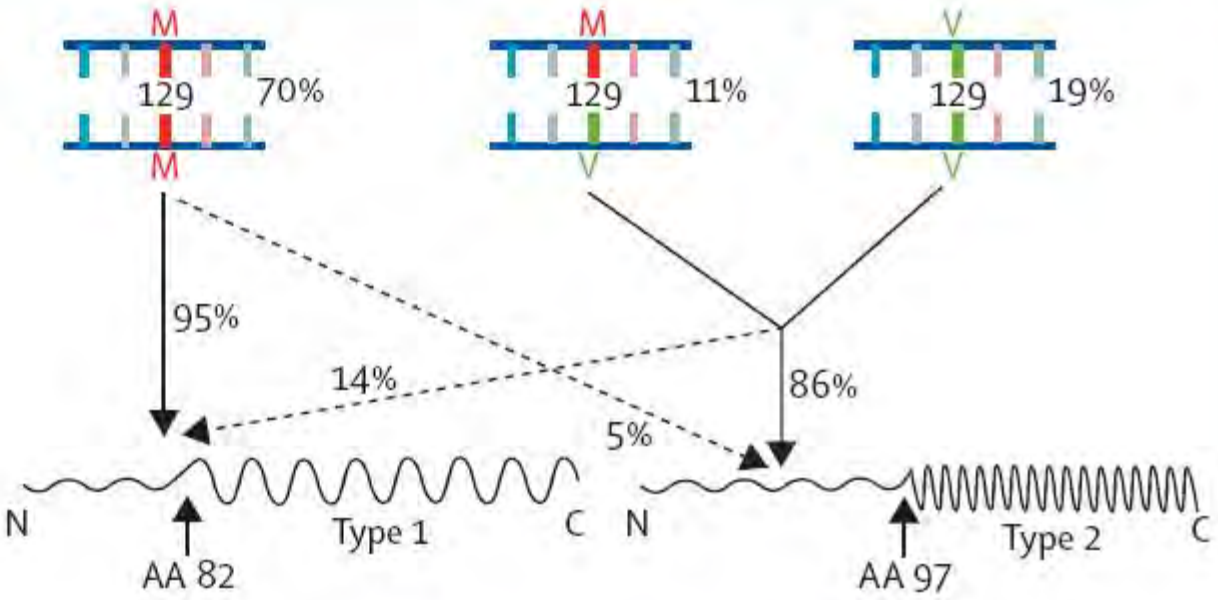

D

Immunoblot of PrP^{Sc} types 1 and 2 without and with deglycosylation by PNGase



E

sCJD and sFI phenotypes

MM(MV)1
VV1

MM2
MV2
VV2
sFI

Parchi P, Giese A, Capellari S, et al. Classification of sporadic Creutzfeldt-Jakob disease based on molecular and phenotypic analysis of 300 subjects. Ann Neurol. 1999; 46: 224-33.

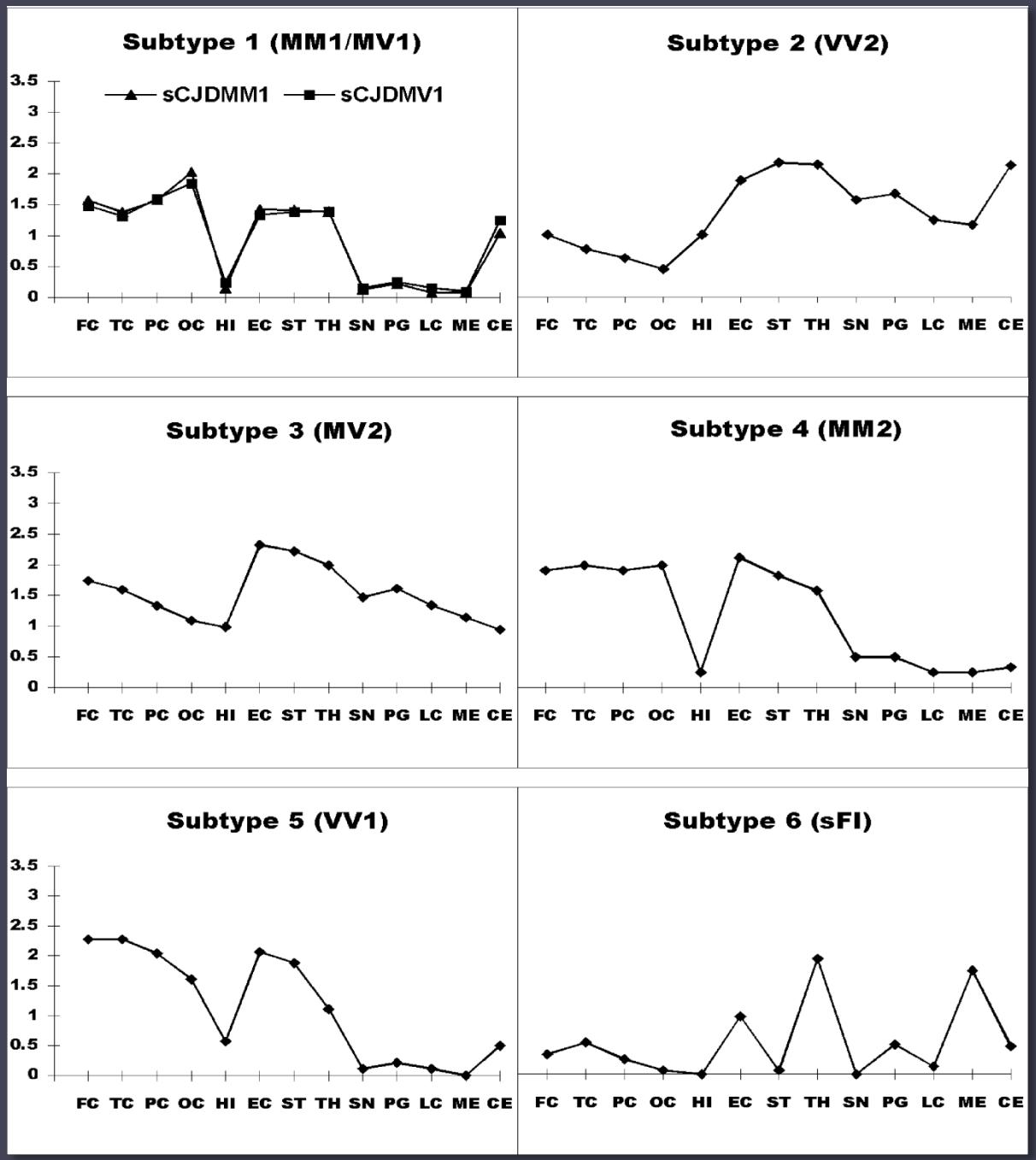

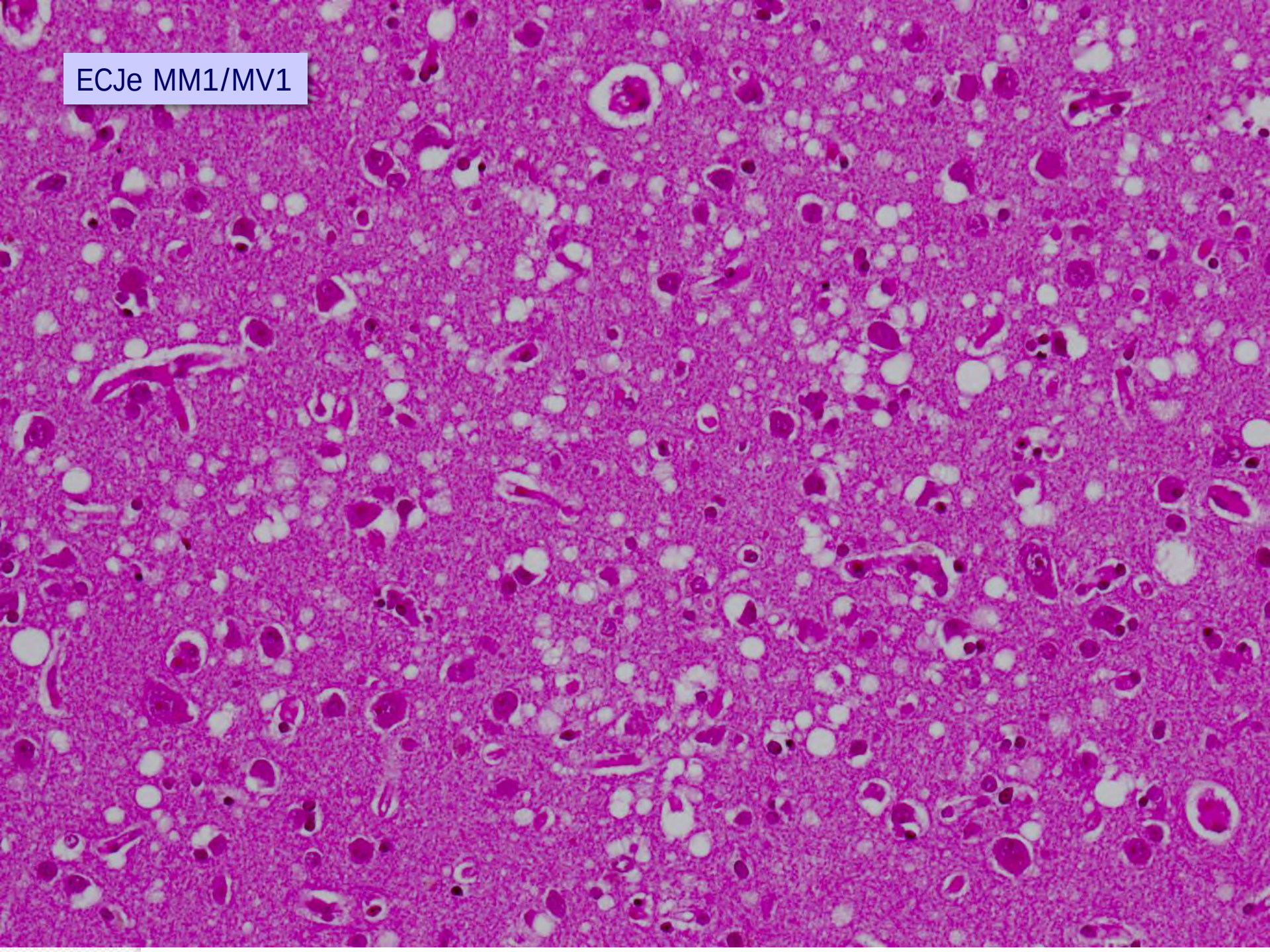
ECJe MM1/MV1

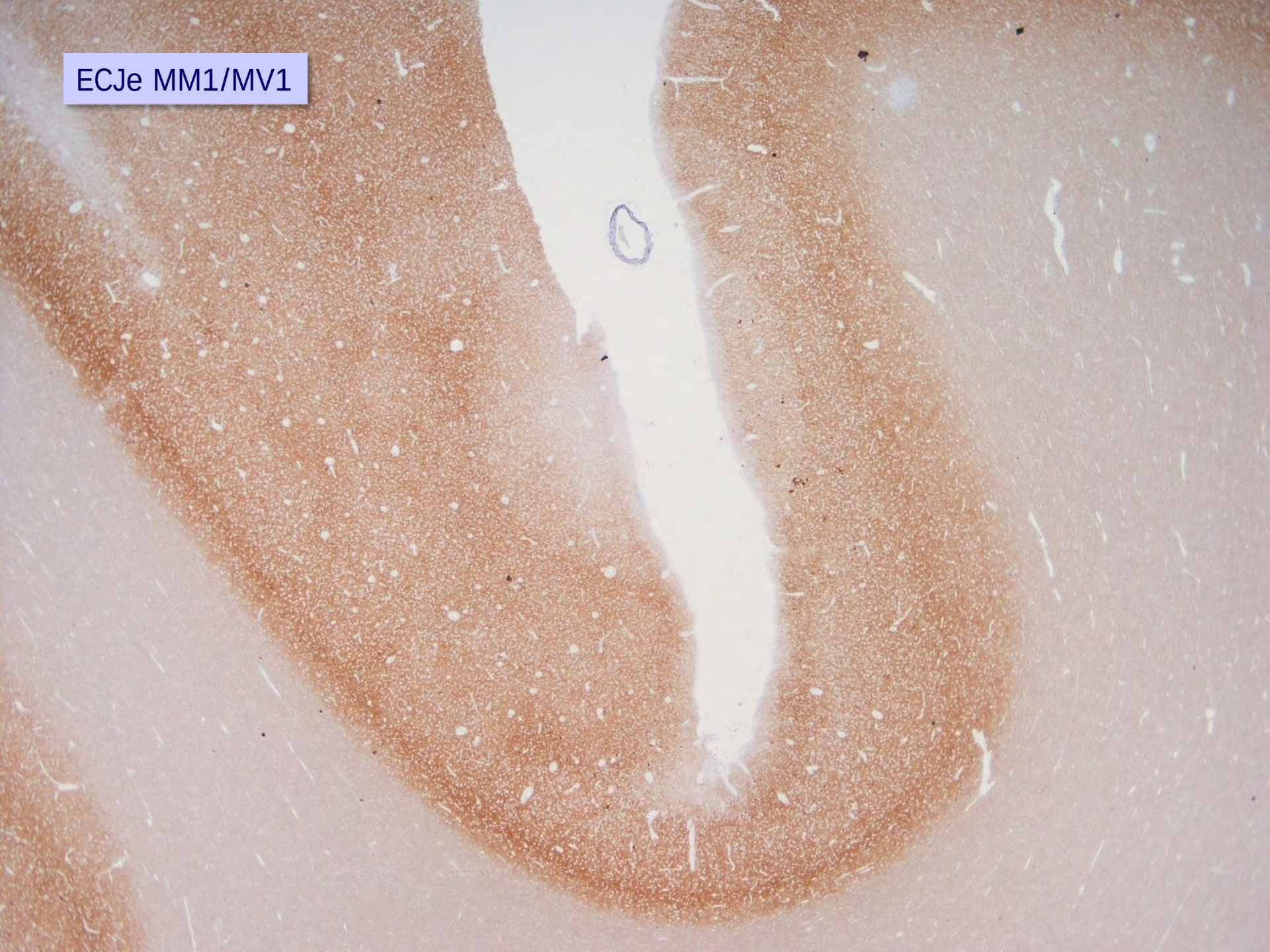
ECJe MM1/MV1

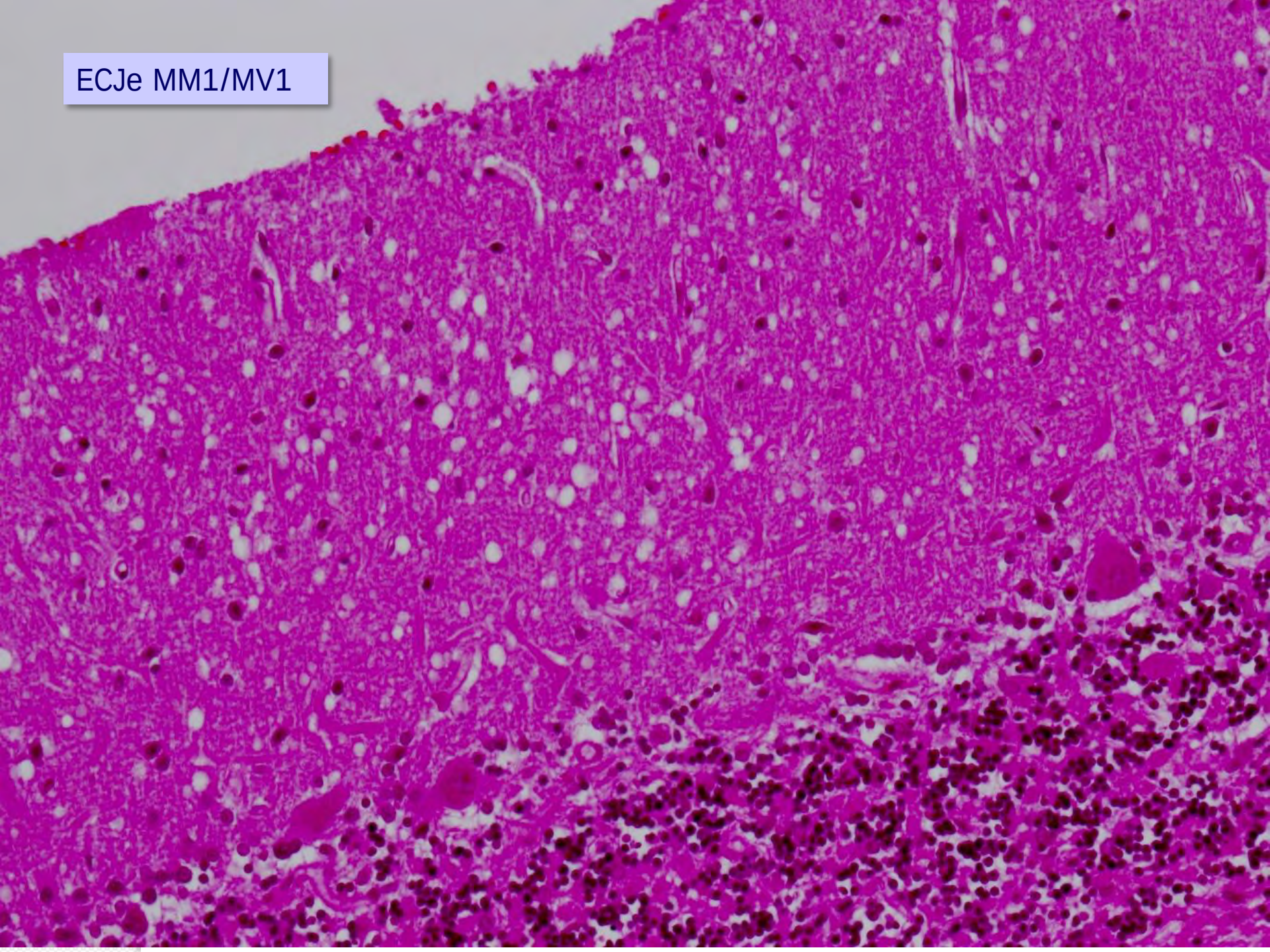
ECJe MM1/MV1

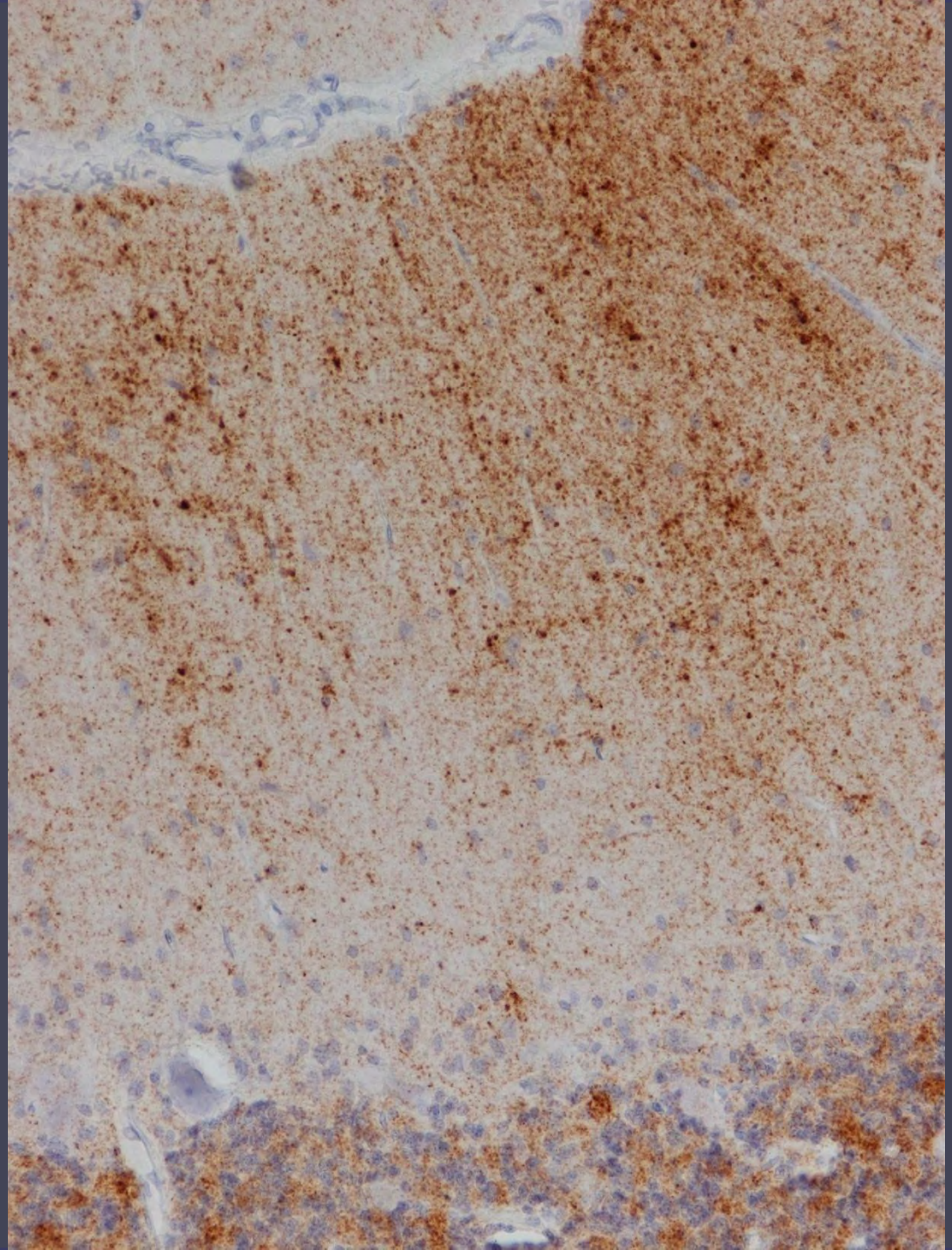

ECJe MM1/MV1

Astrocitosis GFAP

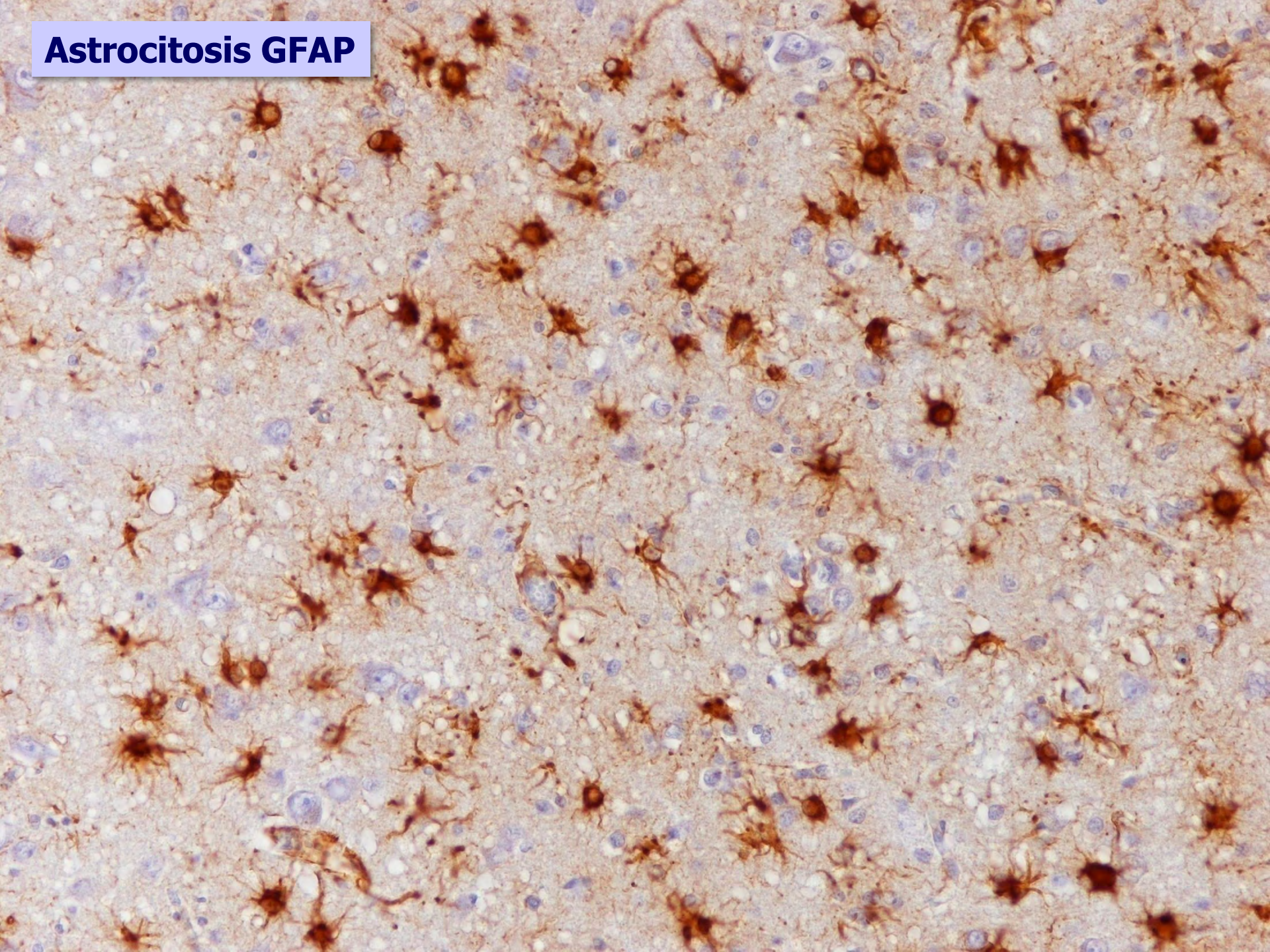

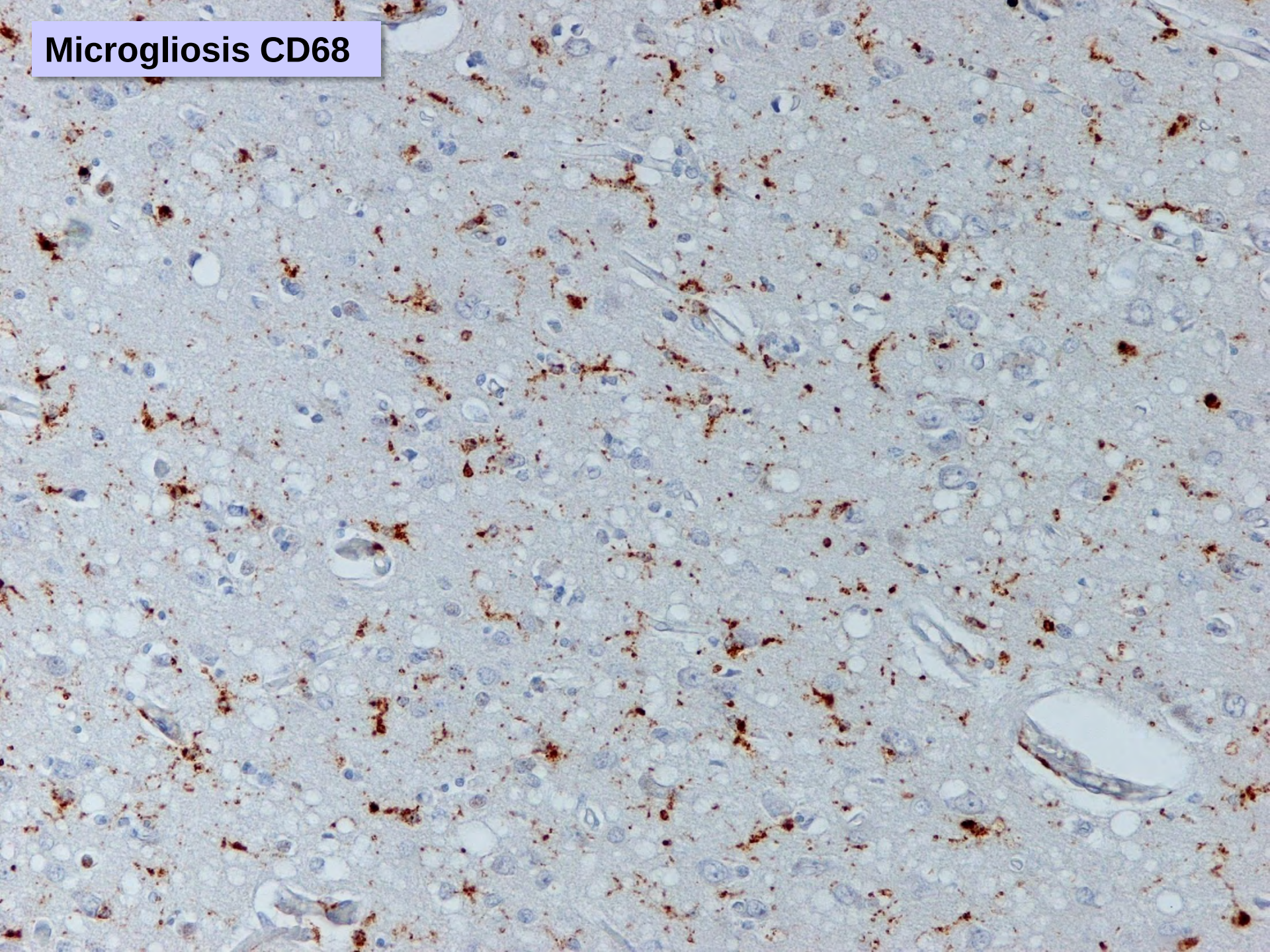
Microgliosis CD68

sCJD VV2

ECJe MV2

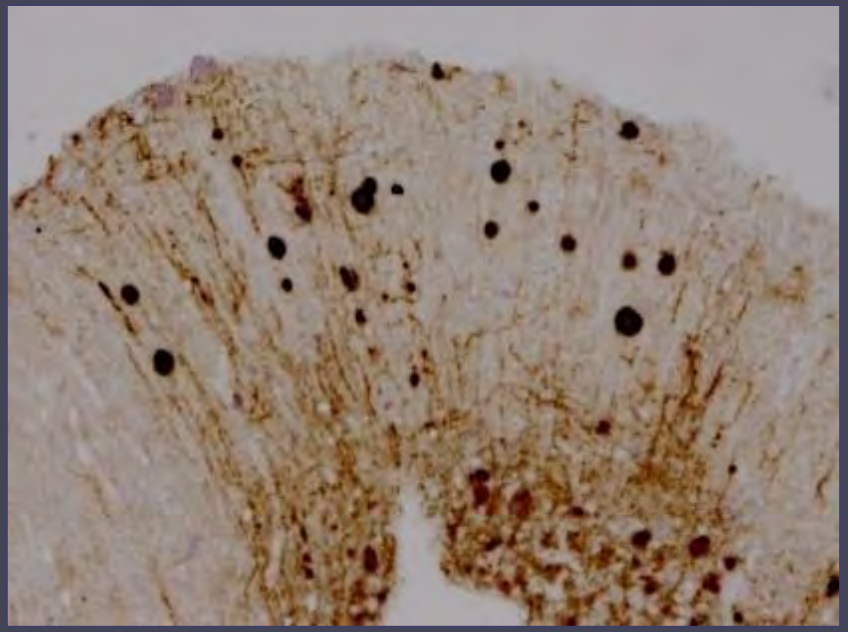

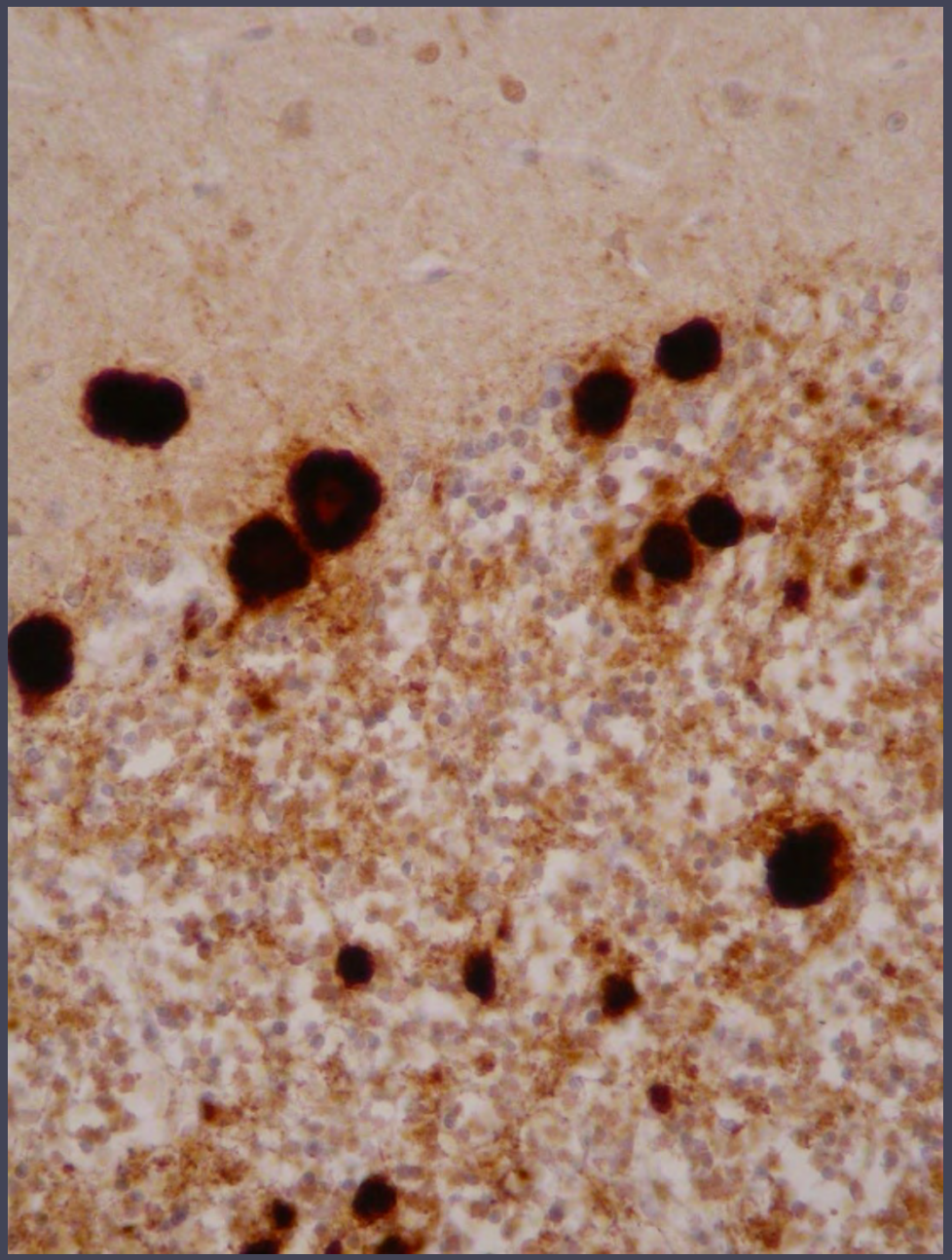

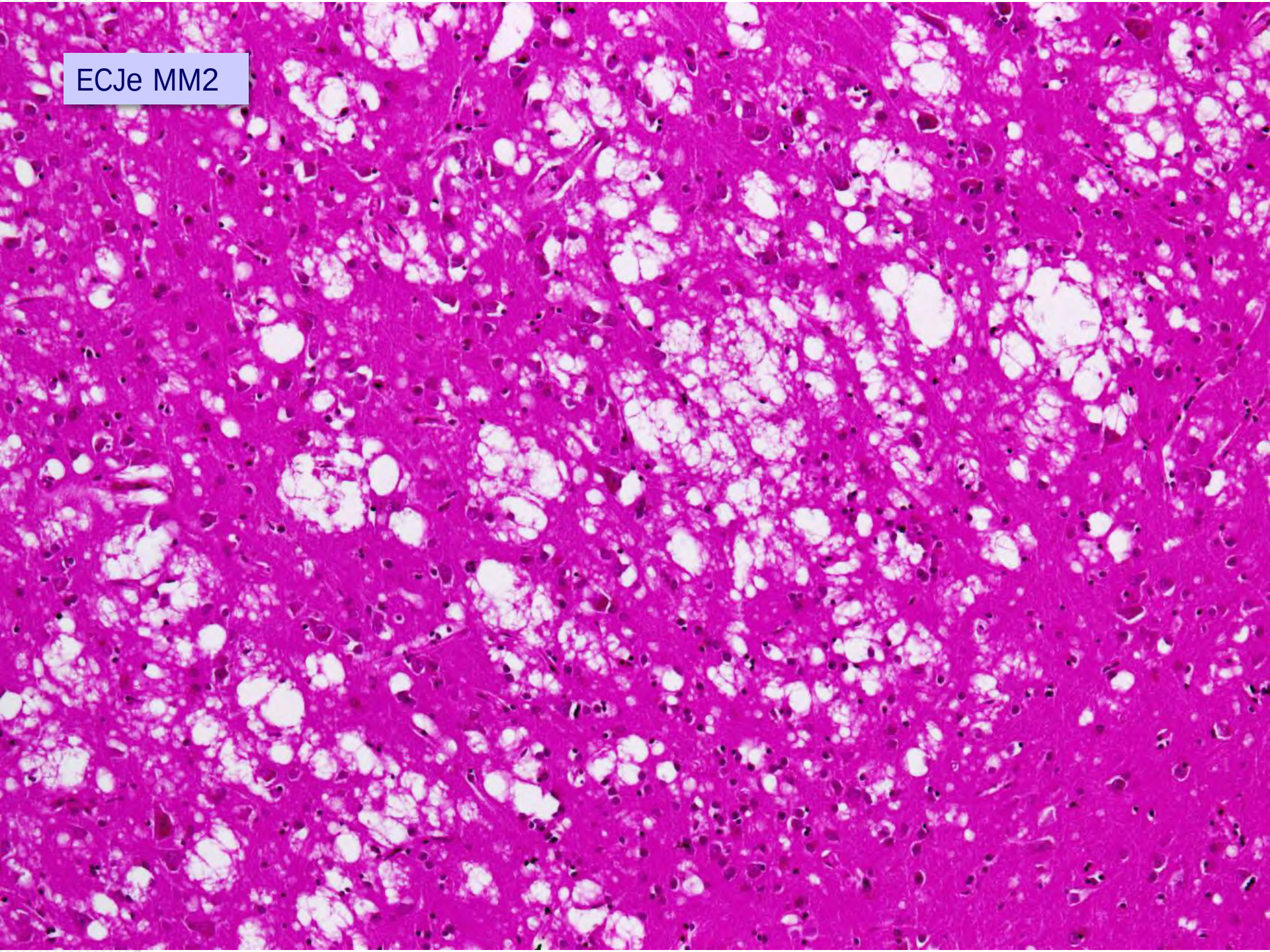
ECJe MM2

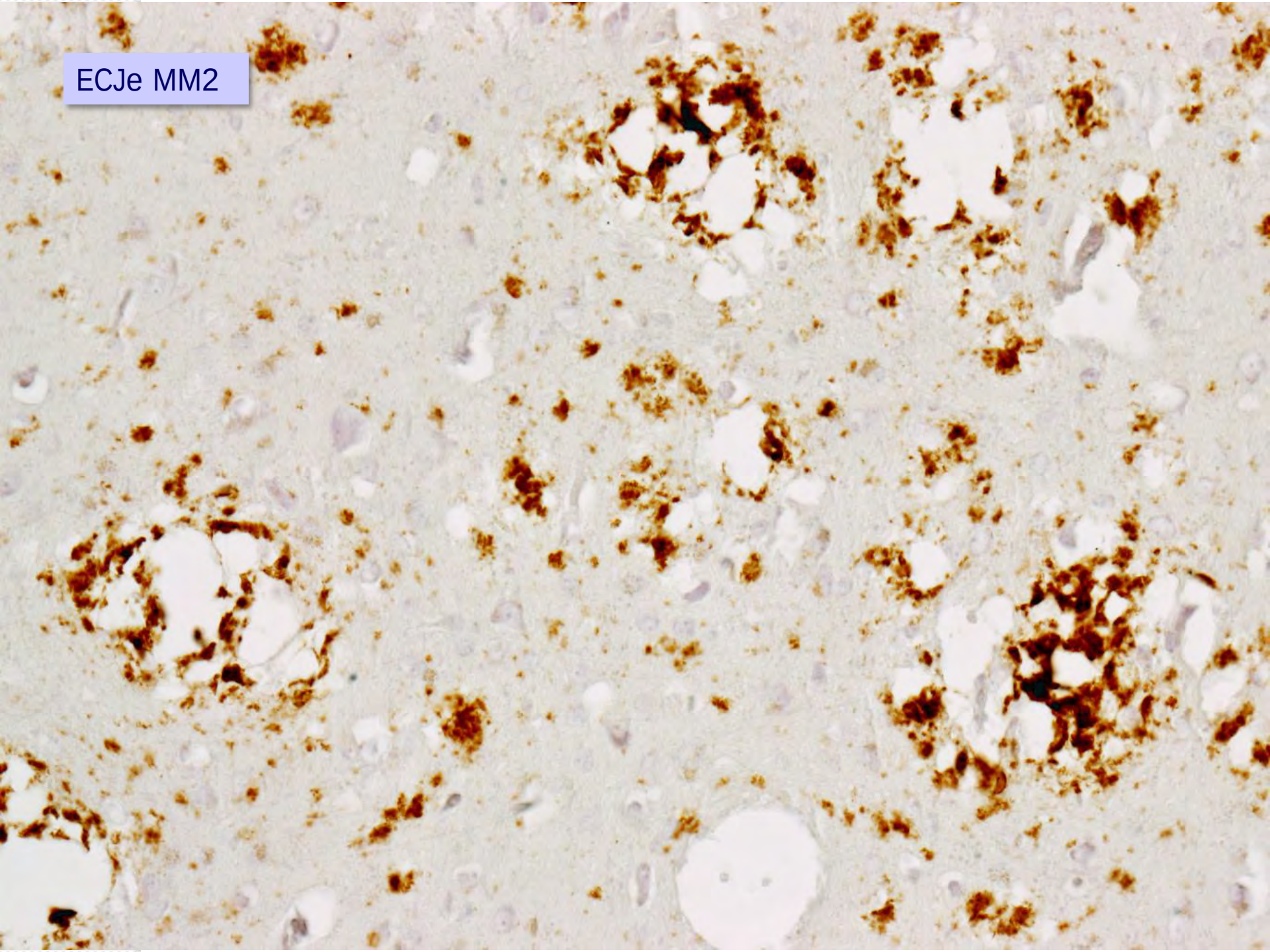
ECJe MM2

ECJe VV1

Varón de 27 años, demencia rápidamente progresiva, 6 años de evolución, últimos dos años en coma vigil.

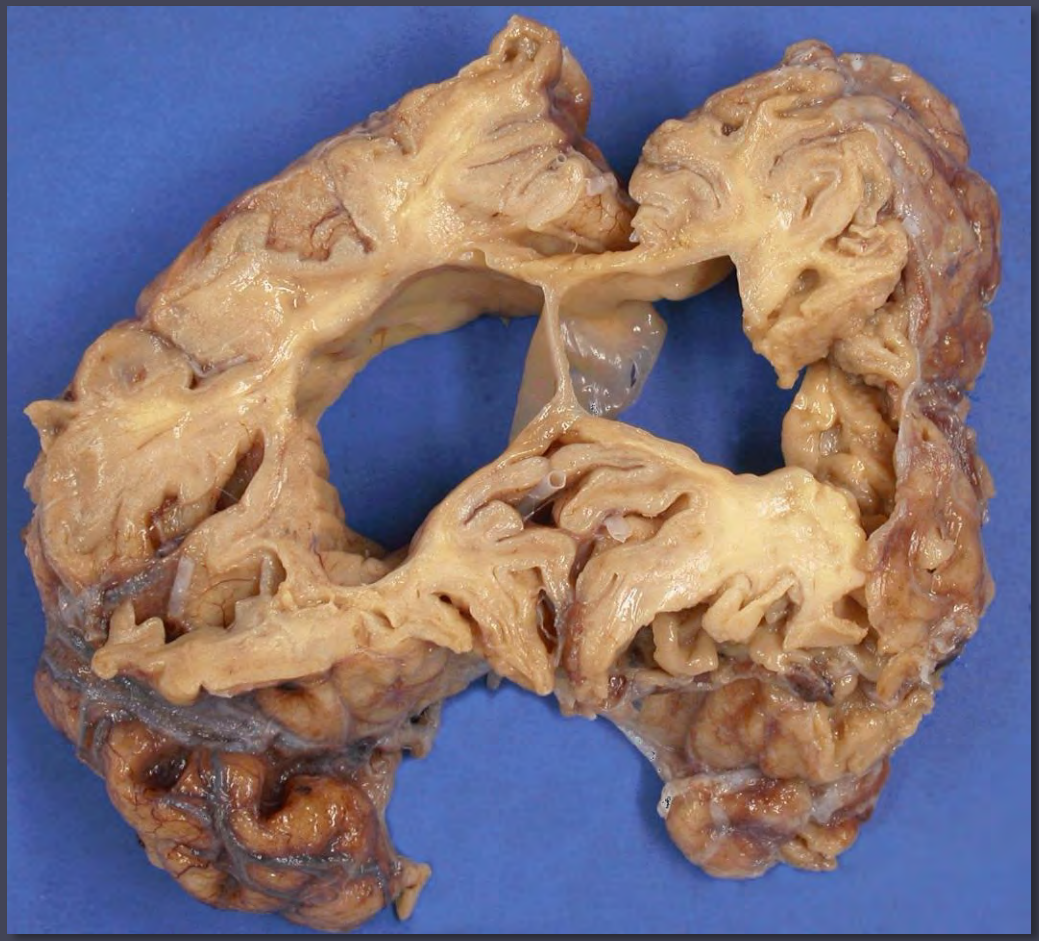

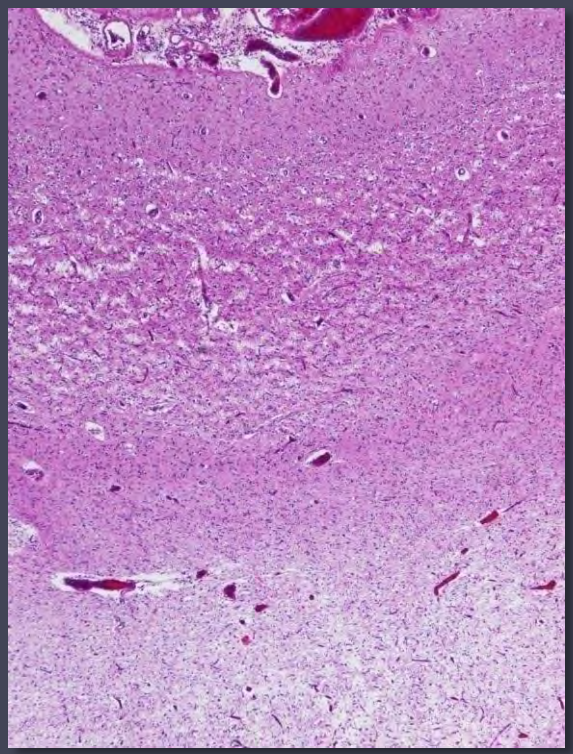

E. de Creutzfeldt-Jakob de tipo esporádico.

Codón 129: Met/Met

Tipo 1 de PrP^{Sc} en cerebelo

Córtex frontal

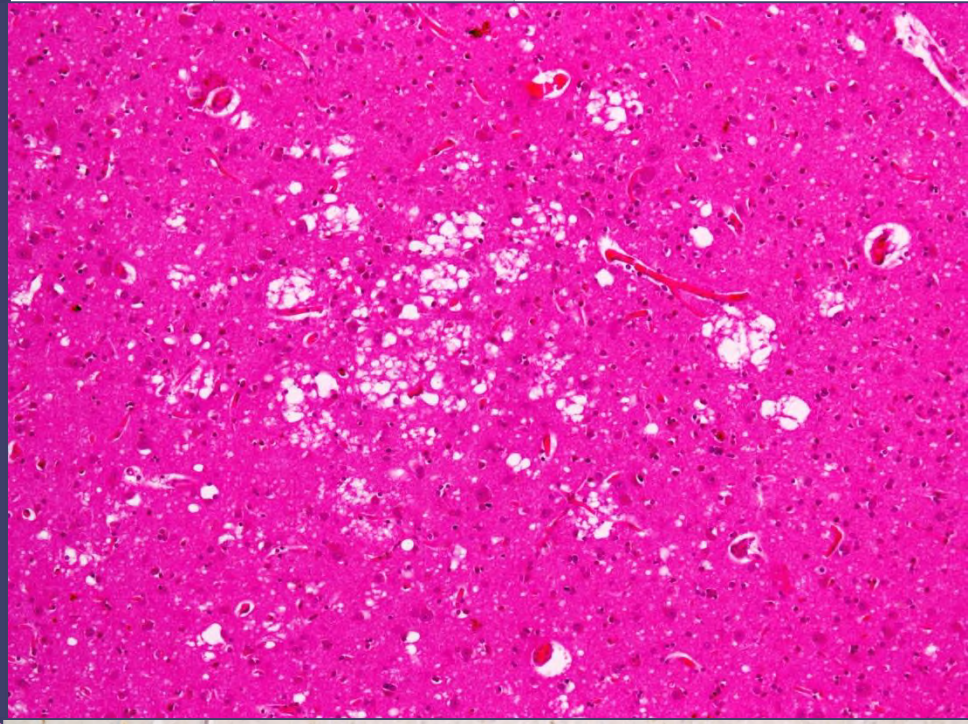

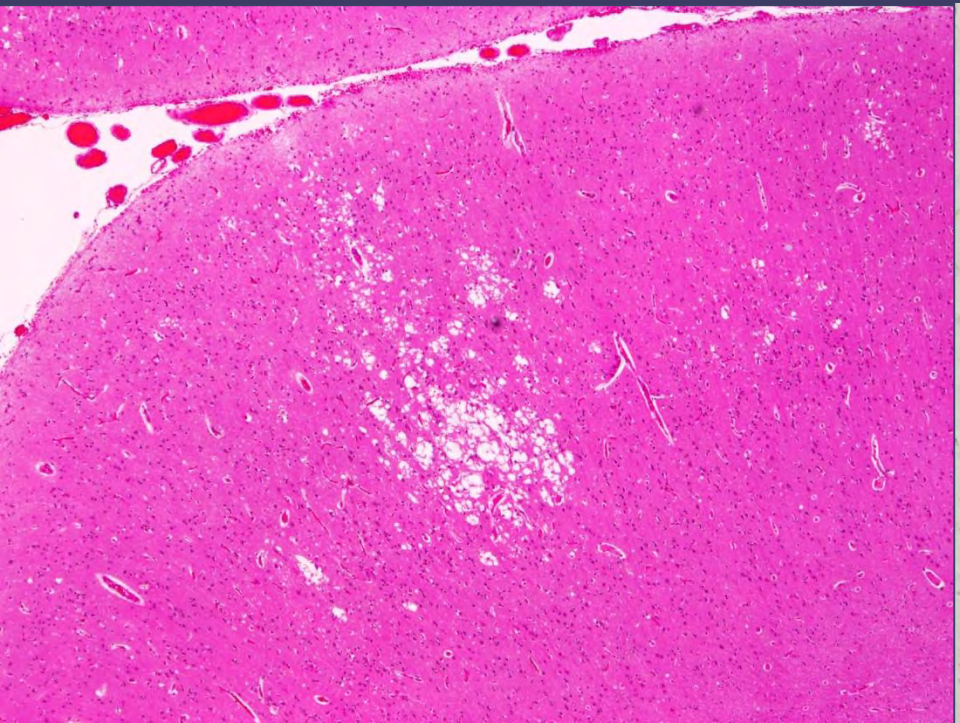

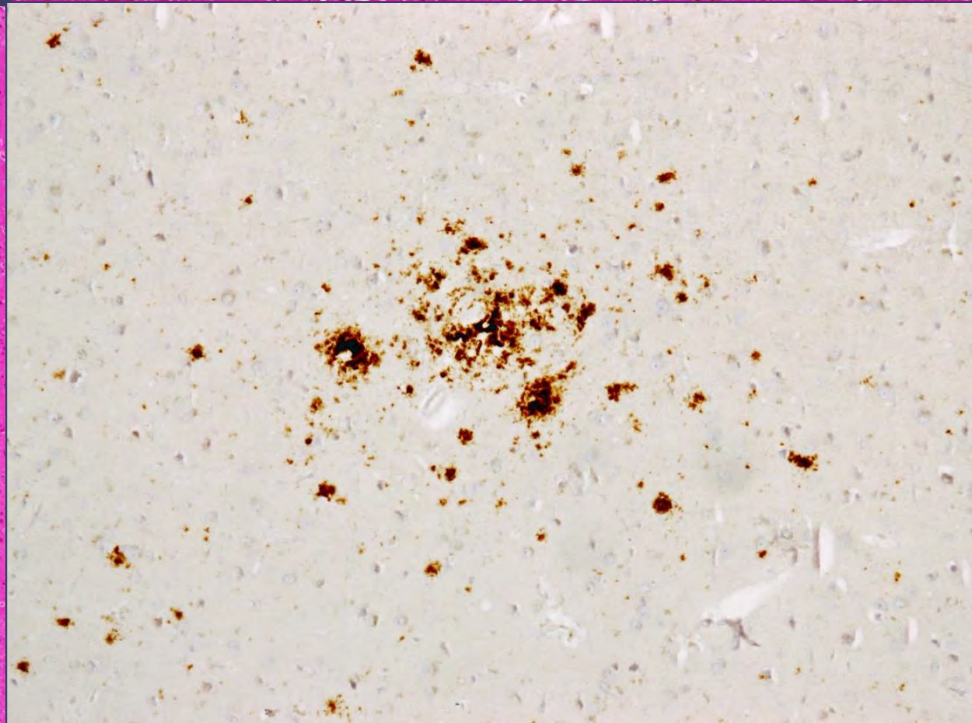

Acta Neuropathol (2009) 118:659–671
DOI 10.1007/s00401-009-0585-1

ORIGINAL PAPER

Incidence and spectrum of sporadic Creutzfeldt–Jakob disease variants with mixed phenotype and co-occurrence of PrP^{Sc} types: an updated classification

Piero Parchi · Rosaria Strammiello · Silvio Notari · Armin Giese · Jan P. M. Langeveld · Anna Ladogana · Inga Zerr · Federico Roncaroli · Patrich Cras · Bernardino Ghetti · Maurizio Pocchiari · Hans Kretzschmar · Sabina Capellari

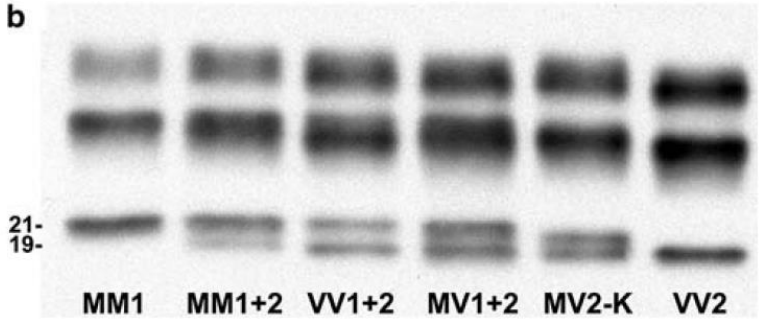

Table 6 Nomenclature and classification of sCJD subtypes

Nomenclature[a]	%[b]	Distinctive histopathologic features
Pure subtypes		
MM/MV 1; VV2; MV 2K; MM/MV 2C; MM 2T; VV1;	65	Previously established [30] (for a summary see Table 8 in [30])
Mixed subtypes		
MM/MV 1+2C	26	As in MM/MV 1 but with clusters of large vacuoles associated to perivacuolar and coarse PrP deposition mainly in cerebral cortex or thalamus
MM/MV 2C+1	2	As in MM/MV 2C but with synaptic-type PrP staining in the molecular layer of the cerebellum
VV 2+1	3	Virtually indistinguishable from VV2
MV 2K+1	1	Virtually indistinguishable from MV 2K
MV 2 K+C	3	As in MV 2K but with clusters of large vacuoles associated to perivacuolar and coarse PrP deposition mainly in cerebral cortex
MM 2 T+C	<1	As in MV 2T but with clusters of large vacuoles associated to perivacuolar and coarse PrP deposition mainly in cerebral cortex

[a] It is largely based on codon 129 *PRNP* genotype, which can be either methionine (M) or valine (V) and the PrP^{Sc} type (1 or 2 according to Parchi et al. [28, 29]). Since both MM 2 and MV 2 groups are associated to 2 distinct phenotypes, these are further defined with a third parameter (*capital letter*) referring to distinctive histopathological features: *K* kuru type amyloid plaques, *C* predominant cortical pathology with confluent vacuoles and perivacuolar PrP staining, *T* prominent thalamic pathology with atrophy

[b] Percentage of total consecutive sCJD cases ($n = 200$) investigated

	Sporadic familial insomnia	Variably protease-sensitive prionopathy			
	MM2 (n=31)	VV (n=21)	MV (n=9)	MM (n=3)*	All genotypes (n=33)
Age at onset (years)	46 (13, 24–74)	67 (9, 48–77)	74 (5, 65–81)	78 (12, 64–87)	70 (9, 48–87)
Duration (months)†	24 (13, 10–73)	18 (15, 10–60)	34 (25, 7–73)	41 (9, 10–73)	24 (10, 7–73)
Presentation					
Cognitive decline	13/31 (42%)	12/21 (57%)	6/9 (67%)	0/3	18/33 (55%)
Ataxia	13/31 (42%)	0/21	0/9	1/3 (33%)	1/33 (3%)
Insomnia	9/31 (29%)	..	..	..	..
Psychiatric	8/31 (26%)	14/21 (67%)	6/9 (67%)	1/3 (33%)	21/33 (64%)
Visual signs	7/31 (23%)	..	..	..	..
Dysautonomia	1/31 (3%)	..	..	..	..
Aphasia	..	11/21 (52%)	1/9 (11%)	1/3 (33%)	13/33 (39%)
Parkinsonism	..	2/21 (10%)	0/9	1/3 (33%)	3/33 (9%)
Advanced stage					
Cognitive decline	31/31 (100%)	21/21 (100%)	9/9 (100%)	3/3 (100%)	33/33 (100%)
Ataxia	22/31 (71%)	10/21 (48%)	2/9 (22%)	1/3 (33%)	13/33 (39%)
Insomnia	14/31 (45%)	..	..	..	..
Psychiatric	14/31 (45%)	18/21 (86%)	6/9 (67%)	1/3 (33%)	25/33 (76%)
Visual signs	13/31 (42%)	..	..	..	..
Pyramidal signs	9/31 (29%)	..	..	..	..
Dysautonomia	6/31 (19%)	..	..	..	..
Aphasia	..	12/21 (57%)	1/9 (11%)	2/3 (67%)	15/33 (45%)
Parkinsonism	..	8/21 (38%)	3/9 (33%)	3/3 (100%)	14/33 (42%)
Myoclonus	32% (30)	12% (16)	22% (9)‡	100% (2)‡	22% (27)‡
EEG sensitivity§	7% (27)	0% (16)	25% (4)	50% (2)	9% (22)
CSF sensitivity§¶	13% (15)	37% (8)	0% (4)	50% (2)	21% (14)
MRI sensitivity§‖	8% (26)**	5% (20)	0% (9)	0% (2)	3% (31)

Data are median (SD, range), n/N (%), or % (N). M=methionine. V=valine. PrP^{Sc}= prototypic scrapie prion protein. EEG=electroencephalogram. *An additional proven case was asymptomatic at death. †Duration is time from first symptom to death. ‡All in the late phase of disease. §95% CIs not available; data should be interpreted with reference to sample size. ¶14-3-3 and tau tests combined. ‖As determined by the presence of alterations typical of Creutzfeldt-Jakob disease. **Single-photon emission CT or PET scans were positive in all eight patients who underwent this examination.

Table 3: **Clinical features of sporadic familial insomnia and subtypes of variably protease sensitive prionopathy, by 129 genotype-PrP^{Sc} type**

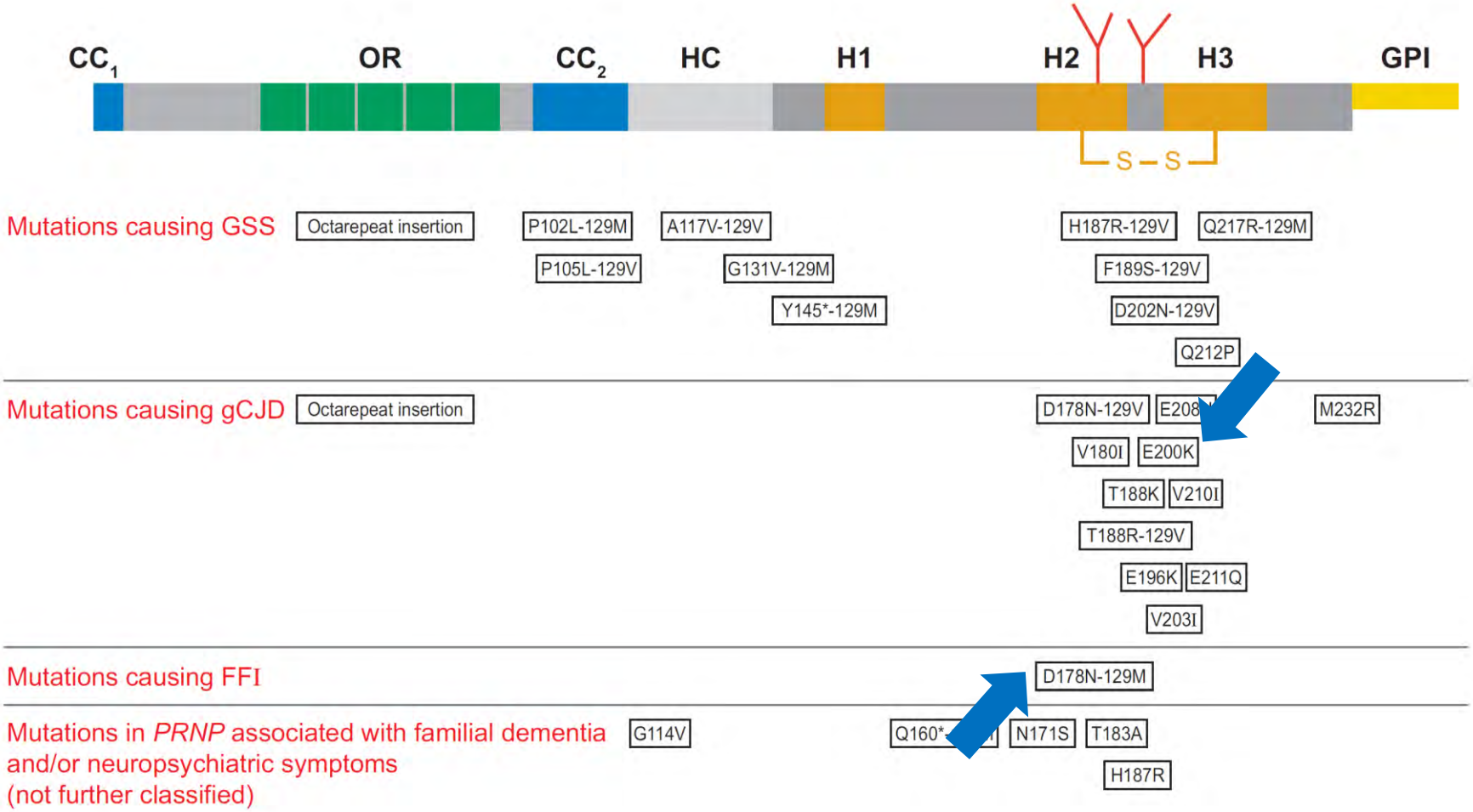

Figure 2

The human PrP^C protein and its mutants. The mature human PrP^C protein contains 208 amino acid residues. It features two positively charged amino acid clusters denoted CC_1 and CC_2 (*blue boxes*), an octapeptide repeat region (OR) (*green boxes*), a hydrophobic core (HC) (*gray box*), three α-helixes (H1-H3) (*red boxes*), one disulphide bond (S–S) between cysteine residues 179 and 214, and two potential sites for N-linked glycosylation (*red forks*) at residues 181 and 197. A glycosylphosphatidylinositol anchor (GPI) (*yellow box*) is attached to the C-terminus of PrP. This figure indicates in black framed boxes point mutations and insertions found in the human *PRNP* gene in patients with prion disease. The associated polymorphisms of codon 129 (methionine M or valine V) are indicated. Amino acids are given in single-letter code. The asterisk indicates a stop codon; therefore, this mutation results in a truncated protein.

E. de Gerstmann – Sträussler - Scheinker

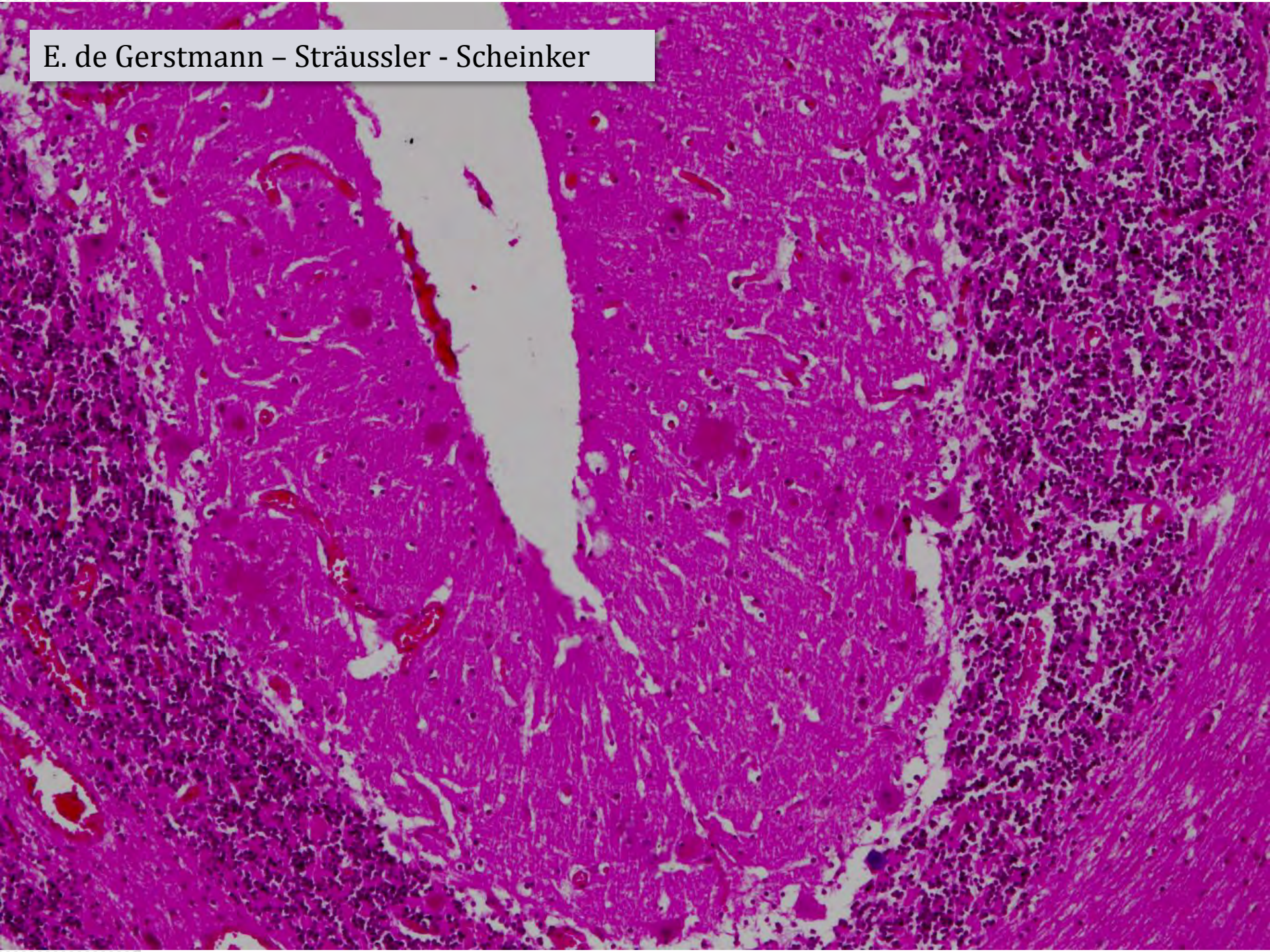

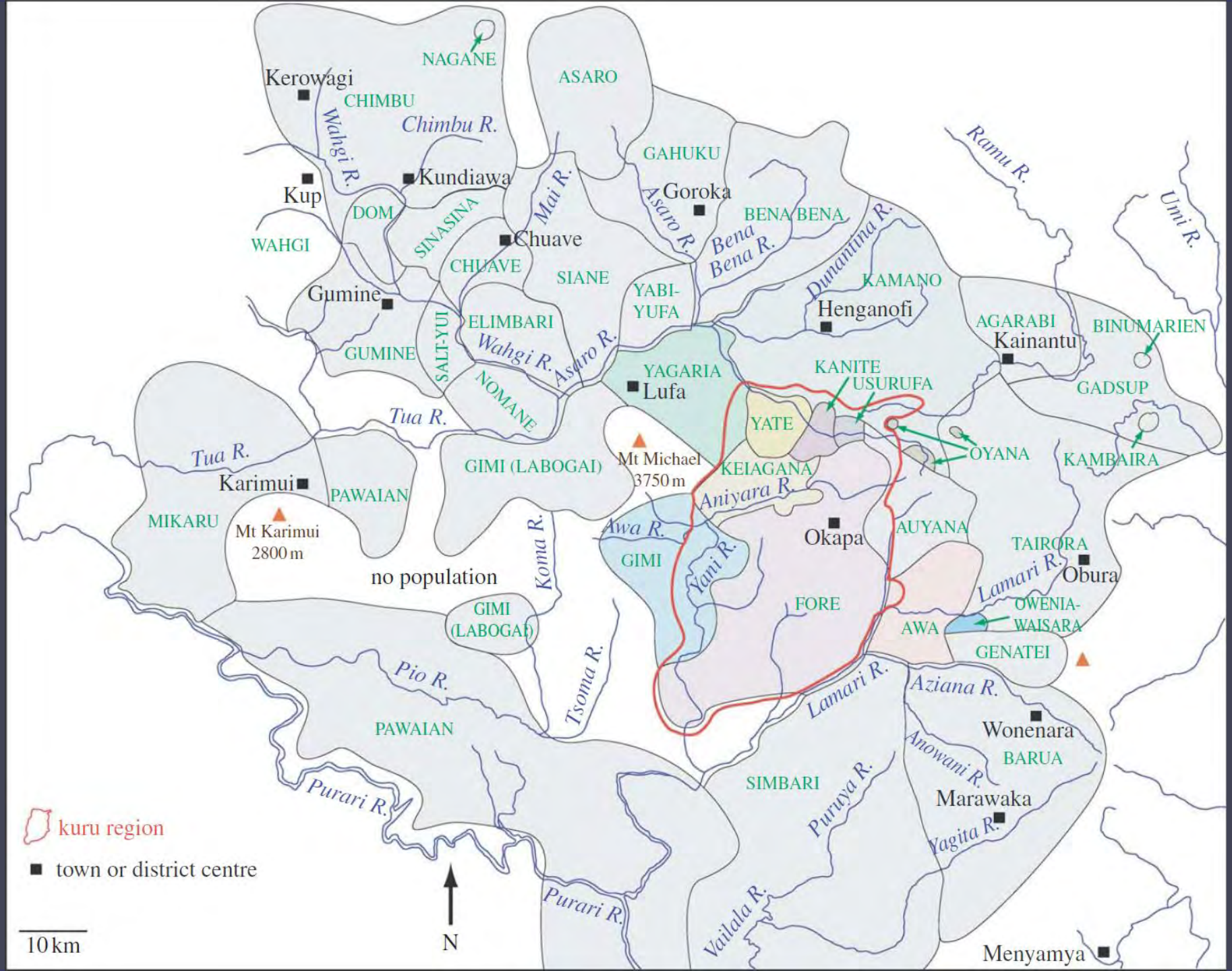
NAGANE
Kerowagi
CHIMBU
Chimbu R.
Wahgi R.
ASARO
GAHUKU
Kundiawa
Kup
DOM
SINASINA
Mai R.
Asaro R.
Goroka
BENA BENA
Bena Bena R.
Ramu R.
Umi R.
WAHGI
Chuave
CHUAVE
SIANE
YABI-YUFA
Dunantina R.
KAMANO
Gumine
Henganofi
ELIMBARI
SALT-YUI
Wahgi R.
Asaro R.
AGARABI
Kainantu
BINUMARIEN
GUMINE
YAGARIA
Lufa
KANITE
USURUFA
GADSUP
NOMANE
Tua R.
YATE
OYANA
KAMBAIRA
Tua R.
GIMI (LABOGAI)
Mt Michael
3750 m
KEIAGANA
Karimui
PAWAIAN
Aniyara R.
MIKARU
Mt Karimui
2800 m
Koma R.
Awa R.
Okapa
AUYANA
TAIRORA
GIMI
Yani R.
Obura
Lamari R.
no population
FORE
OWENIA-WAISARA
GIMI (LABOGAI)
AWA
GENATEI
Pio R.
Tsoma R.
Lamari R.
Aziana R.
PAWAIAN
Wonenara
Anowani R.
BARUA
SIMBARI
Purari R.
Puruya R.
Marawaka
Yagita R.
kuru region
town or district centre
Purari R.
Vailala R.
N
10 km
Menyamya

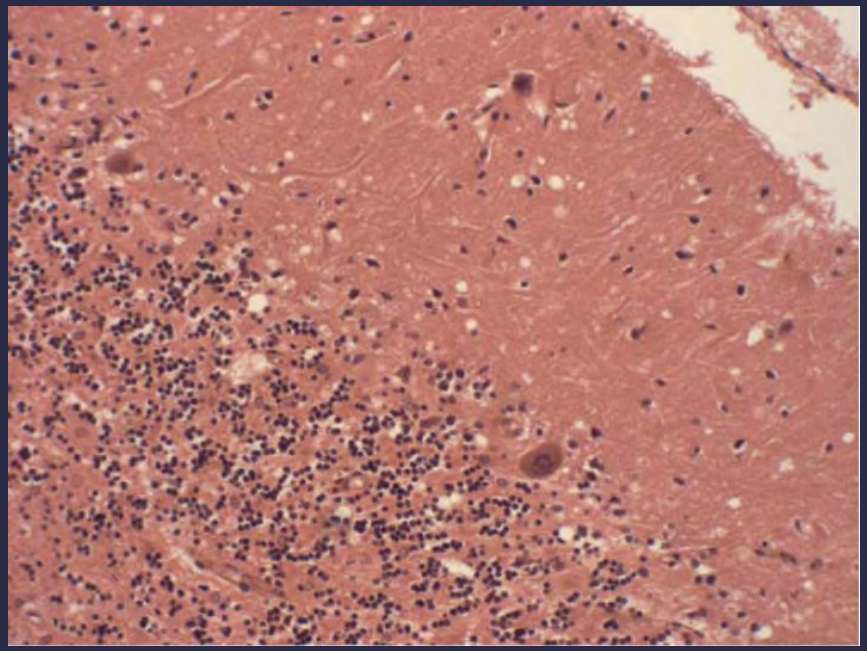

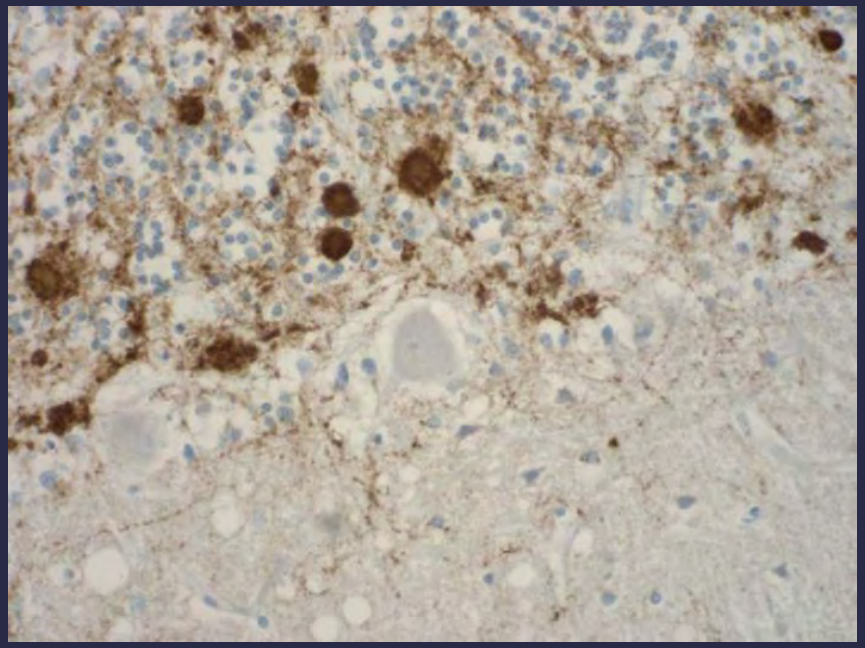

Global distribution of cases of iatrogenic Creutzfeldt-Jakob disease*

	Source of infection and no. cases						
	Surgical procedure				Medical procedure		
Country	Dura mater grafts	Surgical instruments	EEG needles	Corneal transplants†	Growth hormone‡	Gonadotropin	Packed red blood cells§
Argentina	1						
Australia	5					4	
Austria	3				1		
Brazil					2		
Canada	4						
Croatia	1						
France	13	1			119		
Germany	10			1			
Ireland					1		
Italy	9						
Japan	142						
Netherlands	5				2		
New Zealand	2				6		
South Korea	2						
Qatar					1		
South Africa	1						
Spain	14						
Switzerland	3		2				
Thailand	1						
United Kingdom	8	3			65		3
United States	4			1	29		
Total	228	4	2	2	226	4	3

Lancet 1996; 347: 921- 25

A new variant of Creutzfeldt-Jakob disease in the UK

R G Will, J W Ironside, M Zeidler, S N Cousens, K Estibeiro, A Alperovitch, S Poser, M Pocchiari, A Hofman, P G Smith

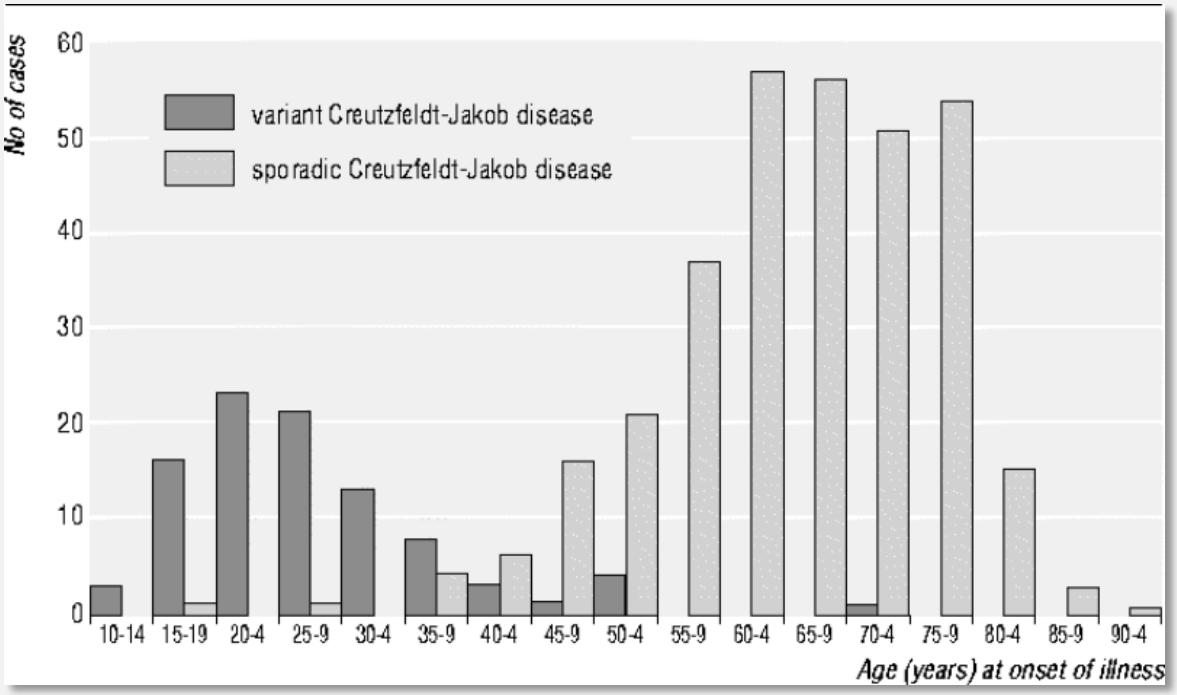

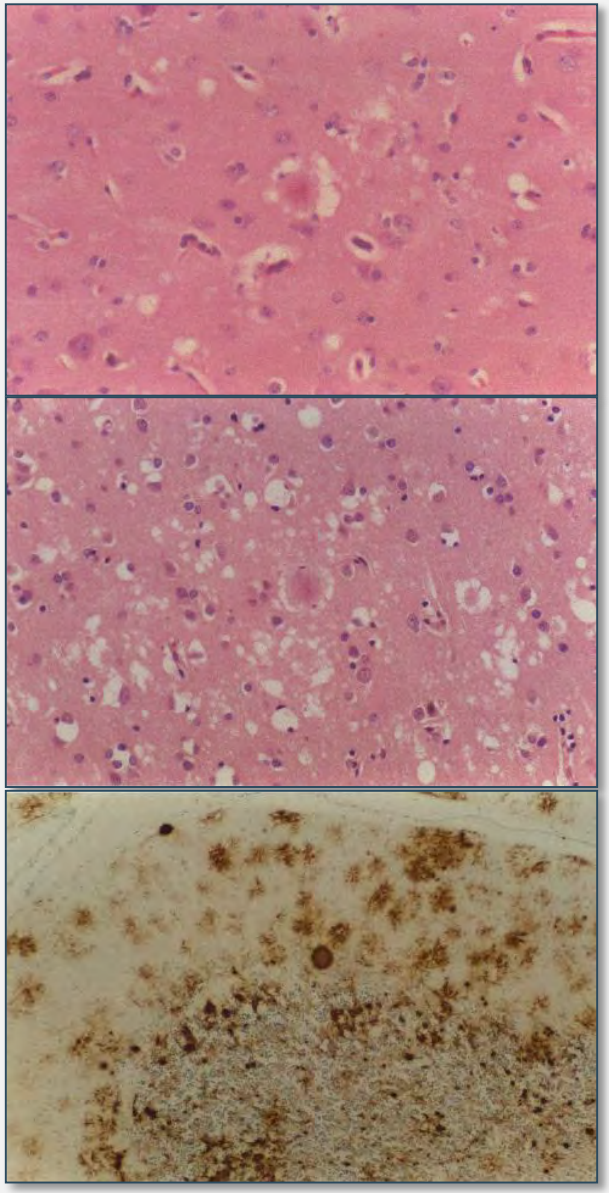

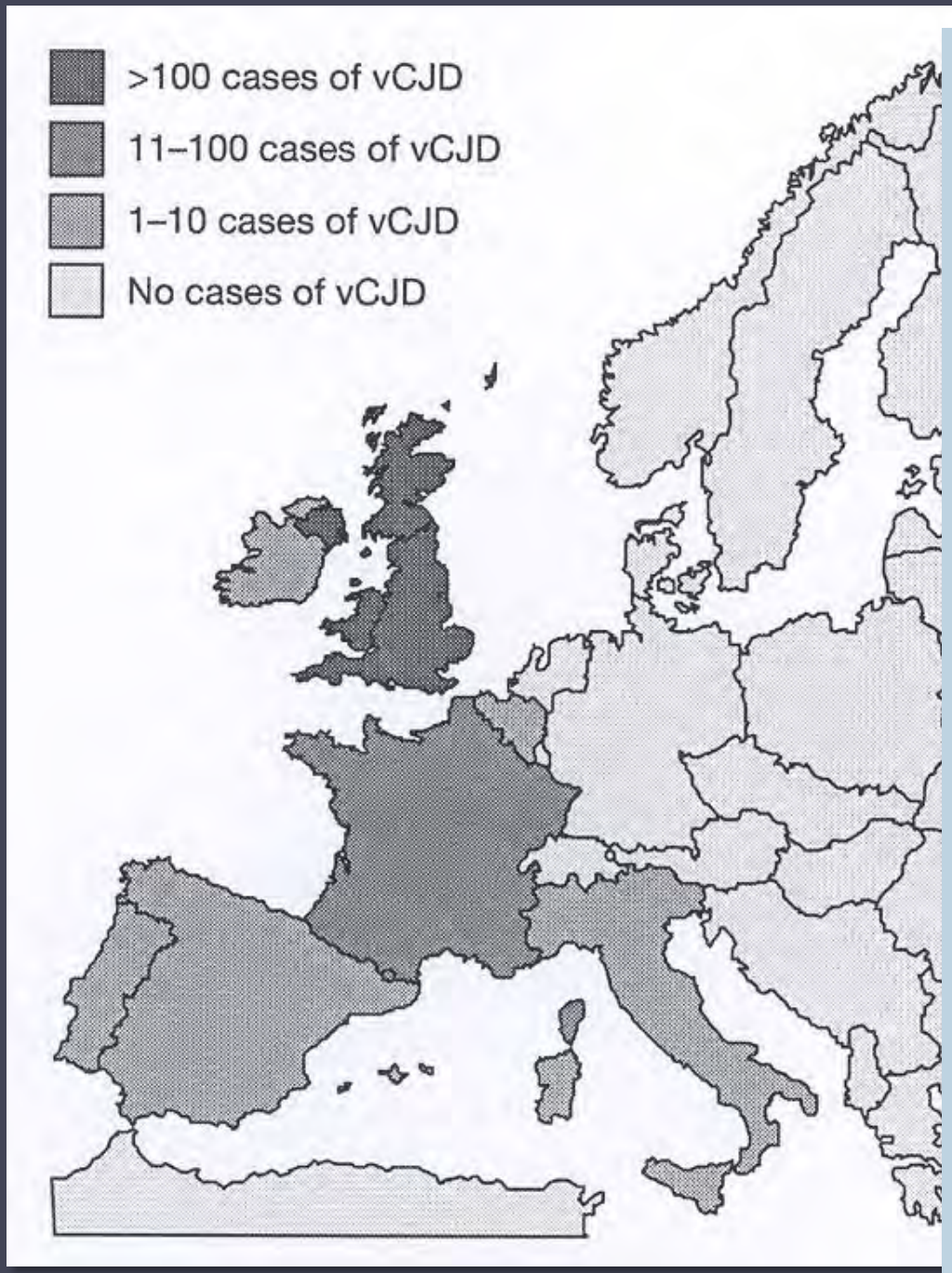

Reino Unido:	177 (0)
Francia:	27 (2)
España:	5 (0)
Irlanda:	4 (0)
Holanda:	3 (0)
Portugal:	2 (0)
Italia:	2 (0)

EE.UU.:	3* (0)
Canadá:	2 (0)
Japón:	1* (0)
Arabia Saudí:	1 (0)
Taiwan:	1 (0)

(04/11/2013)

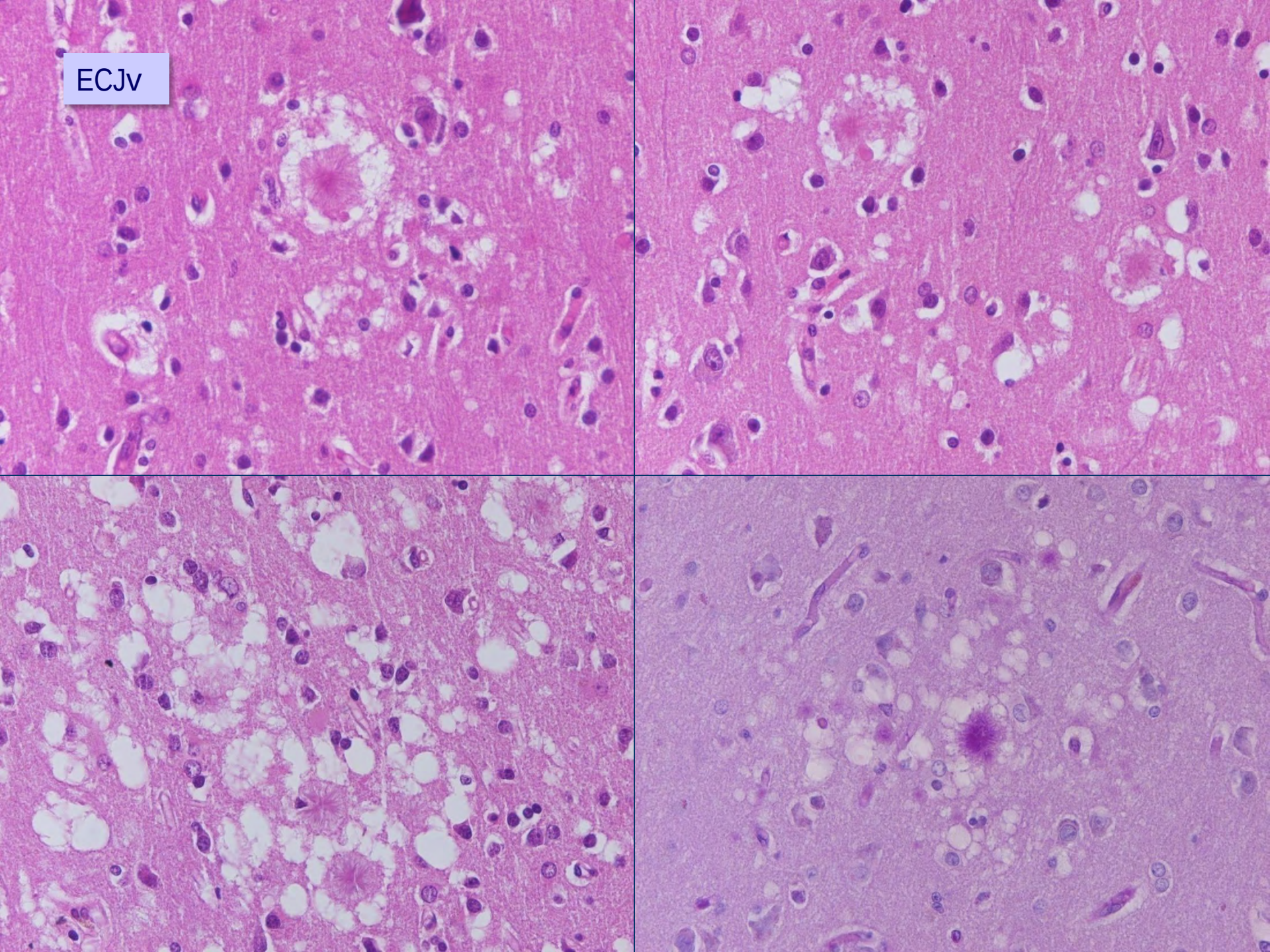
ECJv

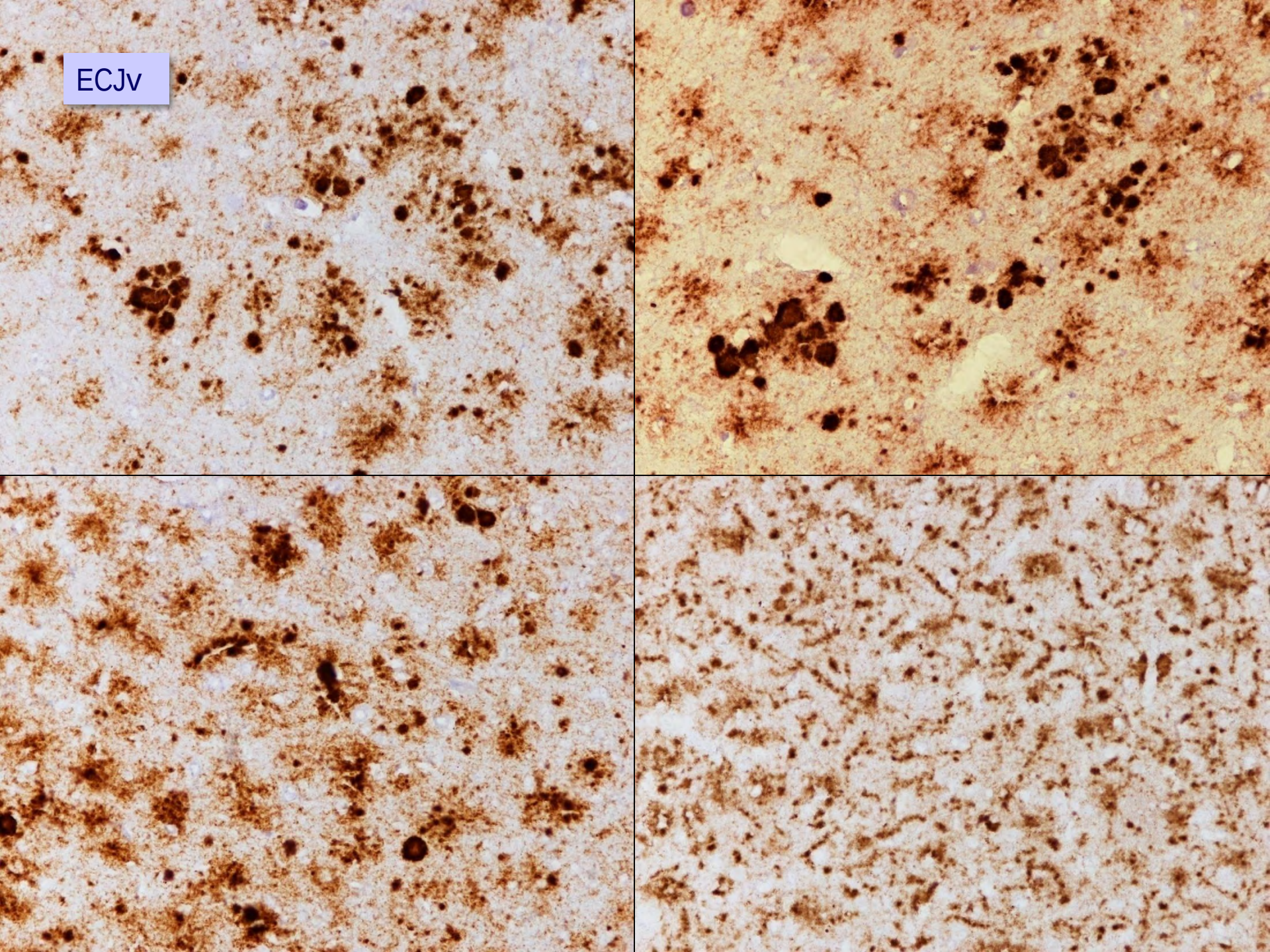
ECJv

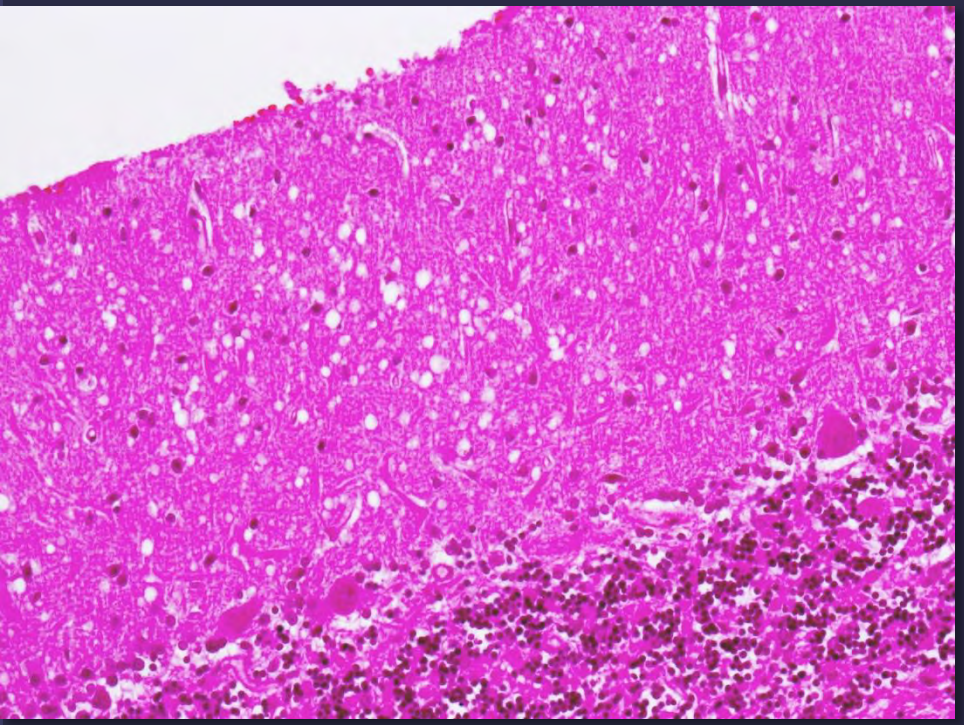

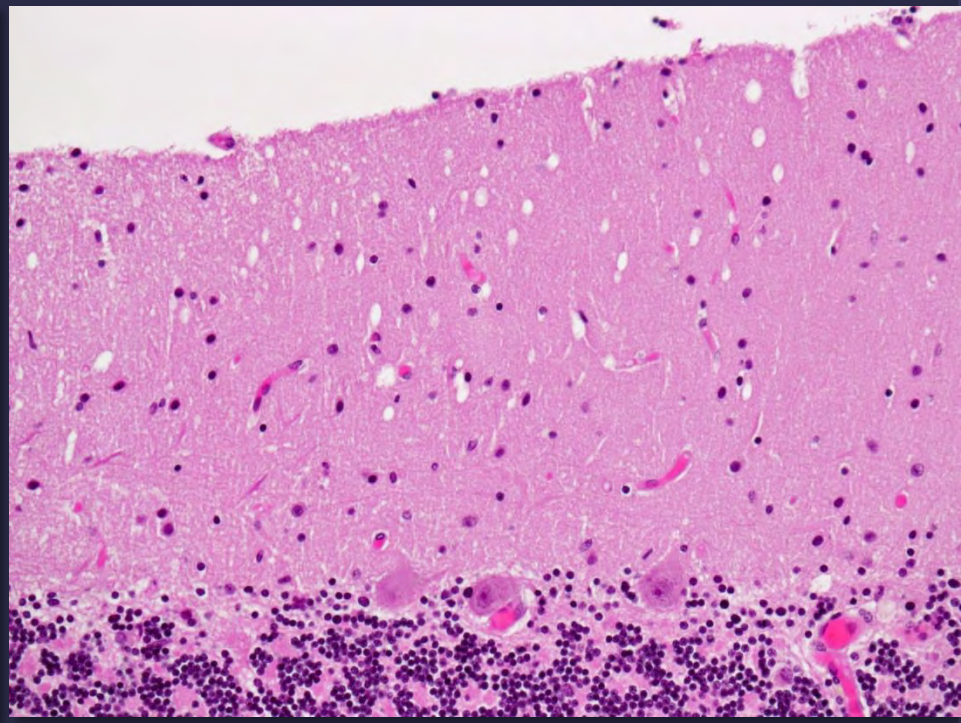

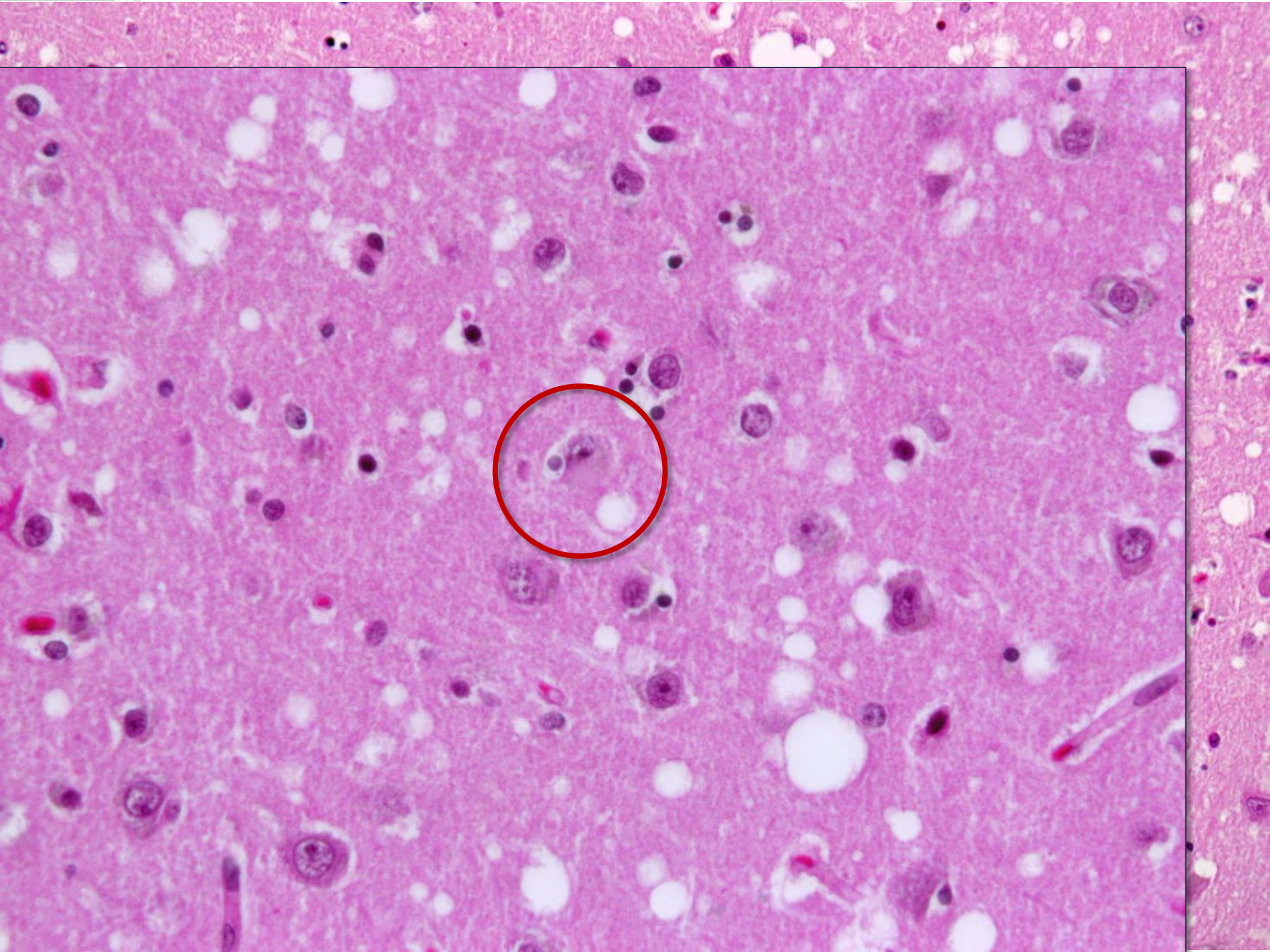

Patología de tipo Lewy

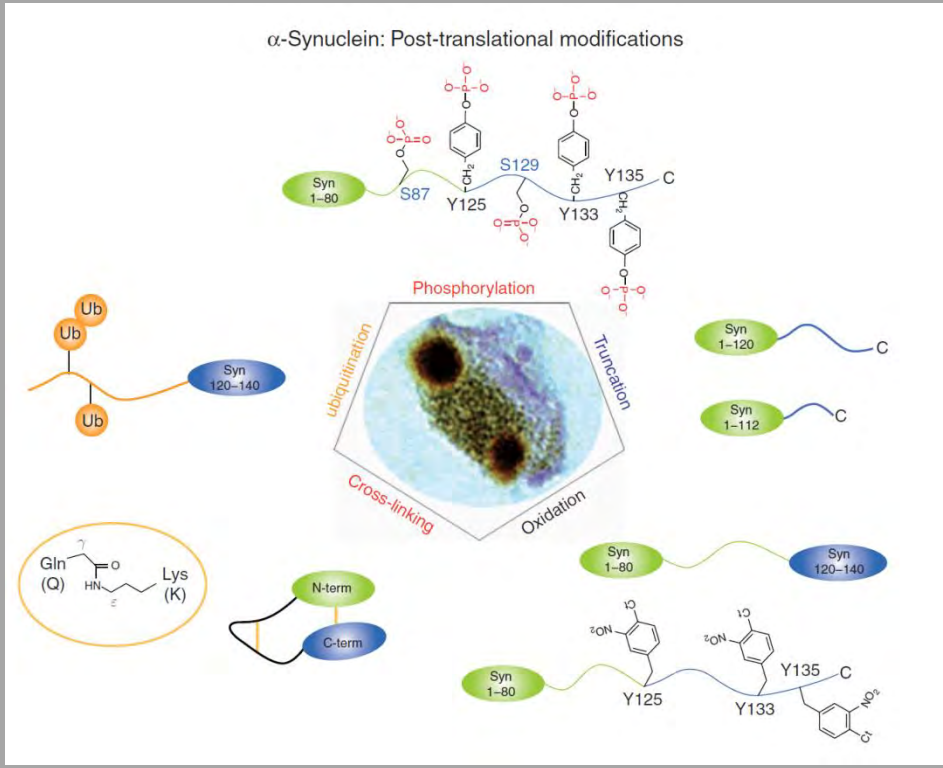

Sustancia nigra,
hematoxilina - eosina

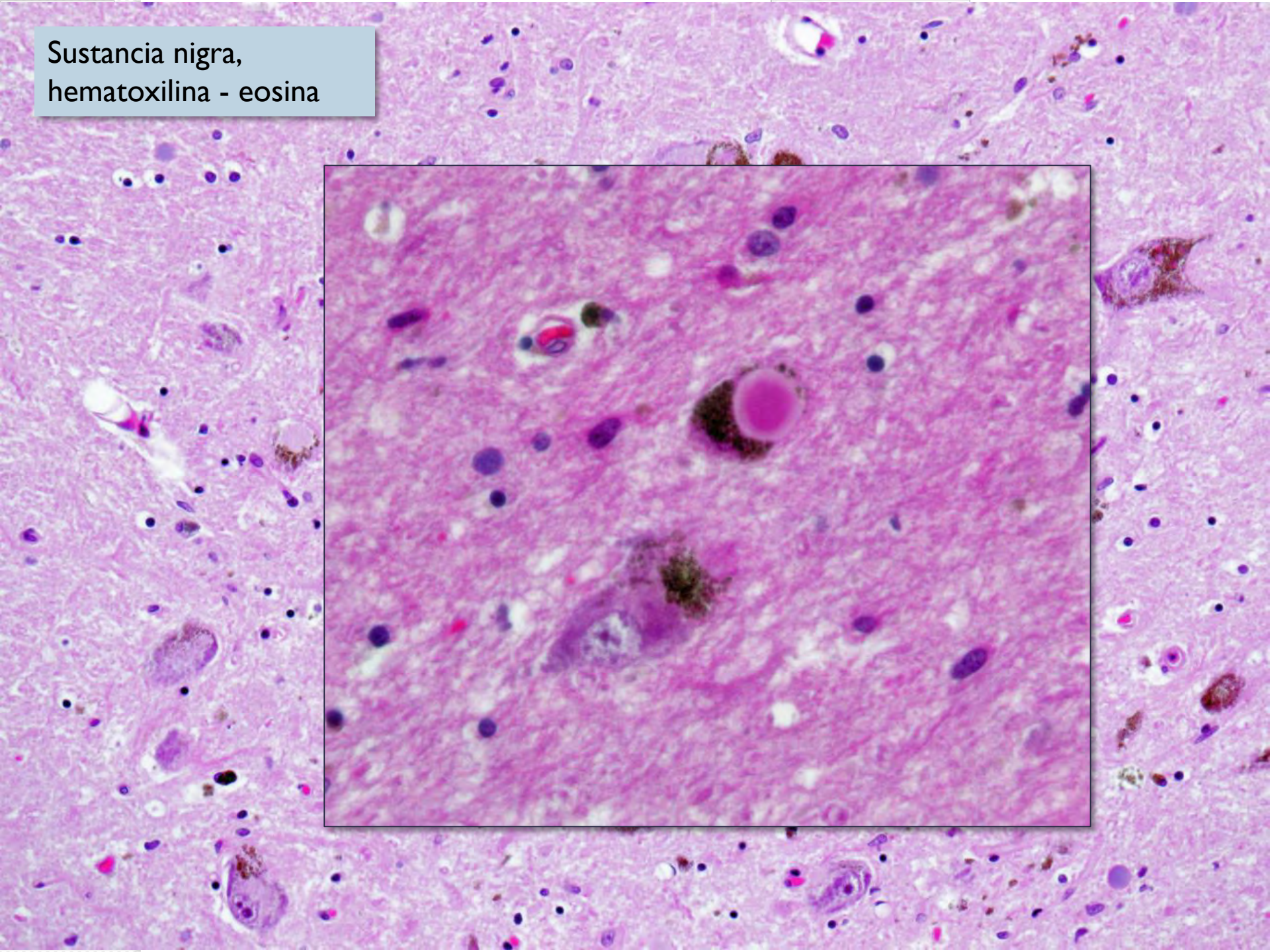

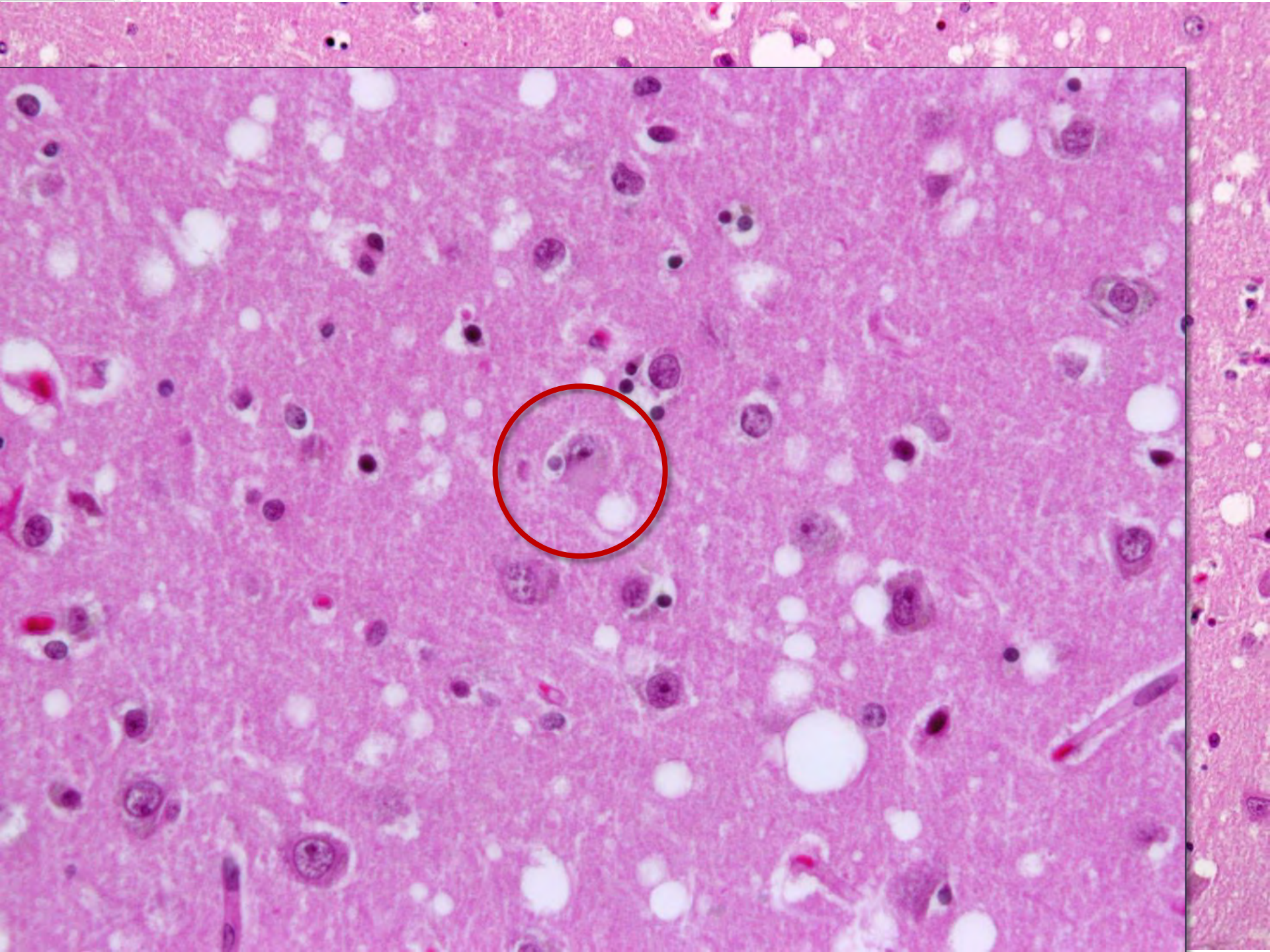

Alfa-sinucleína

Córtex cingular

Córtex frontal lateral

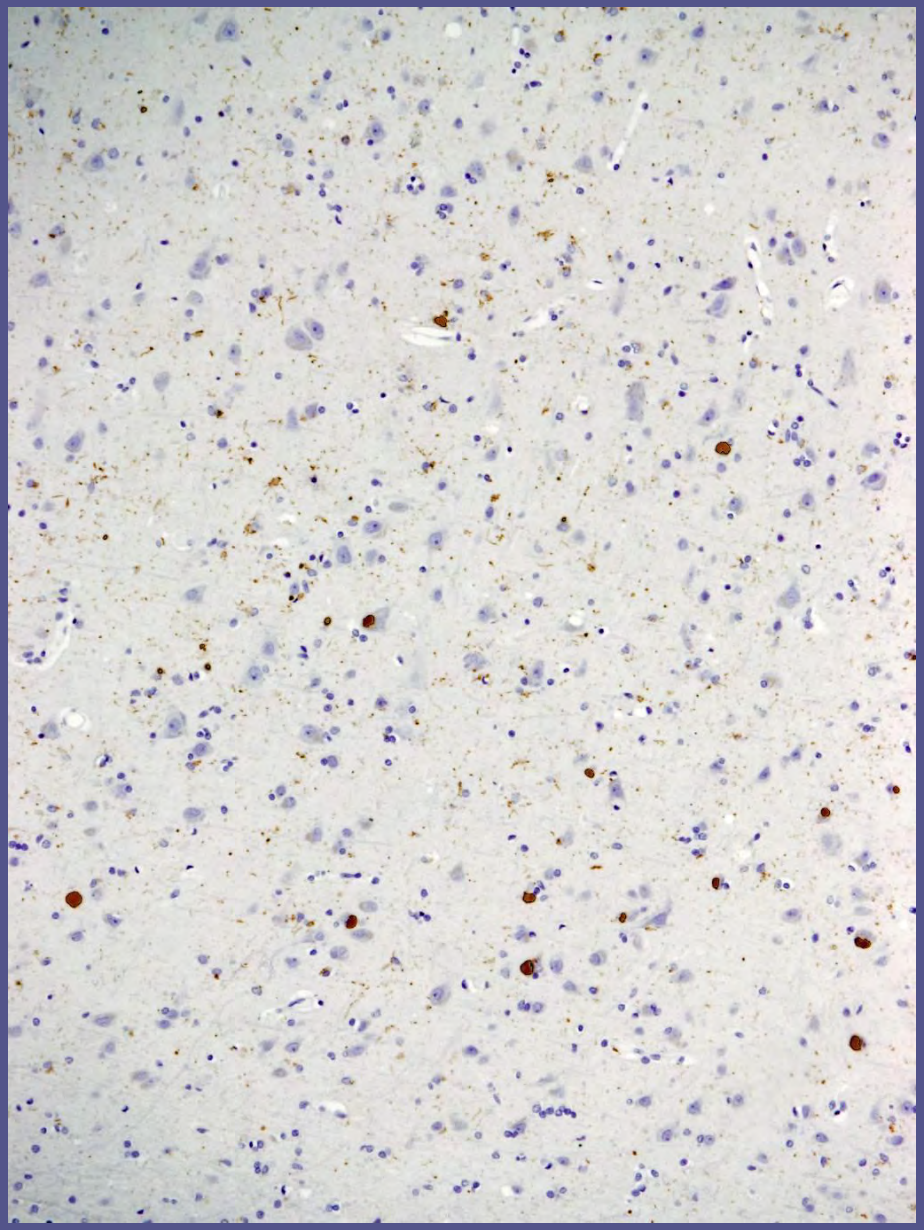

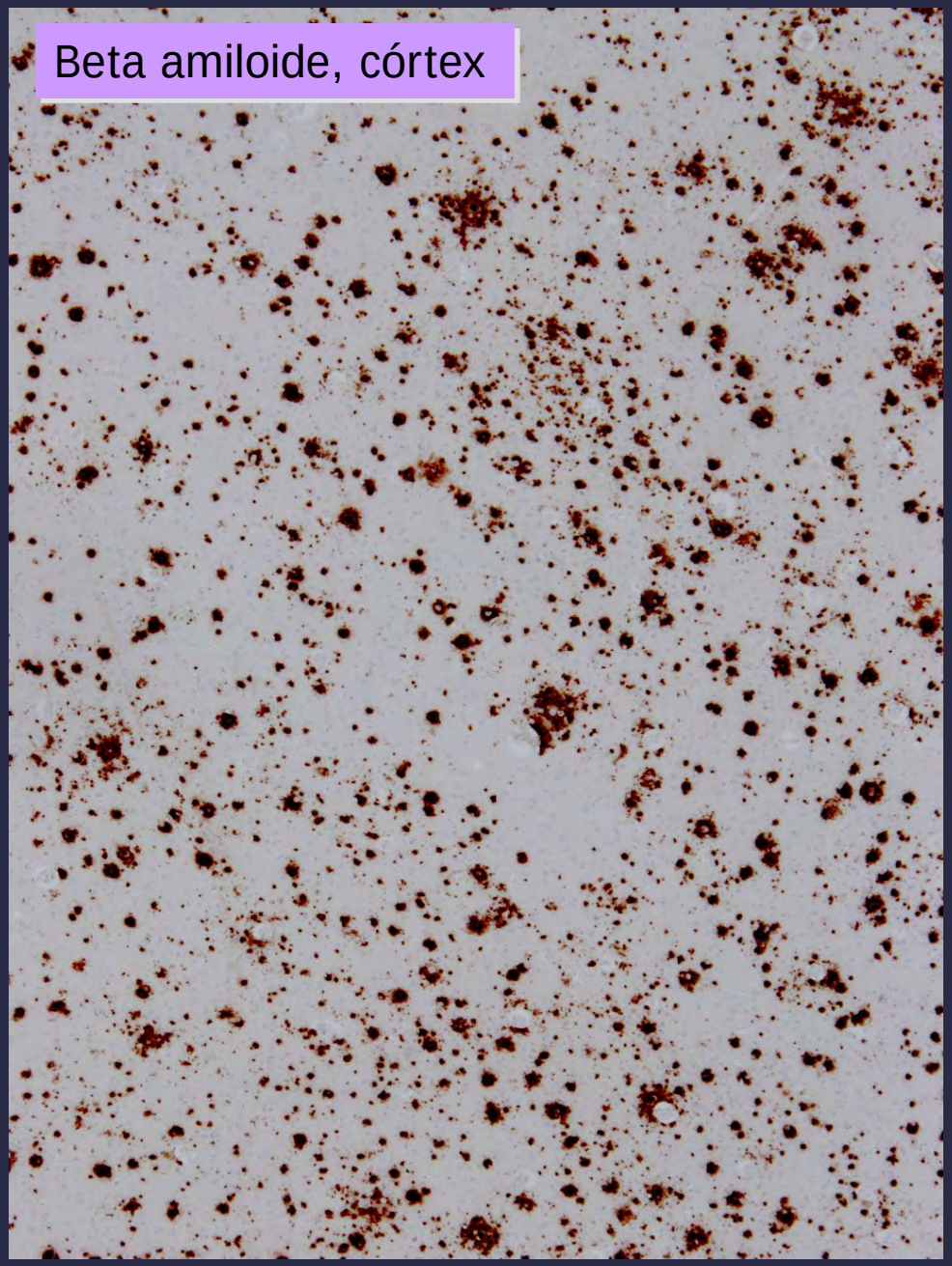
Beta amiloide, córtex

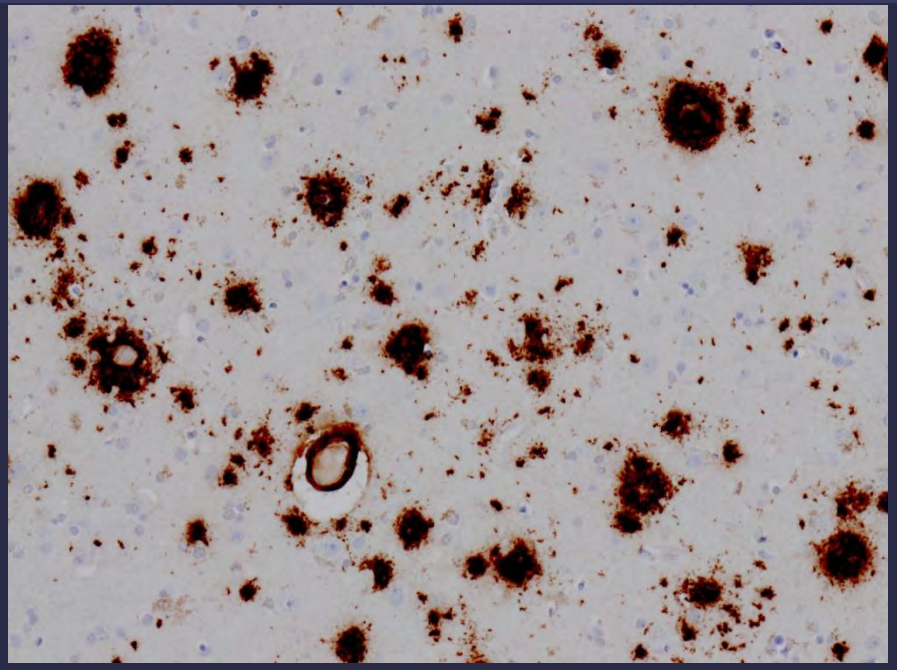

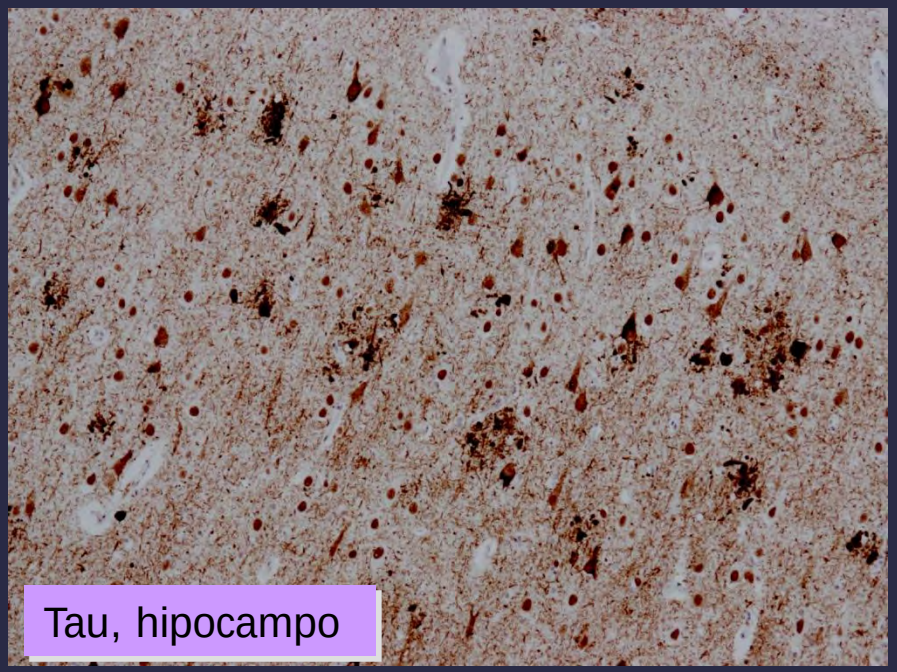
Tau, hipocampo

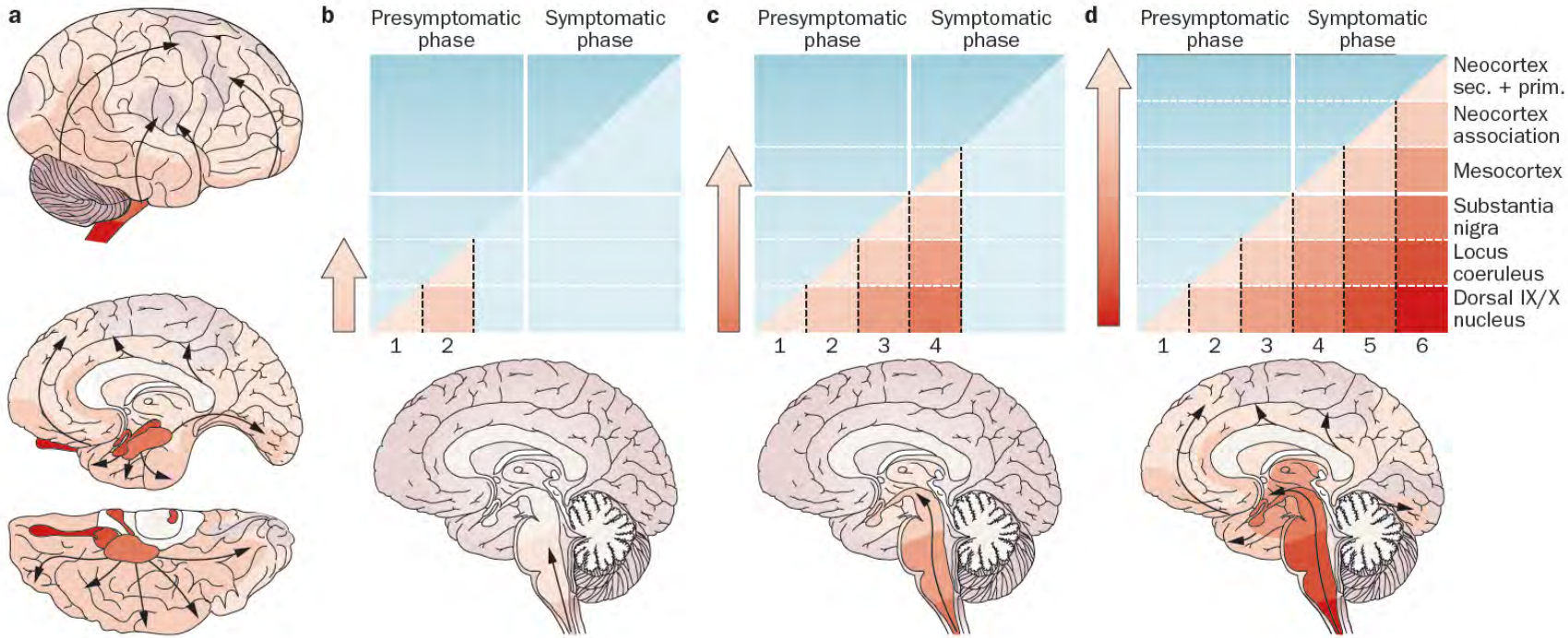

Sampled brain areas	Medulla		Pons		Midbrain	Basal Forebrain		Hippocampus		Gyrus cinguli	Temporal cortex	Frontal cortex	Parietal cortex
Anatomical region	dmV	irx	LC	R	SN	nbM	AC	CA2	TOcx	grey matter	grey matter	grey matter	grey matter
Braak stage	1	1	2	2	3	3	4	3	4	5	5	6	6
McKeith type	BRAINSTEM					LIMBIC						NEOCORTICAL	
Amygdala predominant							AC predominant						
Lesion type requested	LBs and / or LNs						LBs	LNs	LBs				

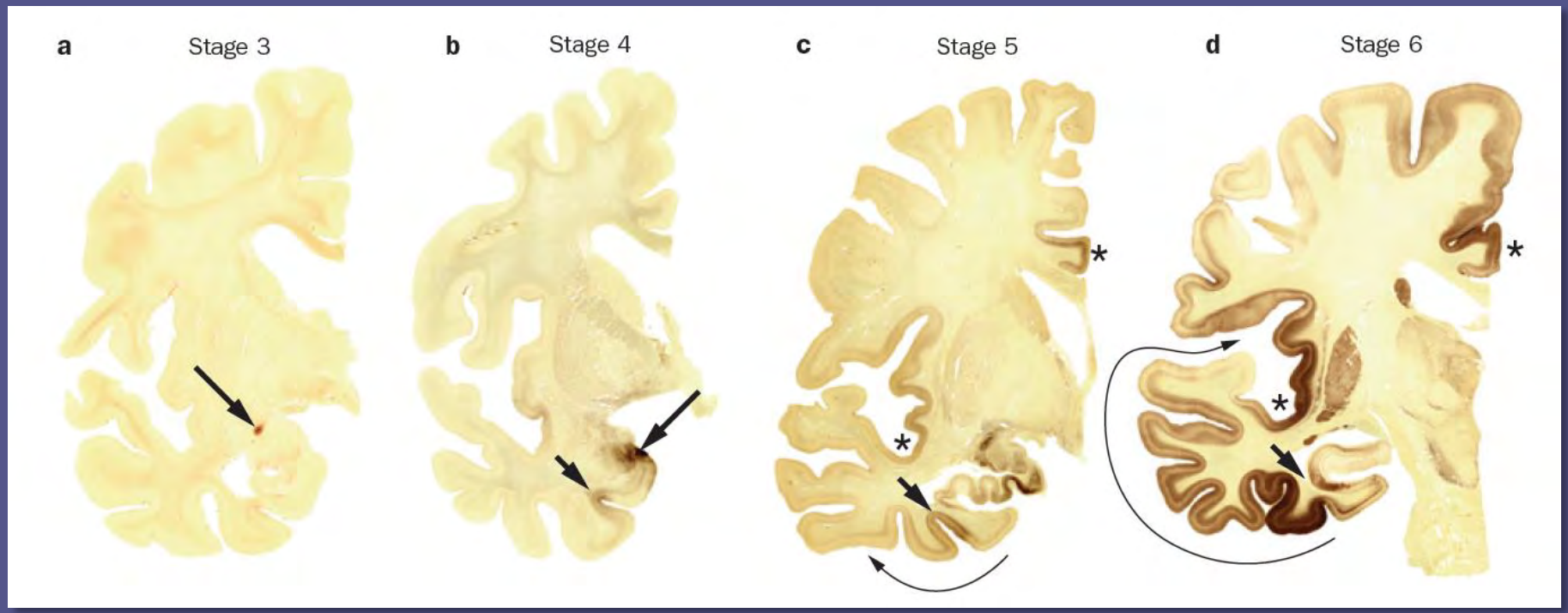

Goedert, M. *et al. Nat. Rev. Neurol.* **9**, 13–24 (2013)

Table 4 Classification of Lewy body disease

None	No LBs or related changes in IHC for α-synuclein
Brainstem-predominant	LBs in medulla, pons, or midbrain
Limbic (Transitional)	LBs in cingulate or entorhinal cortices, usually with brainstem involvement
Neocortical (Diffuse)	LBs in frontal, temporal, or parietal cortices usually with involvement of brainstem and limbic sites, which may include amygdala
Amygdala-predominant	LBs in amygdala with paucity of LBs in the above regions

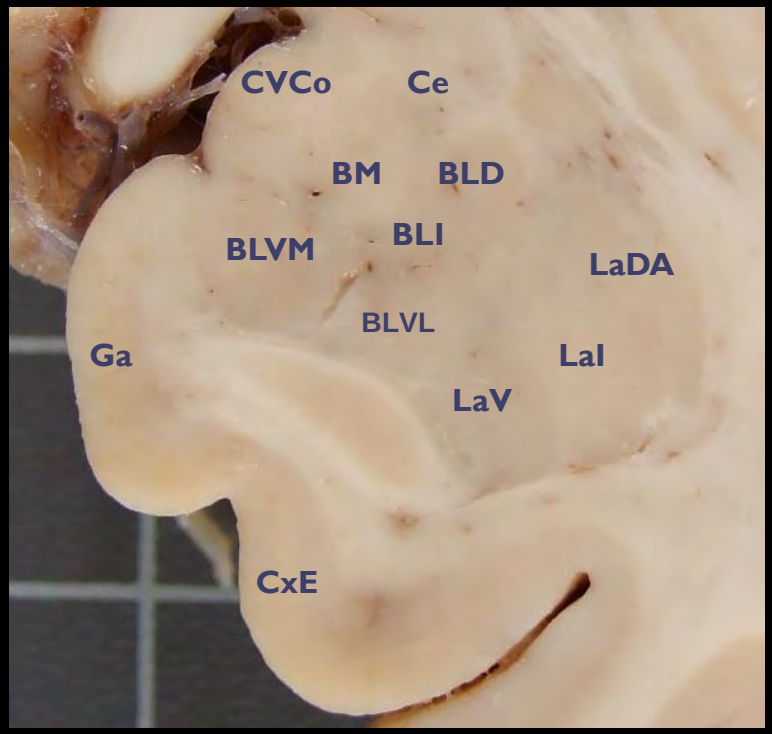
CVCo
Ce
BM
BLD
BLVM
BLI
LaDA
BLVL
Ga
LaI
LaV
CxE

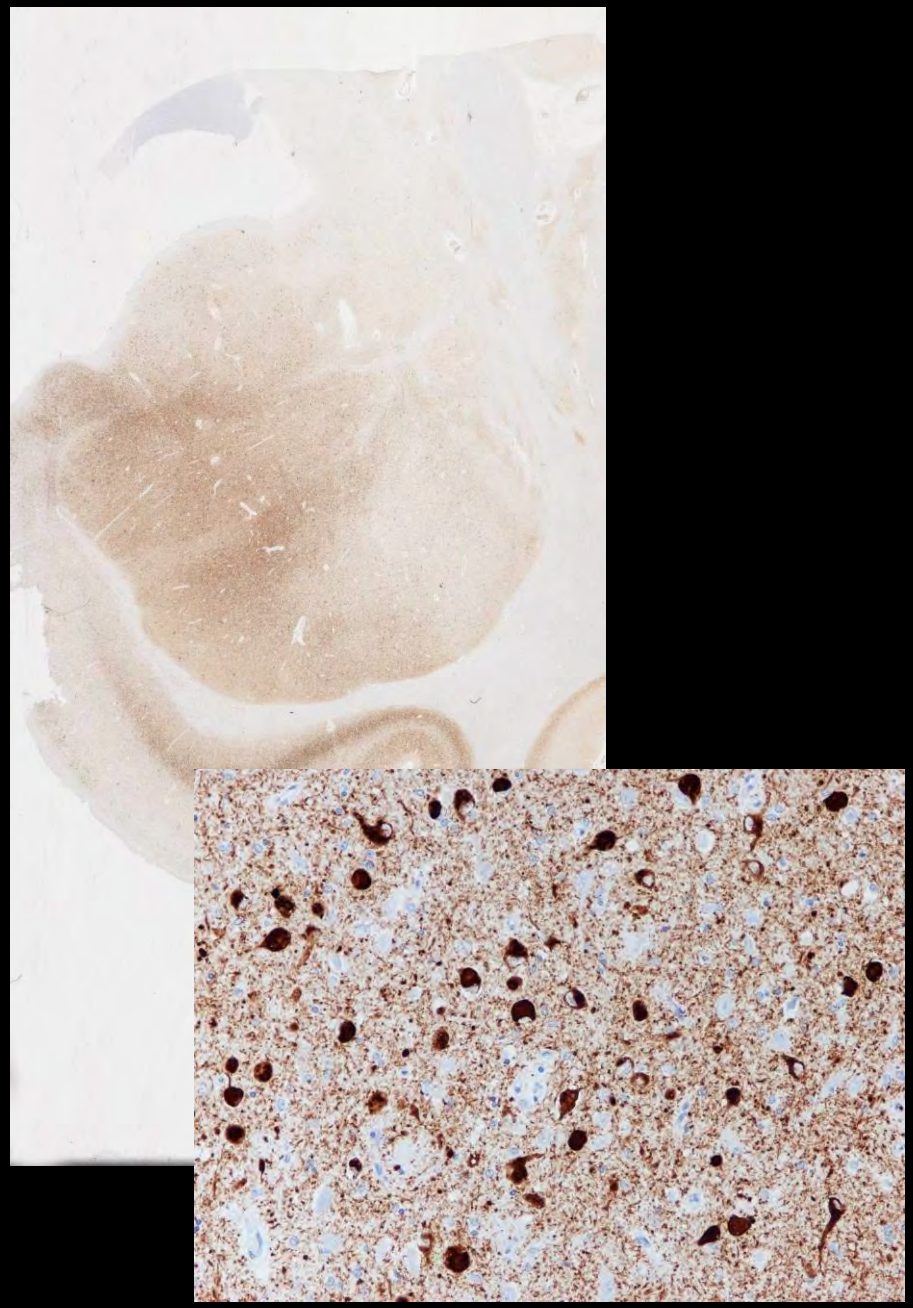

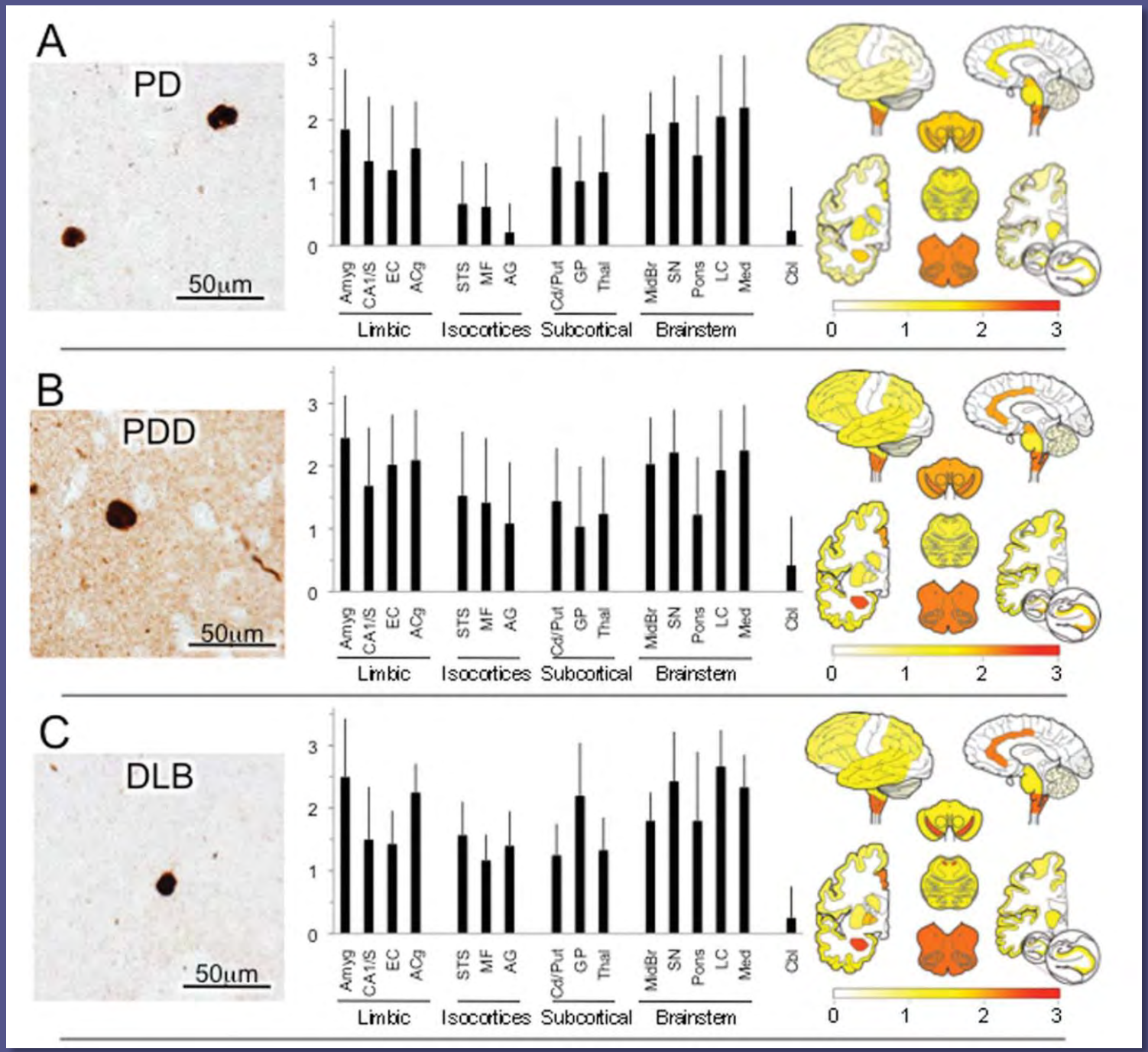
A
PD
50μm
B
PDD
50μm
C
DLB
50μm
0
1
2
3
Amyg
CA1/S
EC
ACg
STS
MF
AG
Cd/Put
GP
Thal
MidBr
SN
Pons
LC
Med
Cbl
Limbic
Isocortices
Subcortical
Brainstem

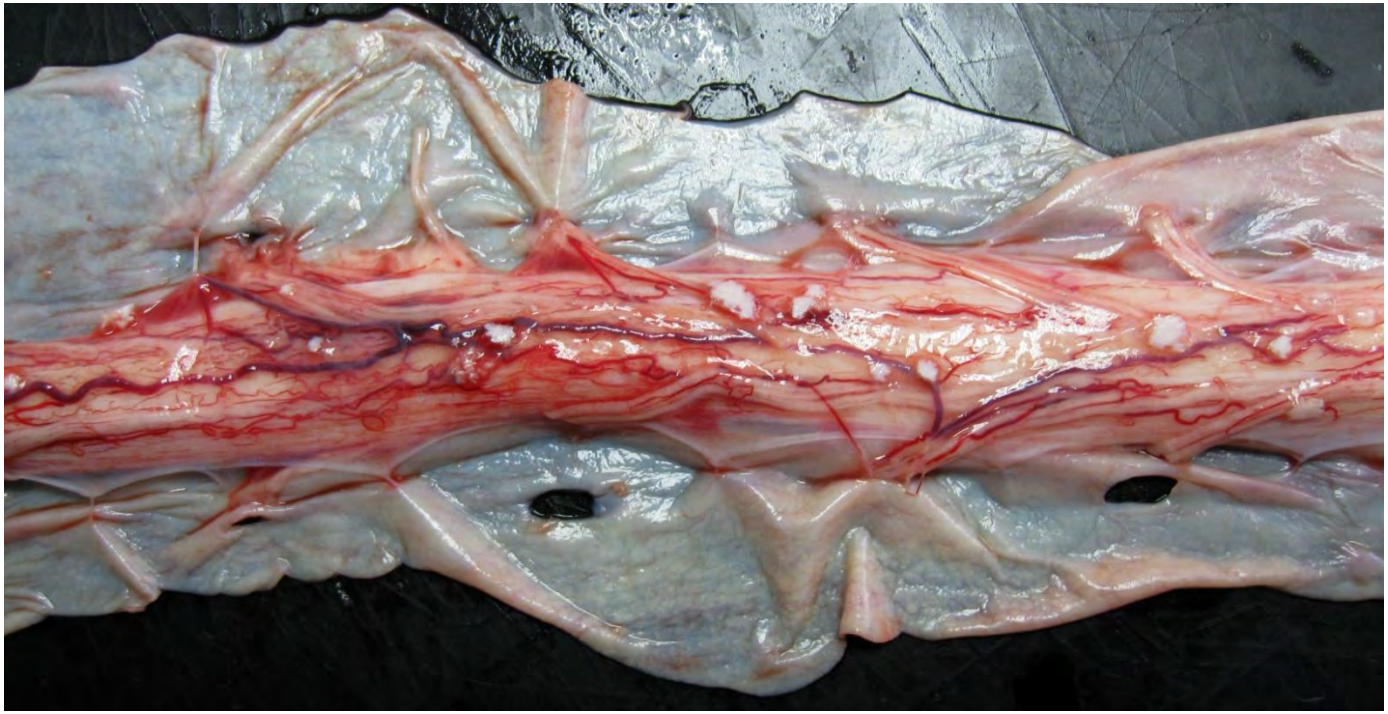

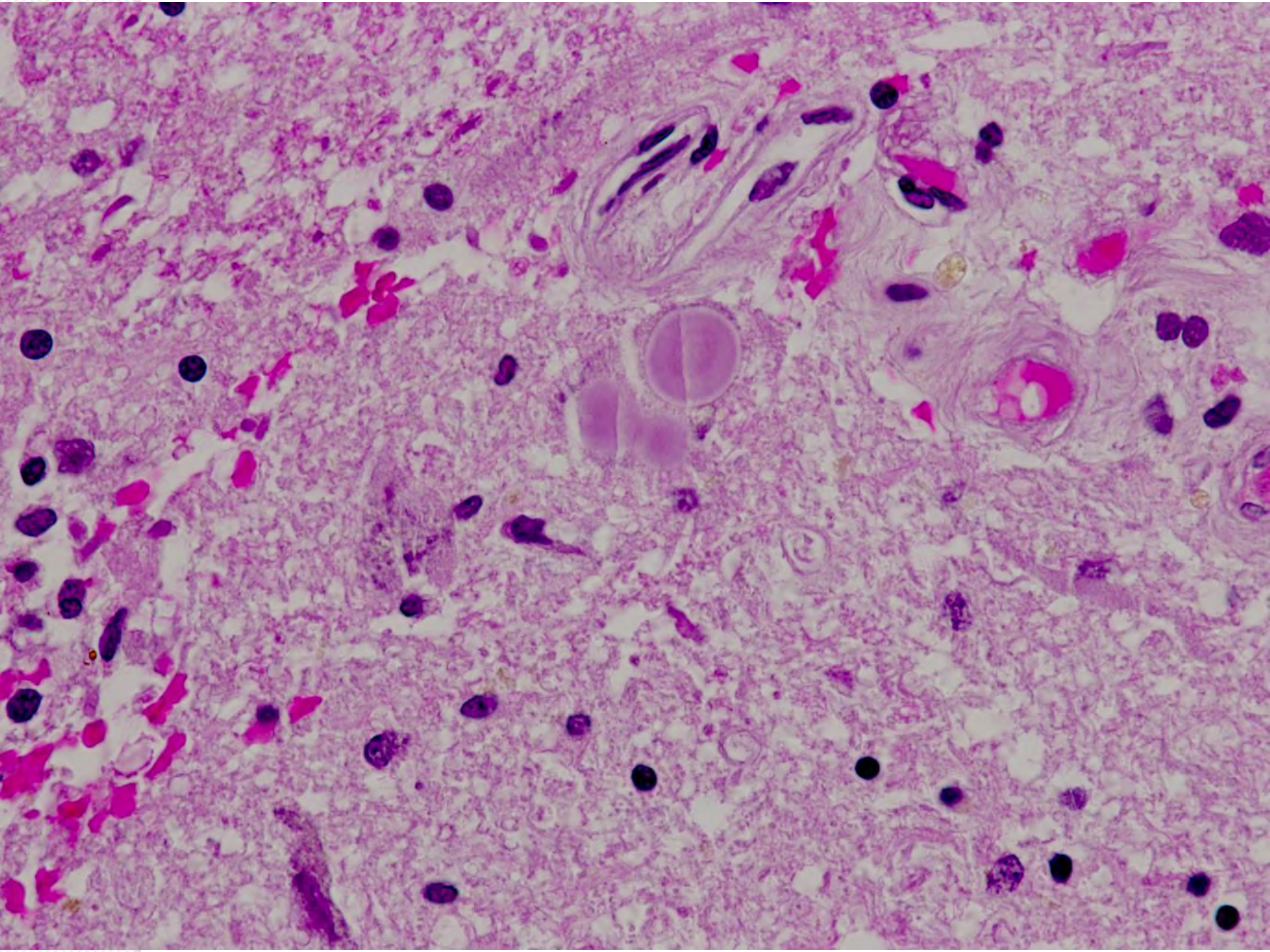

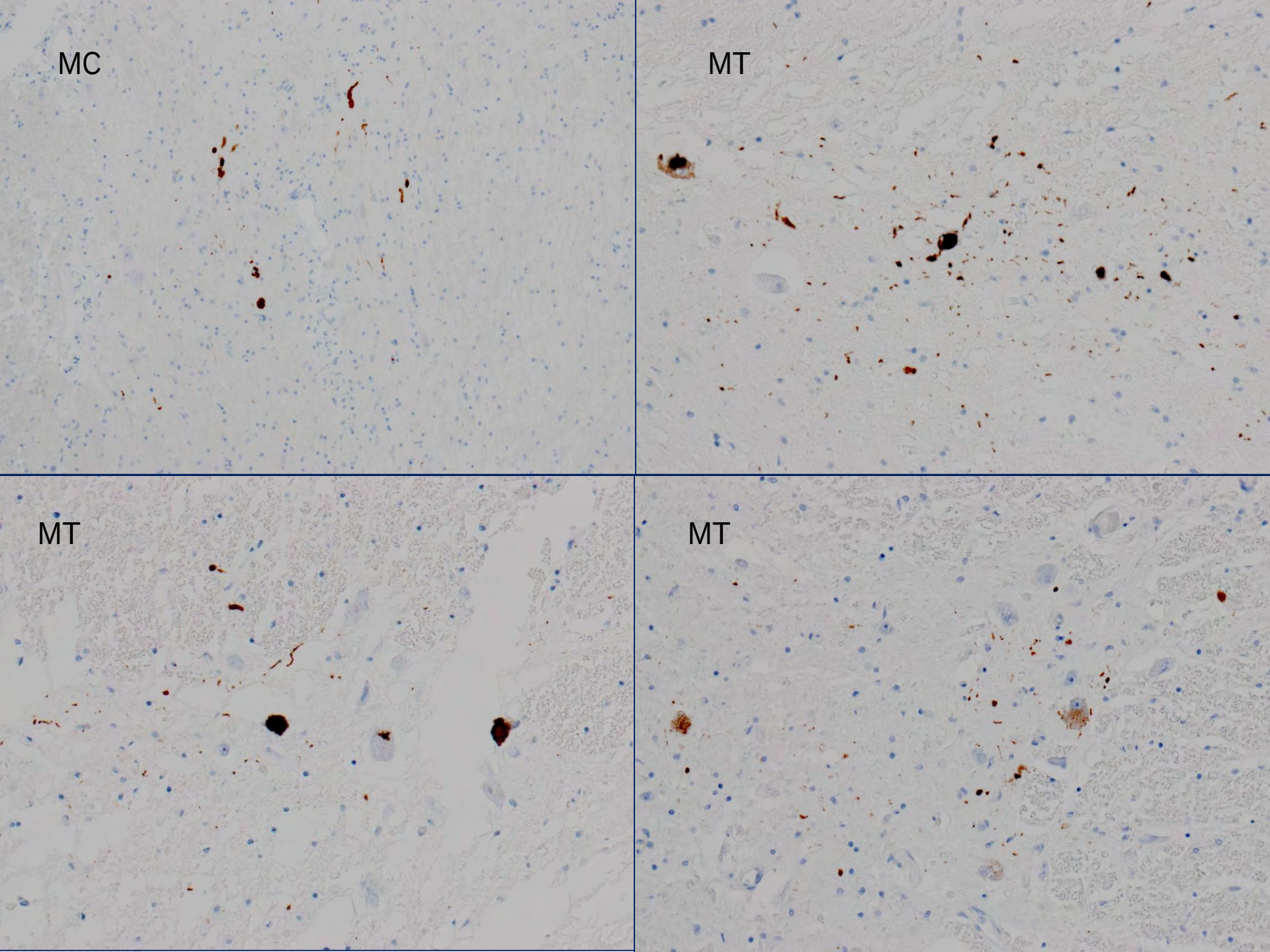
MC
MT
MT
MT

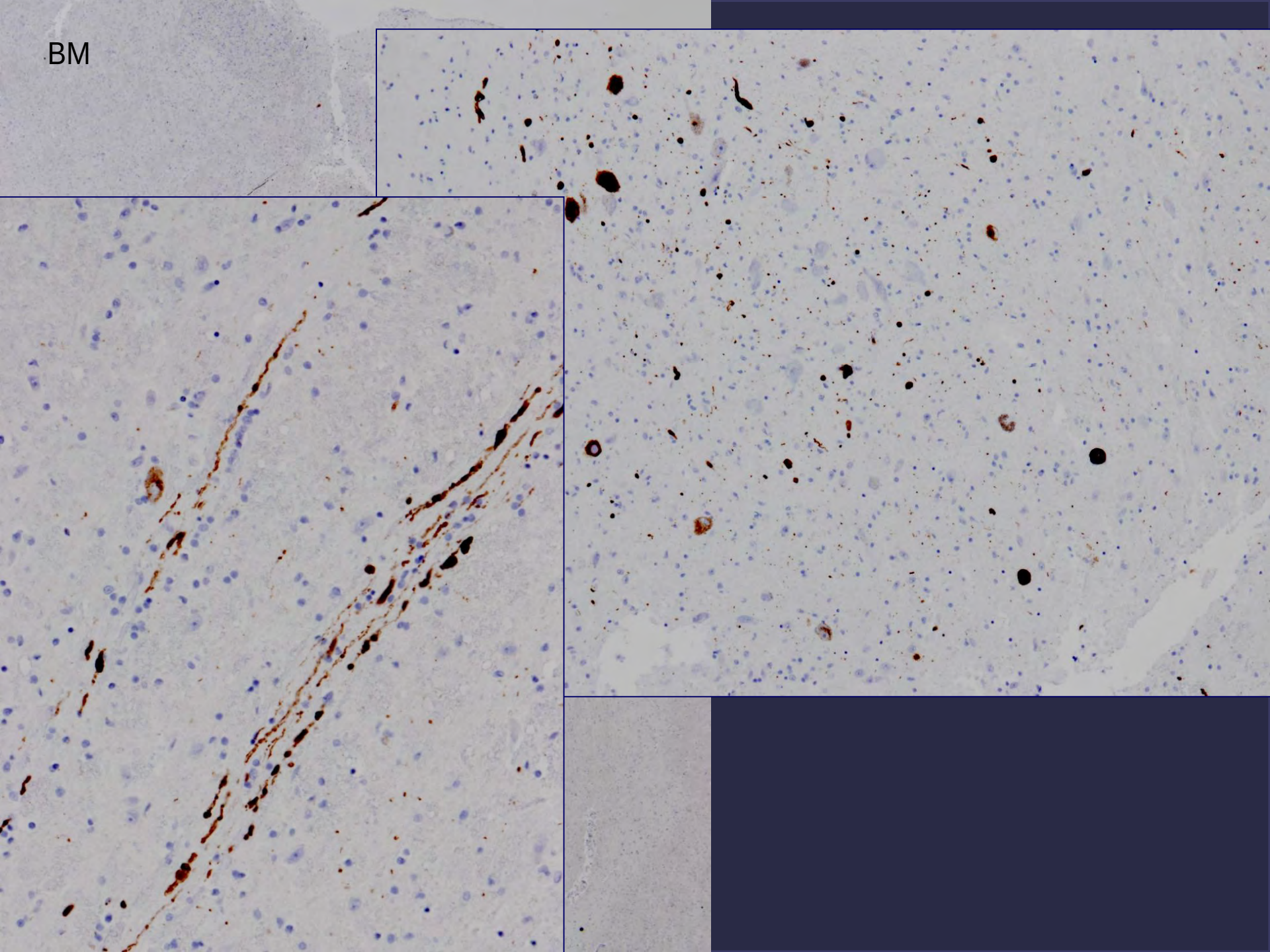
BM

Acta Neuropathol (2007) 114:295–298
DOI 10.1007/s00401-007-0233-6

CASE REPORT

Lewy body dysphagia

Enikö Kövari · Karim Burkhardt · Johannes Alexander Lobrinus · Constantin Bouras

Case 1

This 89-year-old man developed dysphagia 4 years prior to death. He had multiple transient ischemic attacks (TIA) in a setting of auricular fibrillation with anticoagulation treatment. He suffered two novel TIAs 2 months before death, first with right hemiparesis; the second time 4 days later with paresis of the right arm and dysarthria. Neurological examination revealed a severe hypophonia and dysphagia, prompting a clinical suspicion of PSP with affection of cranial nerve X, but no further investigations were performed. The CT scan showed hypodensities in the left Sylvian and insular regions, possibily representing brain infarcts. He died of bronchopneumonia, confirmed by autopsy. Other autopsy findings were moderate atherosclerosis, pulmonary emphysema, and cardiac hypertrophy.

Case 2

An 86-year-old man was admitted to the hospital because of dyspnea, auricular fibrillation and suspicion of pulmonary abscess. In his anamnesis dysphagia was noted, beginning 2 years before death and progressing to aphagia. The performed oesophagogastroduodenoscopy did not yield any explication for dysphagia. The rest of his neurological status was normal. The clinical differential diagnosis included pseudobulbar palsy and amyotrophic lateral sclerosis (ALS). He died due to bronchopneumonia. The systemic autopsy revealed bilateral bronchopneumonia with empyema, pulmonary emphysema, mild atherosclerosis, cardiac hypertrophy, and a tubular adenoma of the colon.

ORIGINAL CONTRIBUTION

Ecology of the Aging Human Brain

Joshua A. Sonnen, MD; Karen Santa Cruz, MD; Laura S. Hemmy, PhD; Randall Woltjer, MD, PhD; James B. Leverenz, MD; Kathleen S. Montine, PhD; Clifford R. Jack, MD; Jeffrey Kaye, MD; Kelvin Lim, MD; Eric B. Larson, MD, MPH; Lon White, MD, MPH; Thomas J. Montine, MD, PhD

Table 1. Characteristics of the 1672 Participants by Study

Characteristic	ACT	HAAS	NS	OBAS	Total
Total autopsies, No.	344	446	548	334	**1672**
Last evaluation within 2 y of death, No.	299	262	475	280	**1316**
"Not dementia" by *DSM* at last evaluation, No.[a]	182	126	182	166	**656**
Eligible cases					
Upper 4 quintiles of cognition function for the entire cohort, No.[b]	116	59	162	87	**424**
Complete neuropathologic examination, No.	116	59	106[c]	55[d]	**336**
Age at death, mean (SD), y	84 (6)	83 (5)	89 (5)	91 (5)	87 (4)
Sex, M/F, No.	52/64	59/0	0/106	23/32	134/202
Last MMSE score, median (range)	28 (25-30)	27 (23-29)	28 (24-30)	29 (28-30)	NA
Last CASI score, mean (SD)	95 (3)	89 (4)	NA	NA	NA
Brain weight, mean (SD), g	1178 (143)	1292 (101)	1143 (122)	1222 (125)	1209 (64)

Arch Neurol. 2011;68(8):1049-1056

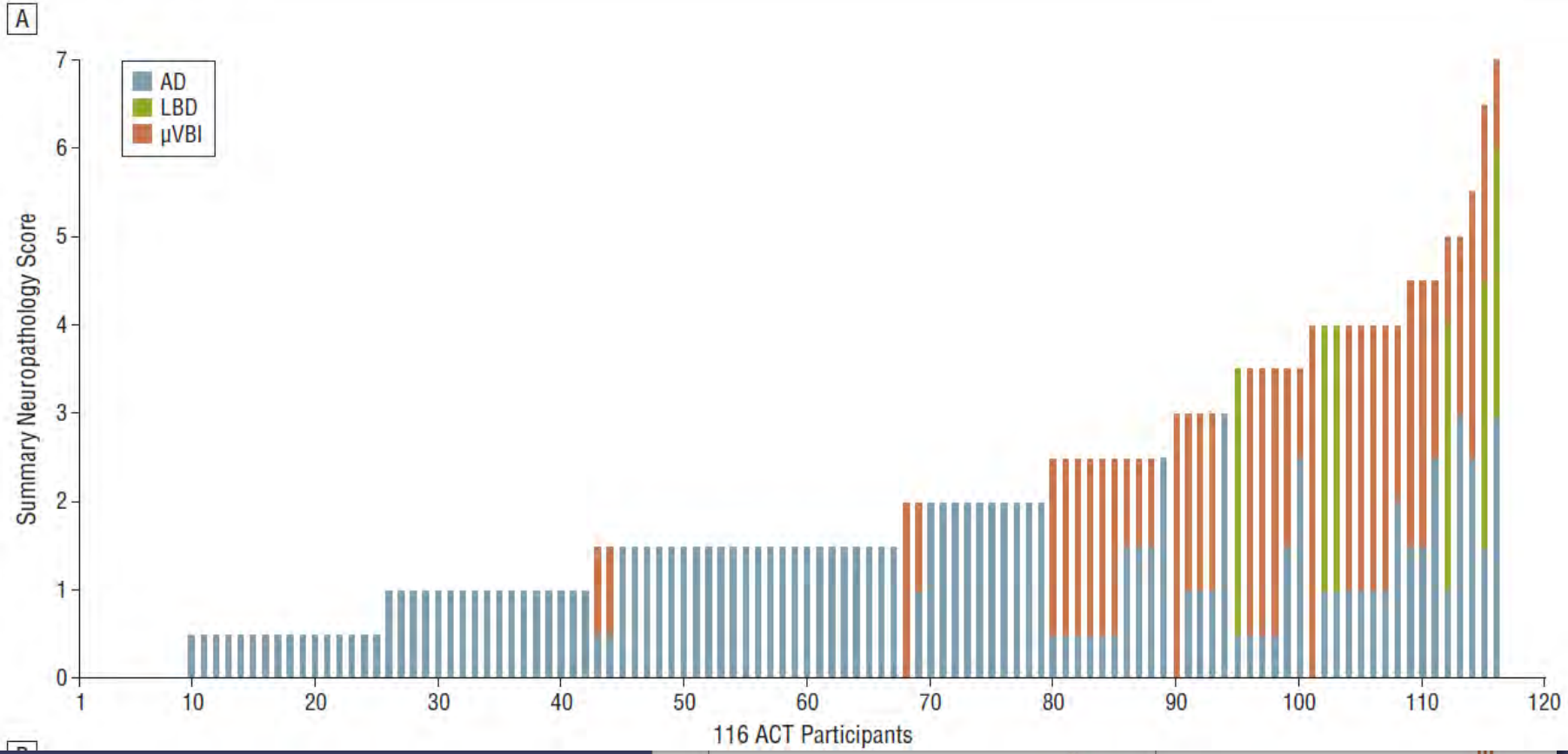

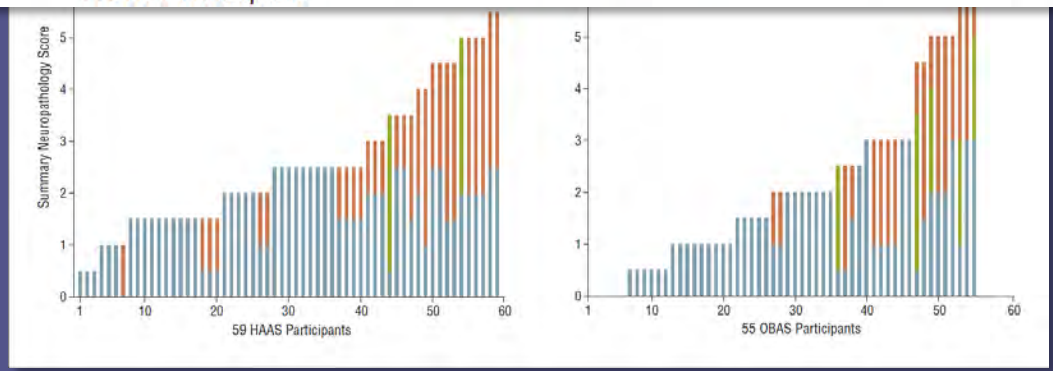

Arch Neurol. 2011;68(8):1049-1056

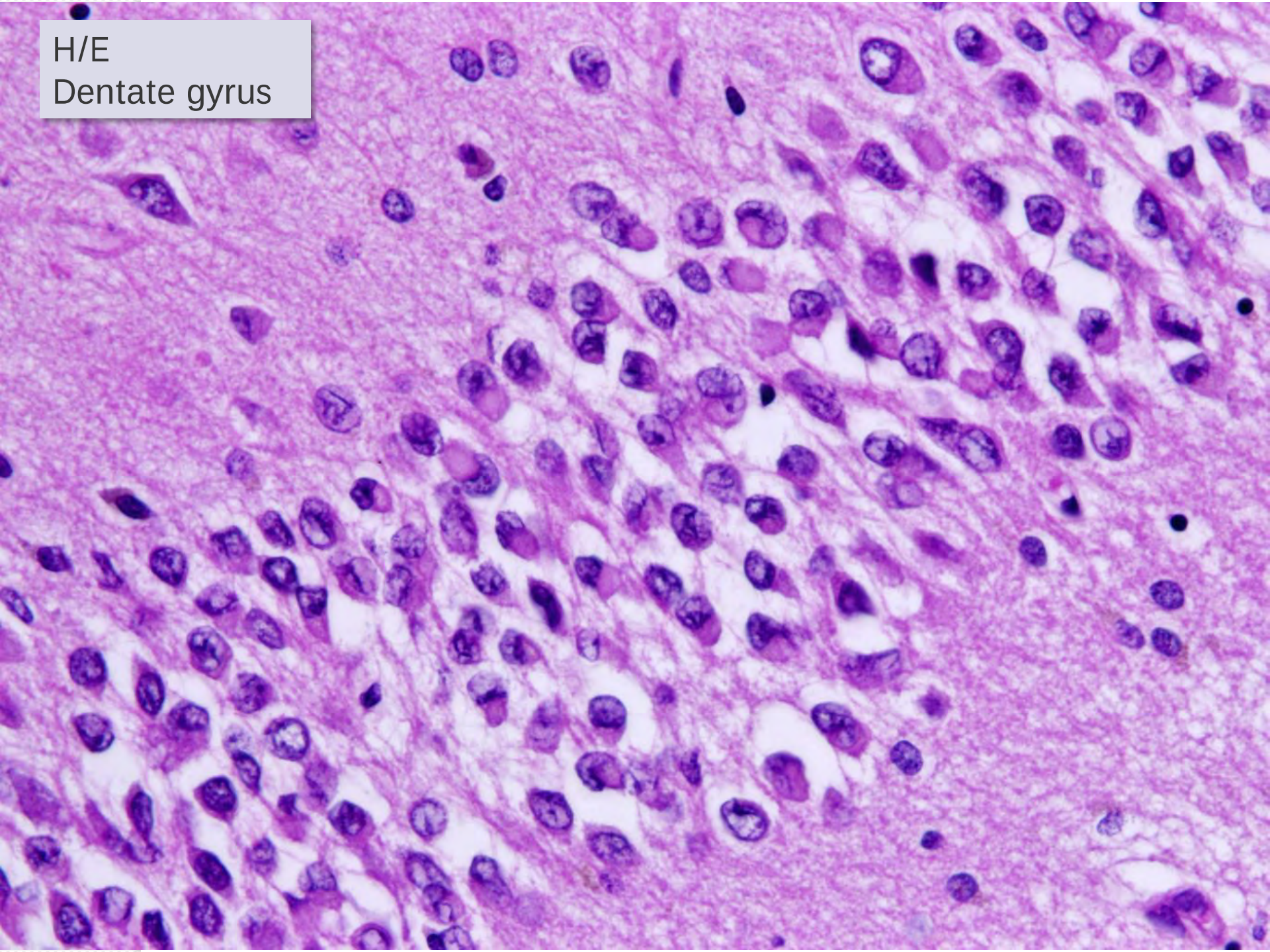
H/E
Dentate gyrus

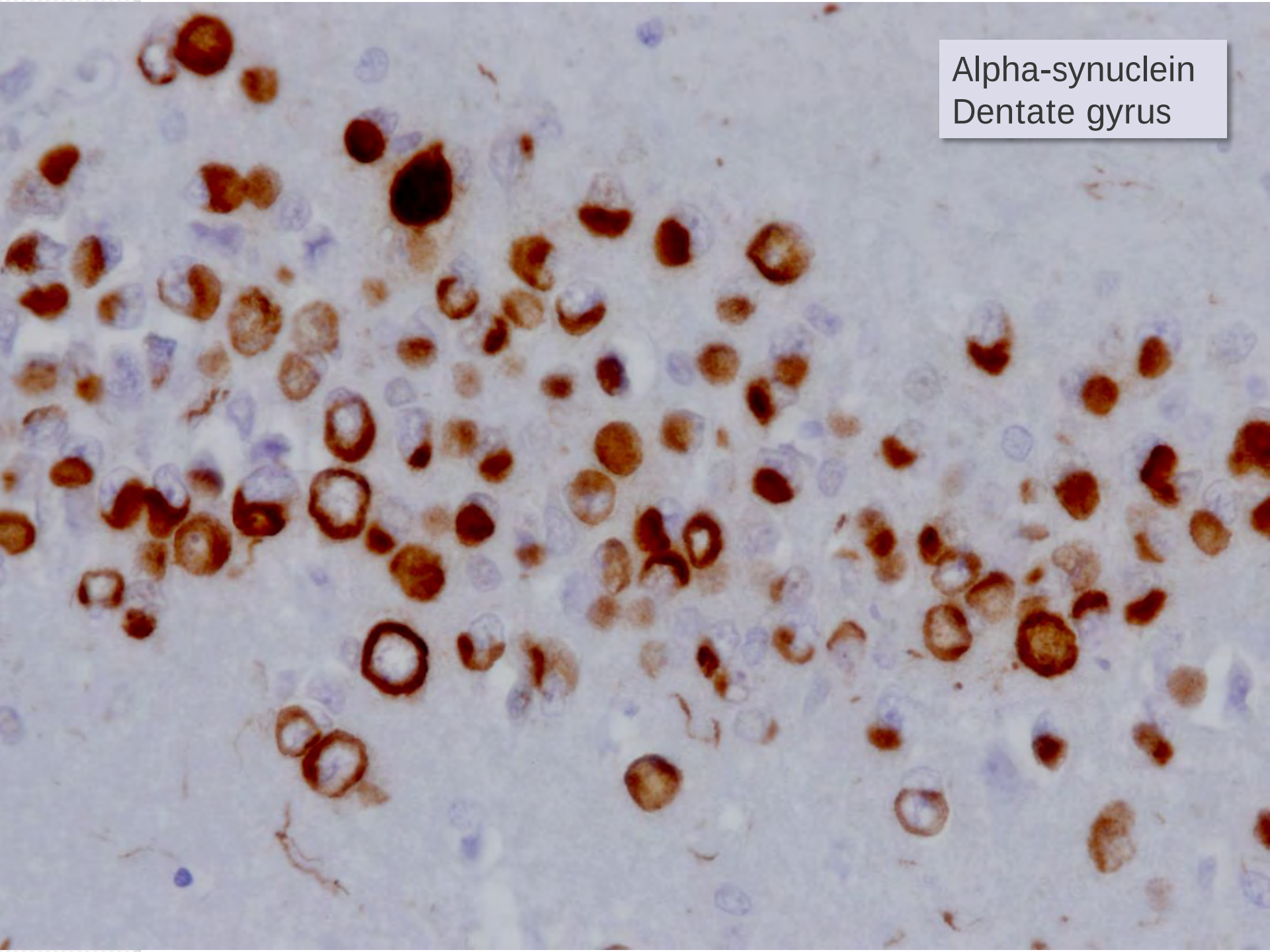
Alpha-synuclein
Dentate gyrus

Degeneración lobar frontotemporal

Cx. temporal

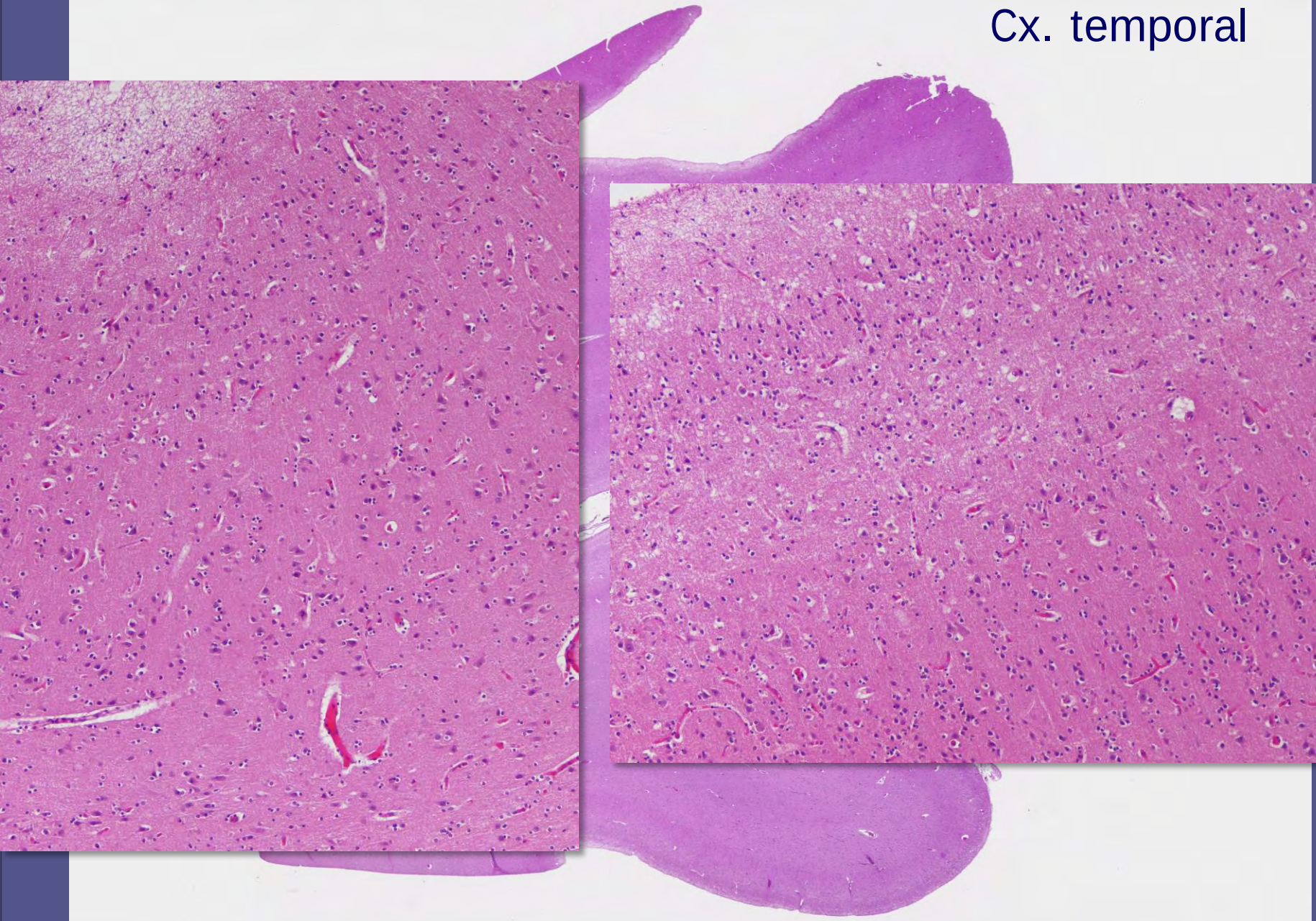

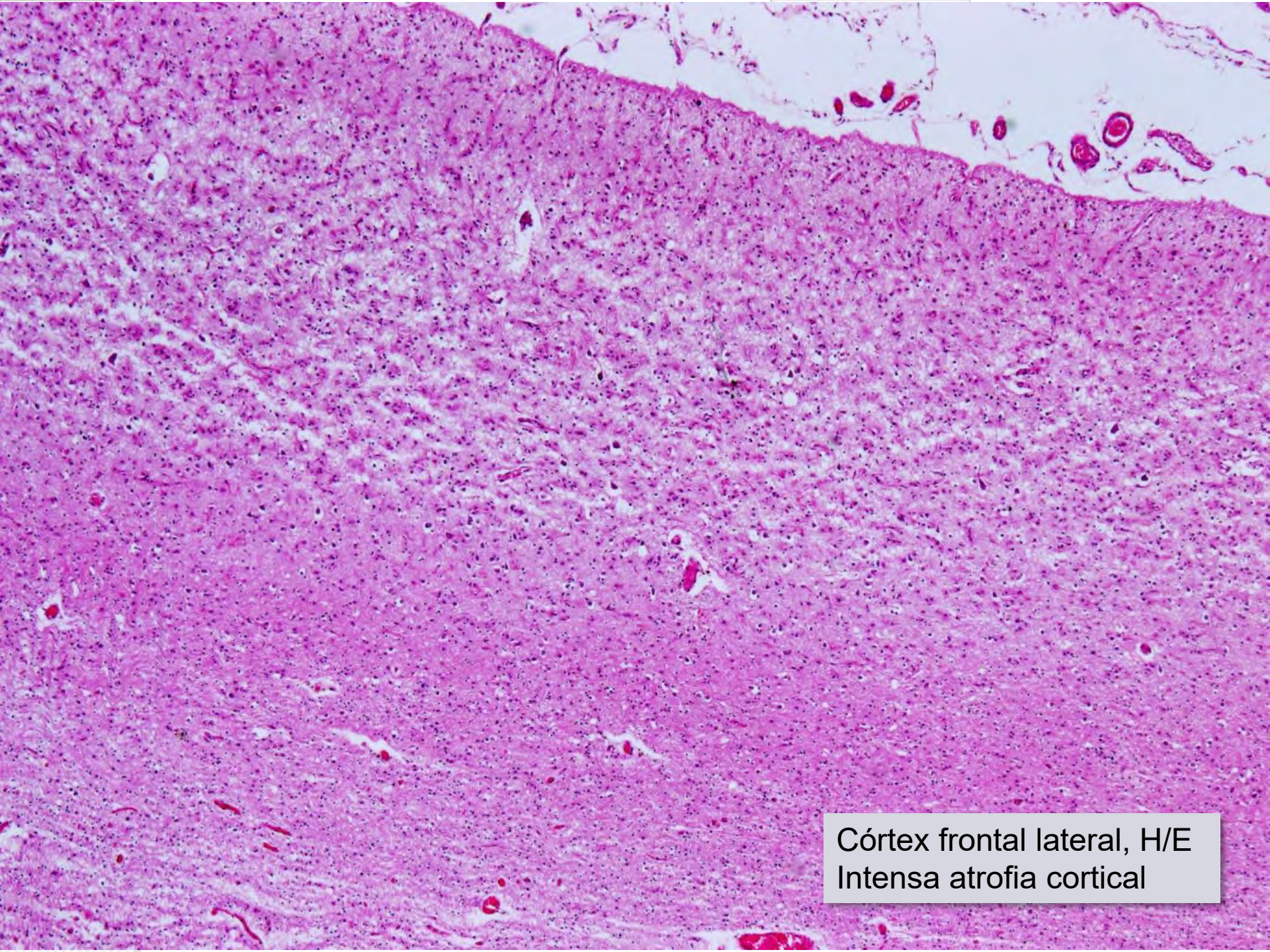
Córtex frontal lateral, H/E
Intensa atrofia cortical

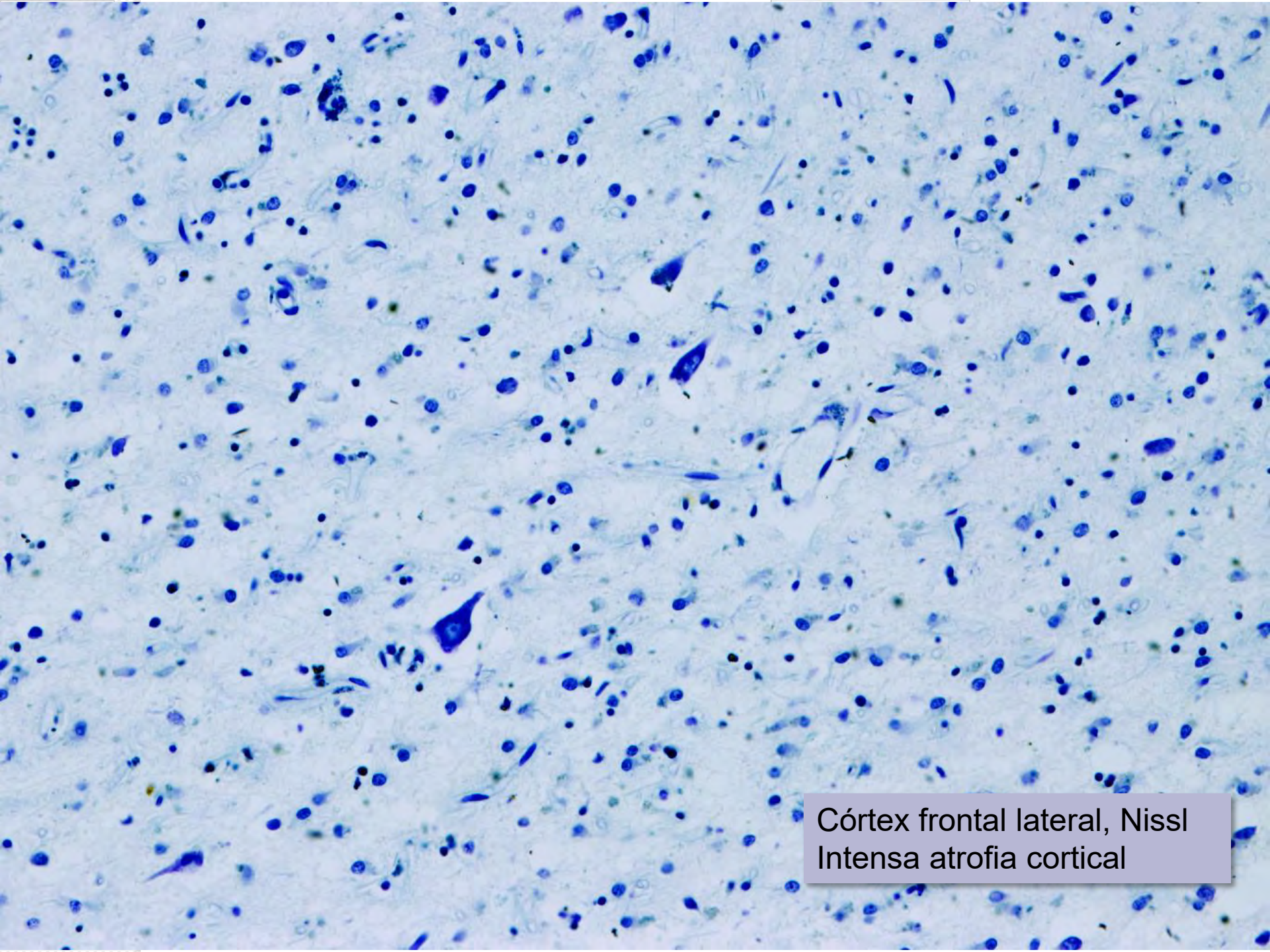
Córtex frontal lateral, Nissl
Intensa atrofia cortical

FTLD Protocol Flowchart

REGIONS: MFG, STG, PL, HIP (with DG), CG

STAINS: H & E, Tau (e.g. PHF1, AT8), Ub or p62 , α-Synuclein

If not high-Braak stage AD or high-probabilty DLB, proceed with specific FTLD protocol

Tau +

Tau IHC on additional sections, if indicated: OL, AMYG, STR, GP, THAL/SUBTN, MID, PONS, MED, CBLM including DN

Use morphological criteria (e.g. tufted astrocytes, grains, etc) and, as required, use tau isoform-specific IHC:

3R & 4R tau on HIP & MFG if Tau **+**, additional sections as indicated.

3R Tau + → **FTLD with Pick bodies**

***MAPT* mutation** → **FTLD with *MAPT* mutation** (3R, 4R, or 3R & 4R Tau)

4R Tau + → **CBD, PSP, AGD, MSTD, Unclassifiable tauopathy**

3R & 4R Tau + → **Neurofibrillary tangle dementia**

*Note:
1. "Unclassifiable sporadic tauopathies" may be predominantly either 3R, 4R, or combined 3R and 4R tauopathies.
2. Coexisting neurodegenerative disease(s) may also be present.

Tau - & no Ub/p62 inclusions seen → Prion **+** ➔ **Prion disease**; Prion **-** ➔ **DLDH** or FTLD, NOS

Ub +/p62 +, Tau -, -Syn -, *OR* case is ALS

TDP-43 IHC on STR, MED, SC (if available), or same sections as for Tau IHC AND

NF or INA IHC on area with highest density of Ub+ or p62 +inclusions;

If either is positive, repeat on MFG, STG, HIP, CING

Mutation analysis (PGRN, *VCP*, *CHMP2B*, *IFT74*) as indicated.

TDP-43 +, NF or INA - → **TDP-43 proteinopathy:**
FTLD-U
FTLD-U with MND
with or without *PGRN* or *VCP* mutation or chr 9p linkage

TDP-43 –

NF or INA + → **NIFID**

NF or INA - → **BIBD** or **FTLD-U with *CHMP2B* mutation**

Atypical FTLD-U

FUS (+)

Nigel J. Cairns · Eileen H. Bigio · Ian R. A. Mackenzie · Manuela Neumann · Virginia M. -Y. Lee ·Kimmo J. Hatanpaa · Charles L. White III · Julie A. Schneider · Lea Tenenholz Grinberg · Glenda Halliday ·Charles Duyckaerts · James S. Lowe · Ida E. Holm · Markus Tolnay · Koichi Okamoto · Hideaki Yokoo ·Shigeo Murayama · John Woulfe · David G. Munoz · Dennis W. Dickson · Paul G. Ince · John Q. Trojanowski ·David M. A. Mann. Neuropathologic diagnostic and nosologic criteria for frontotemporal lobar degeneration: consensus of the Consortium for Frontotemporal Lobar Degeneration. Acta Neuropathol (2007) 114:5–22.

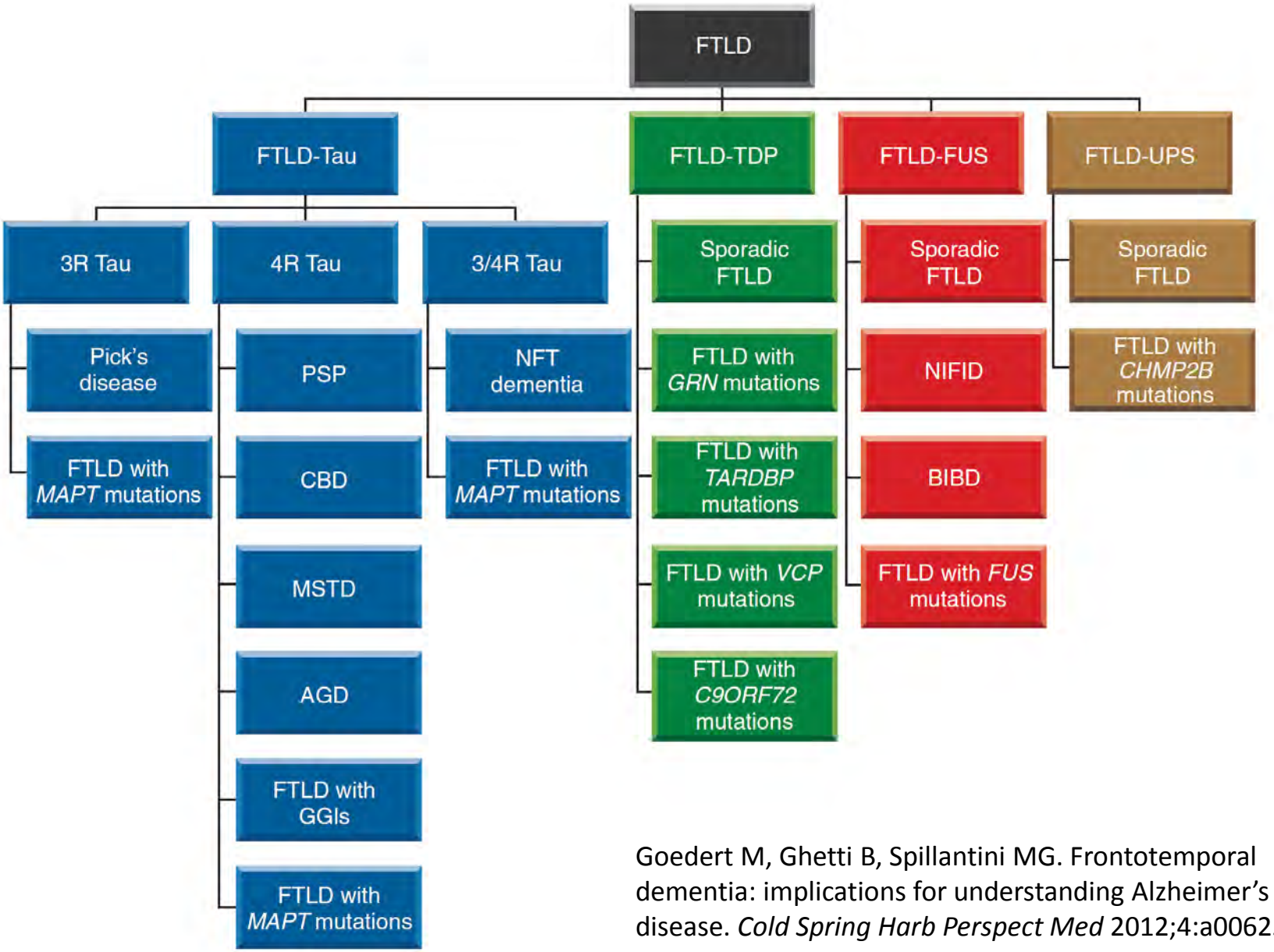

Goedert M, Ghetti B, Spillantini MG. Frontotemporal dementia: implications for understanding Alzheimer's disease. *Cold Spring Harb Perspect Med* 2012;4:a006254

Taupatías

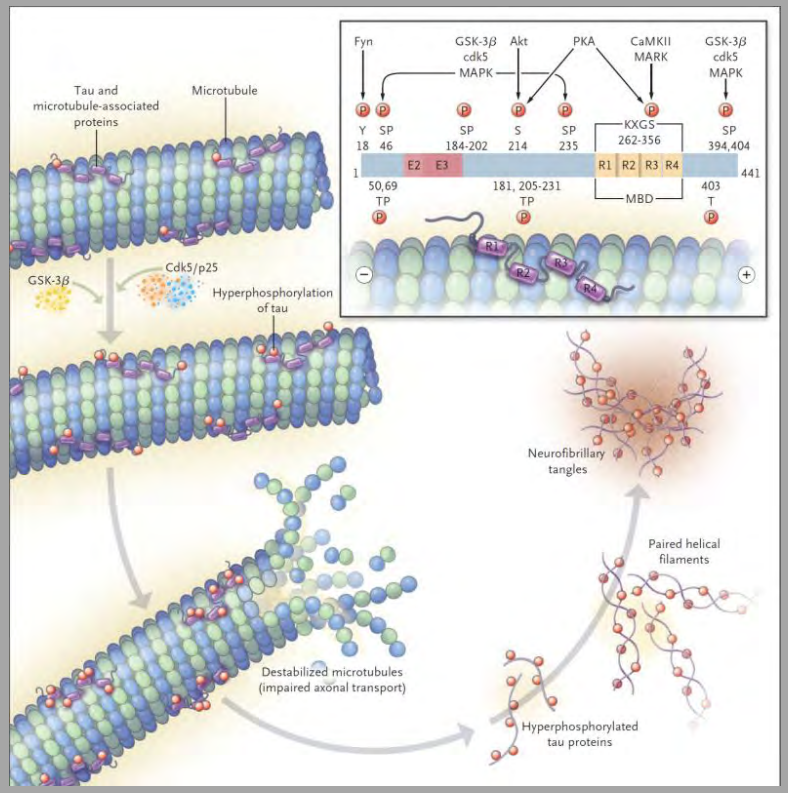
Tau and microtubule-associated proteins
Microtubule
GSK-3β
Cdk5/p25
Hyperphosphorylation of tau
Destabilized microtubules (impaired axonal transport)
Hyperphosphorylated tau proteins
Paired helical filaments
Neurofibrillary tangles
Fyn
GSK-3β cdk5 MAPK
Akt
PKA
CaMKII MARK
GSK-3β cdk5 MAPK
Y 18
SP 46
SP 184-202
S 214
SP 235
KXGS 262-356
SP 394,404
E2 E3
R1 R2 R3 R4
1
441
50,69 TP
181, 205-231 TP
MBD
403 T

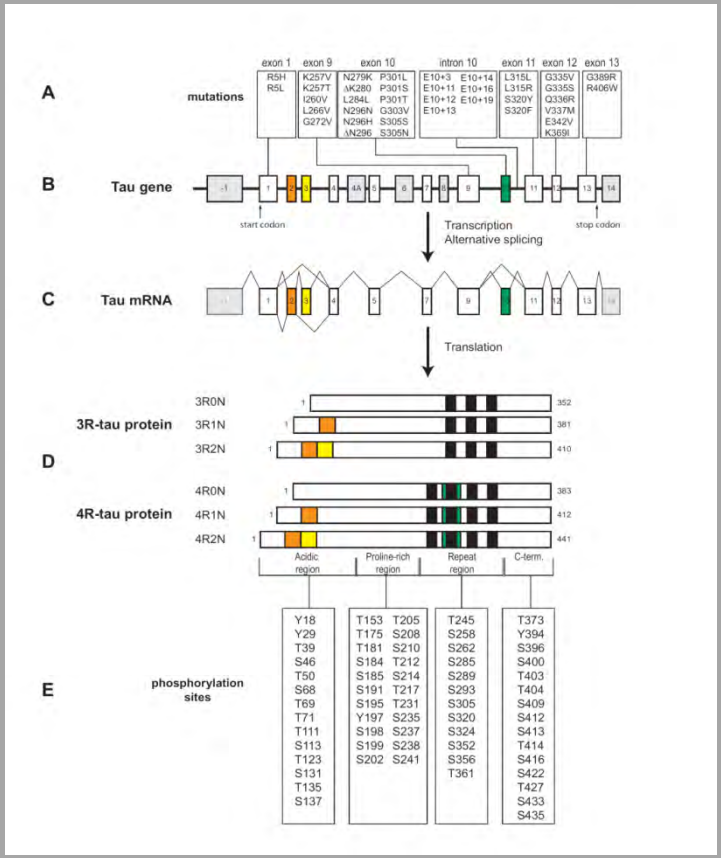
A
mutations
exon 1
exon 9
exon 10
intron 10
exon 11
exon 12
exon 13
R5H R5L
K257V K257T I260V L266V G272V
N279K ΔK280 L284L N296N N296H ΔN296
P301L P301S P301T G303V S305S S305N
E10+3 E10+11 E10+12 E10+13
E10+14 E10+16 E10+19
L315L L315R S320Y S320F
G335V G335S Q336R V337M E342V K369I
G389R R406W
B
Tau gene
start codon
stop codon
Transcription
Alternative splicing
C
Tau mRNA
Translation
D
3R-tau protein
3R0N
3R1N
3R2N
4R-tau protein
4R0N
4R1N
4R2N
352
381
410
383
412
441
Acidic region
Proline-rich region
Repeat region
C-term.
E
phosphorylation sites
Y18 Y29 T39 S46 T50 S68 T69 T71 T111 S113 T123 S131 T135 S137
T153 T175 T181 S184 S185 S191 S195 Y197 S198 S199 S202
T205 S208 S210 T212 S214 T217 T231 S235 S237 S238 S241
T245 S258 S262 S285 S289 S293 S305 S320 S324 S352 S356 T361
T373 Y394 S396 S400 T403 T404 S409 S412 S413 T414 S416 S422 T427 S433 S435

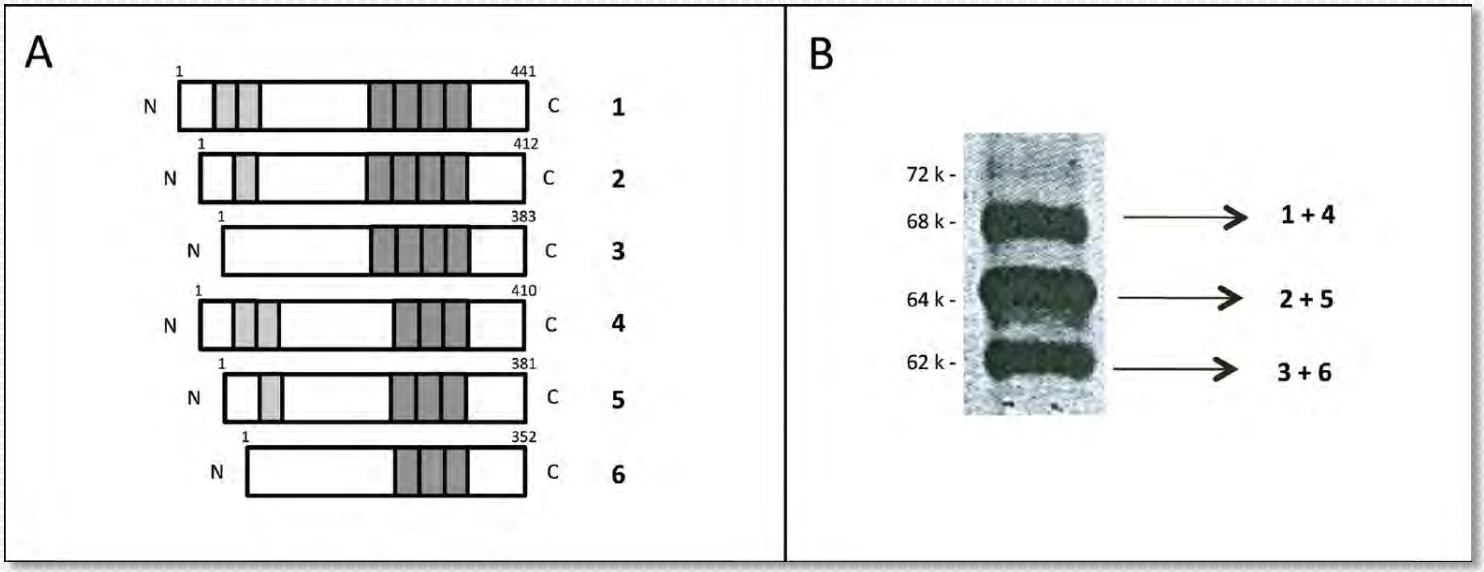
A
1
441
N
C
1
1
412
N
C
2
1
383
N
C
3
1
410
N
C
4
1
381
N
C
5
1
352
N
C
6
B
72 k -
68 k -
64 k -
62 k -
1 + 4
2 + 5
3 + 6

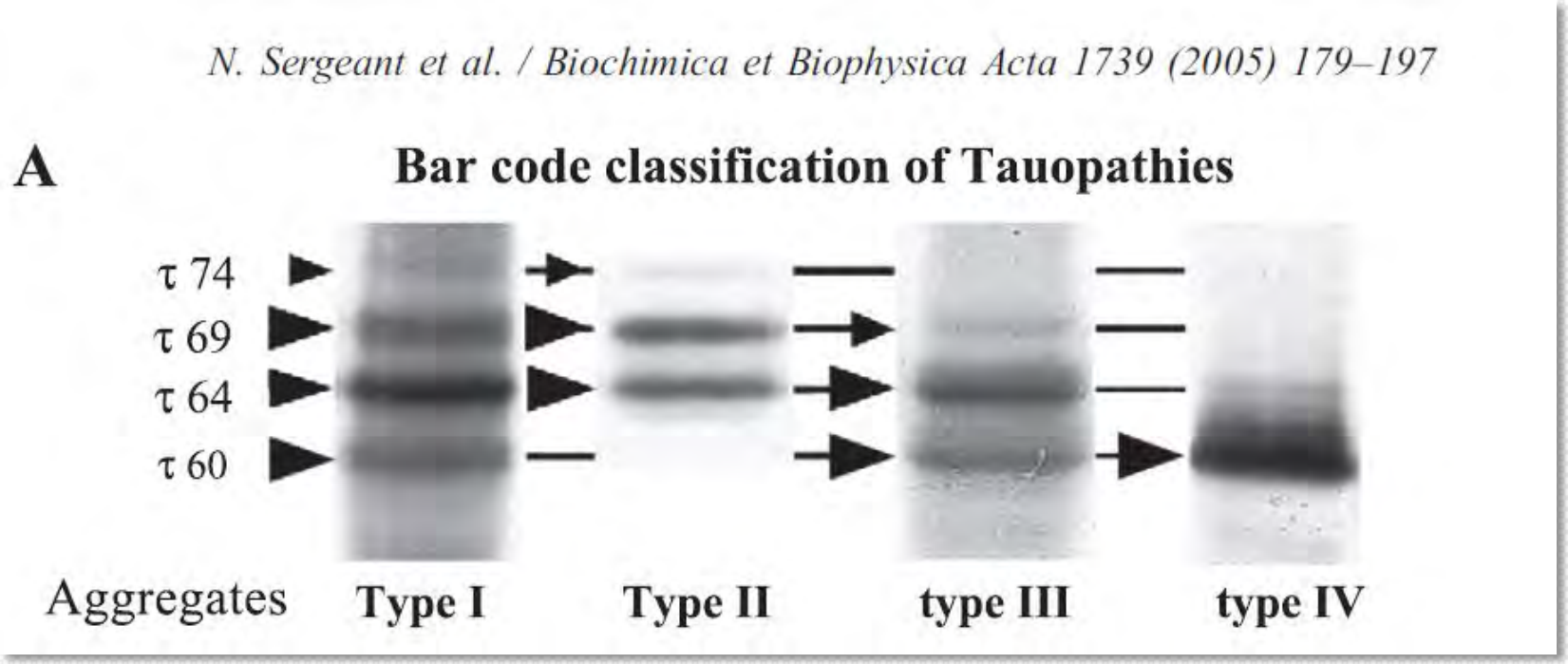
N. Sergeant et al. / Biochimica et Biophysica Acta 1739 (2005) 179–197
A
Bar code classification of Tauopathies
τ 74
τ 69
τ 64
τ 60
Aggregates
Type I
Type II
type III
type IV

ENTIDAD	SÍNDROME	REGIONES AFECTADAS	TAU
ENFERMEDAD DE PICK (EP)	Demencia	Córtex cerebral Ganglios basales	**3R**
PARÁLISIS SUPRANUCLEAR PROGRESIVA (PSP)	Parkinsonismo	Ganglios basales Tronco cerebral	**4R**
DEGENERACIÓN CÓRTICOBASAL (DCB)	Parkinsonismo Demencia	Ganglios basales Córtex cerebral	**4R**
ENFERMEDAD DE GRANOS ARGIRÓFILOS (EGA)	Demencia Trastorno de conducta	Córtex límbico	**4R**
DEMENCIA FRONTOTEMPORAL CON INCLUSIONES TAU (+) (DFT-TAU)	Demencia Parkinsonismo	Córtex cerebral Ganglios basales	**3R** **4R** **3R & 4R**
DEMENCIA CON OVILLOS NEUROFIBRILARES (DON)	Demencia	Córtex cerebral	**3R & 4R**

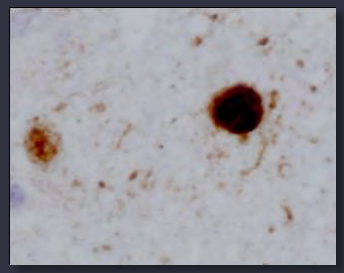

Cuerpo de Pick

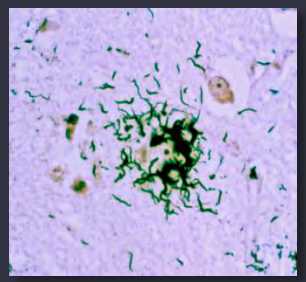

Astrocito en penacho

'coiled body'

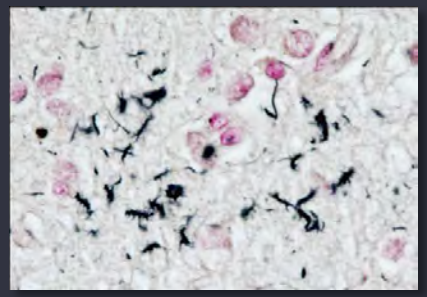

Placa astrocitaria

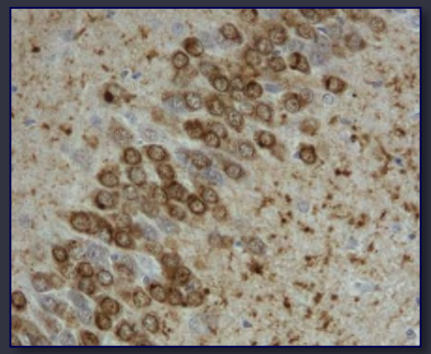

Neuronas tau (+), giro dentado

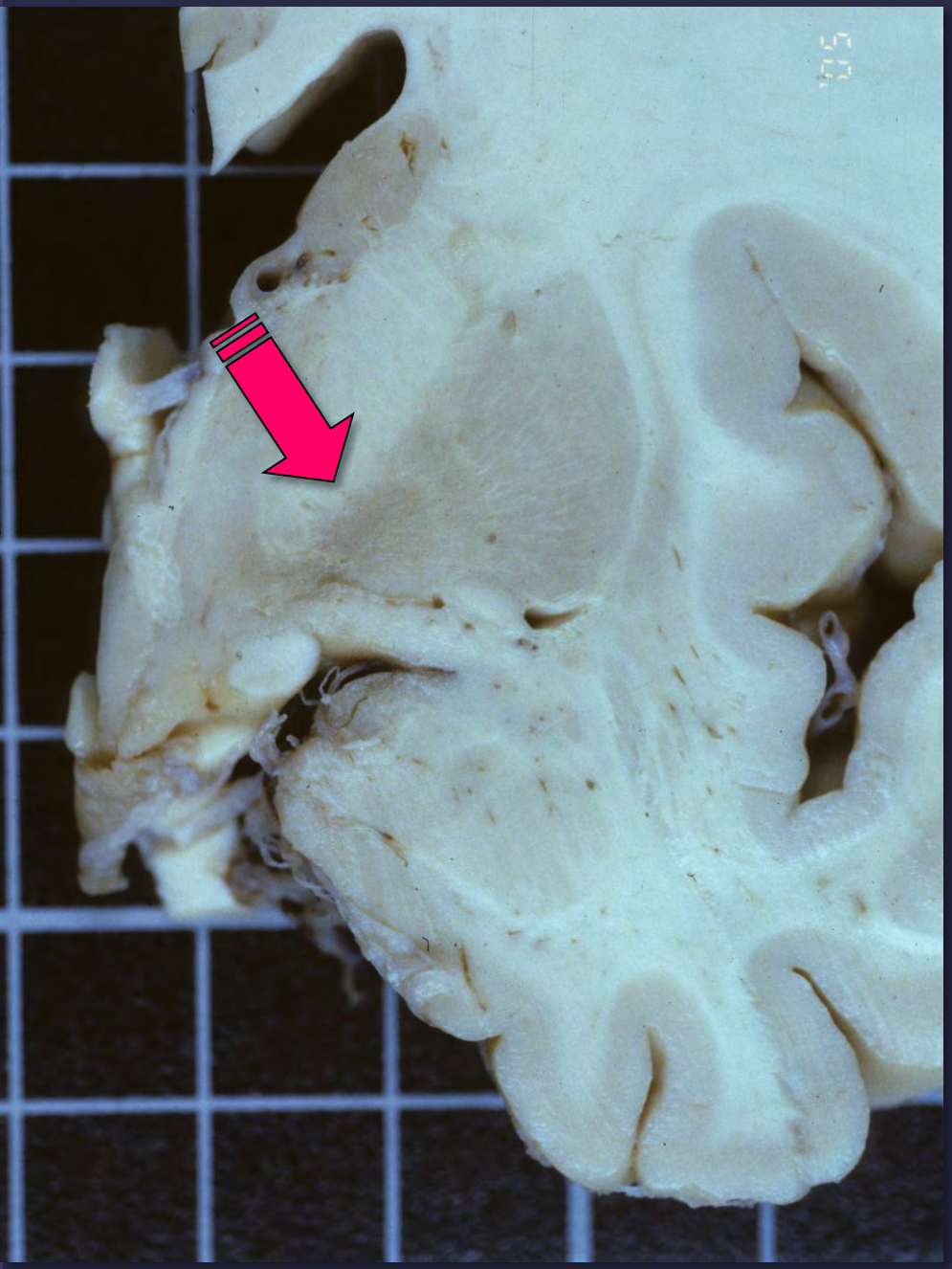

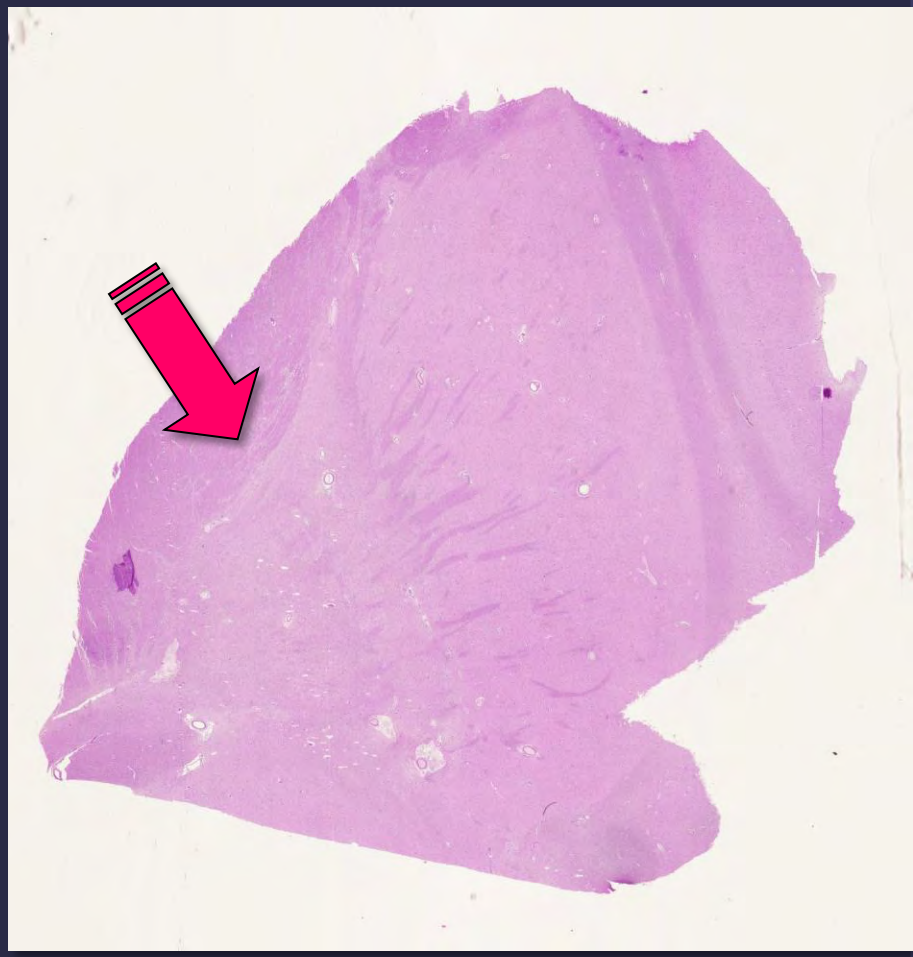

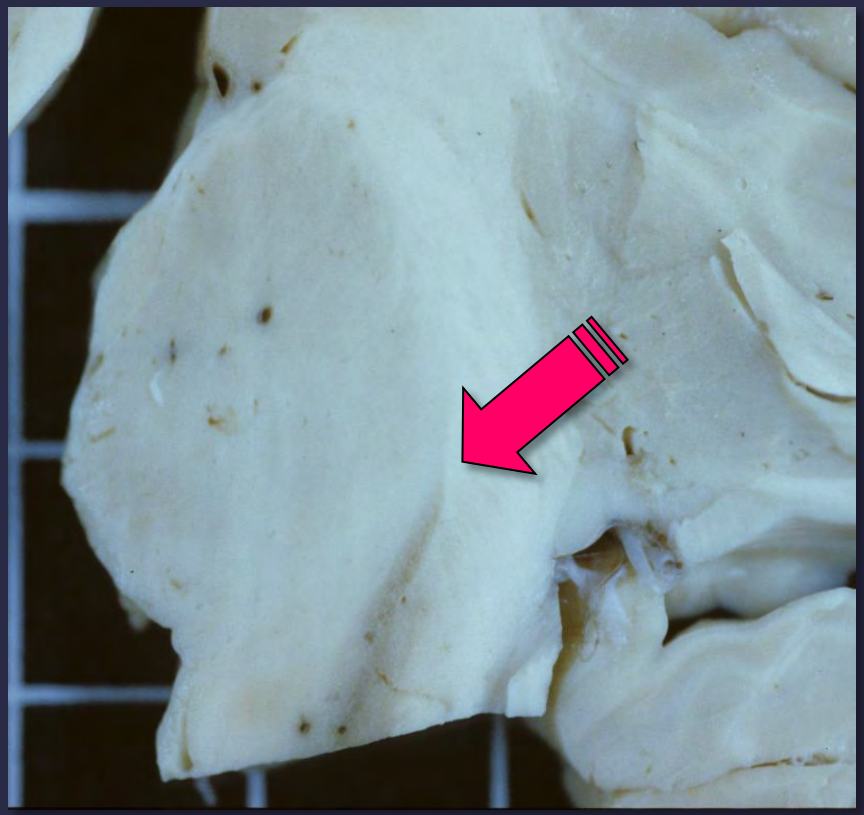

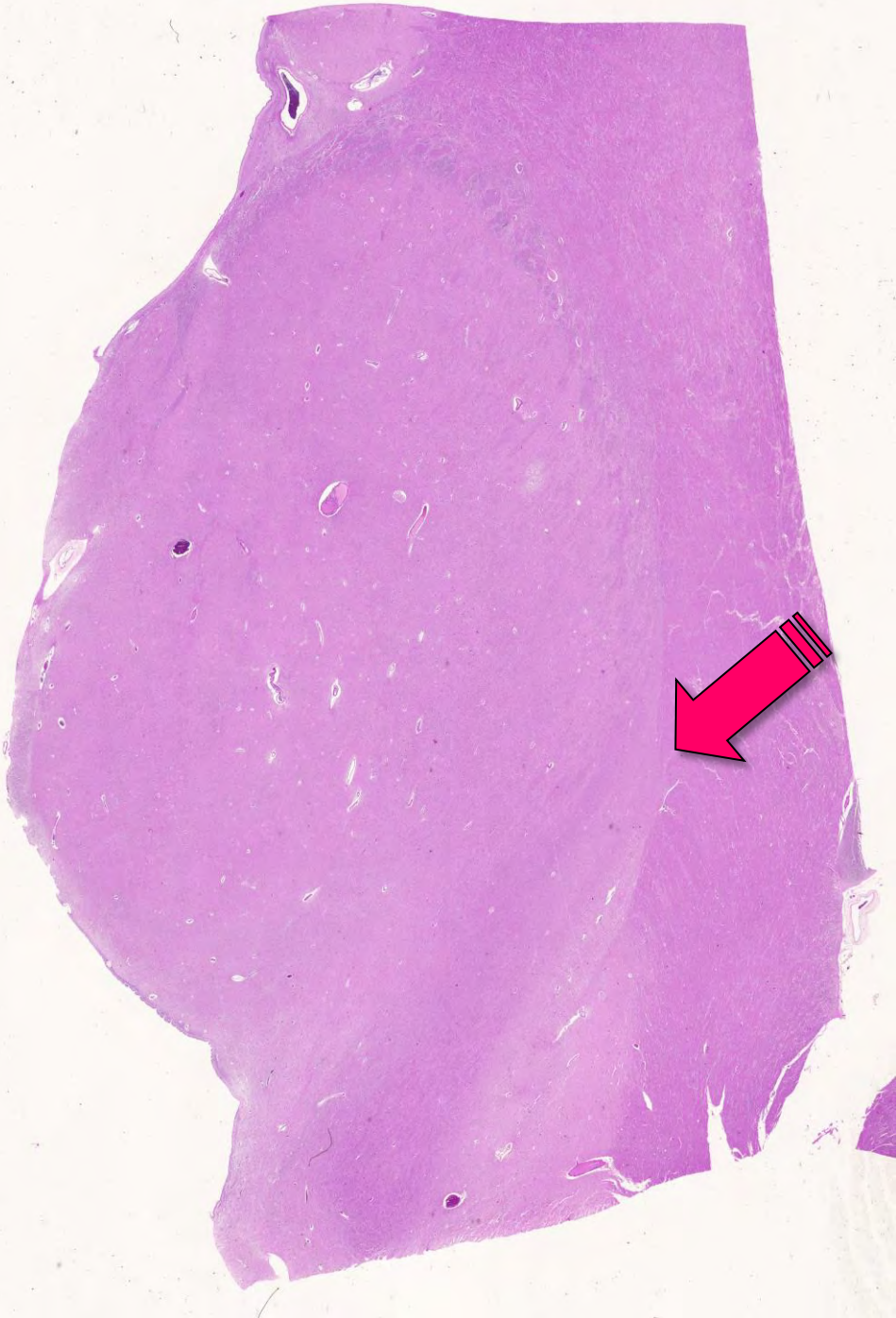

Parálisis supranuclear progresiva – demencia frontotemporal

Cx frontal
Tau AT100

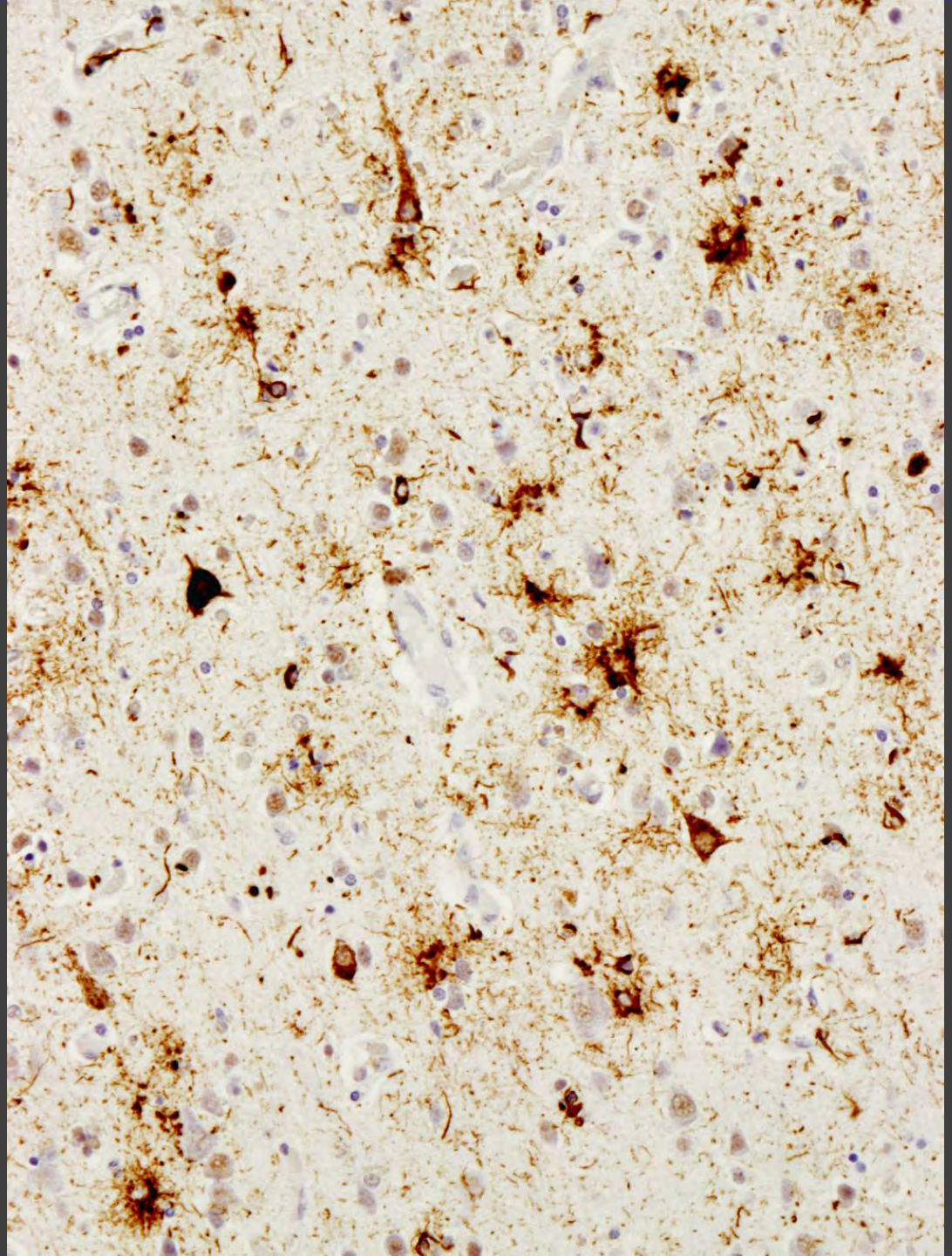

INCLUSIONES TAU (+):

Astrocitos en penacho
"tufted astrocytes"

Ovillos globoides

Preovillos

Inclusiones
oligodendrogliales
"coiled bodies"

Hebras neuropílicas

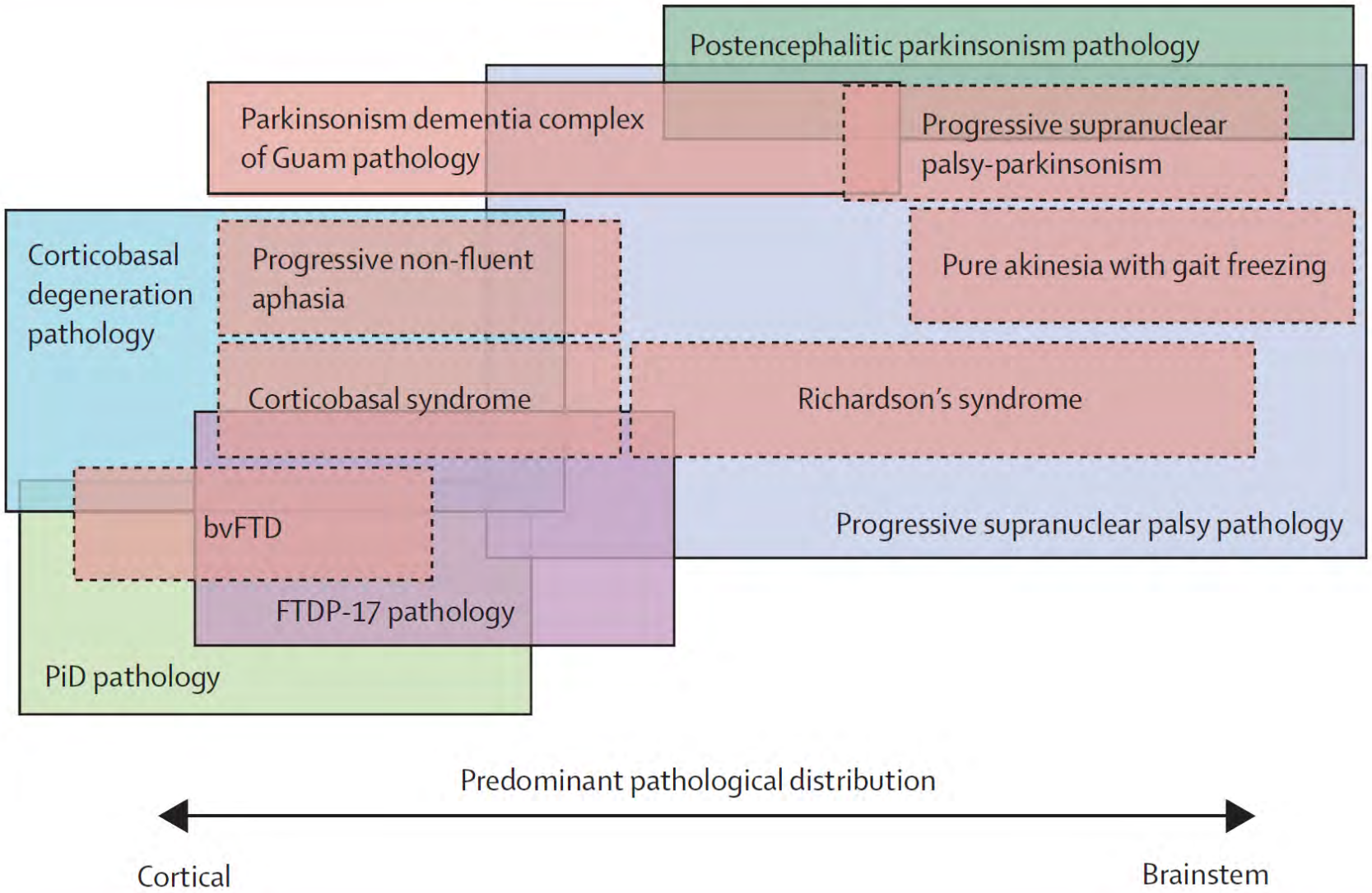

Williams RD, Lees AJ. Progressive supranuclear palsy: clinicopathological concepts and diagnostic challenges. *Lancet Neurol* 2009; 8: 270–79

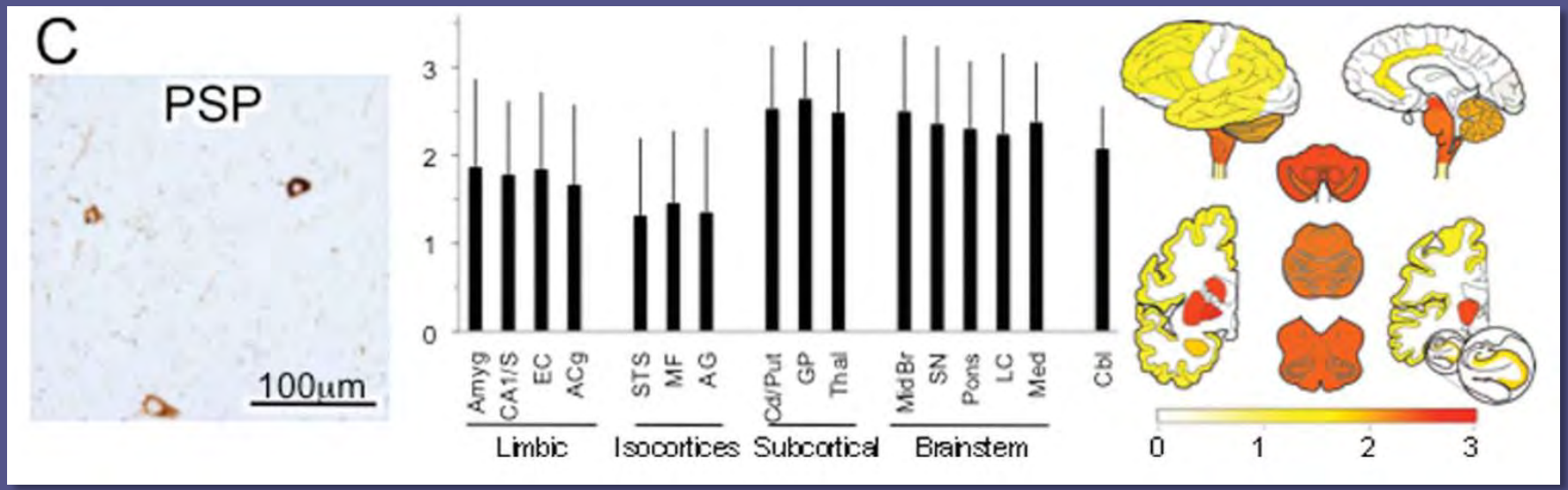
C
PSP
100µm
3
2
1
0
Amyg
CA1/S
EC
ACg
STS
MF
AG
Cd/Put
GP
Thal
MidBr
SN
Pons
LC
Med
Cbl
Limbic
Isocortices
Subcortical
Brainstem
0
1
2
3

Izquierdo
fijado

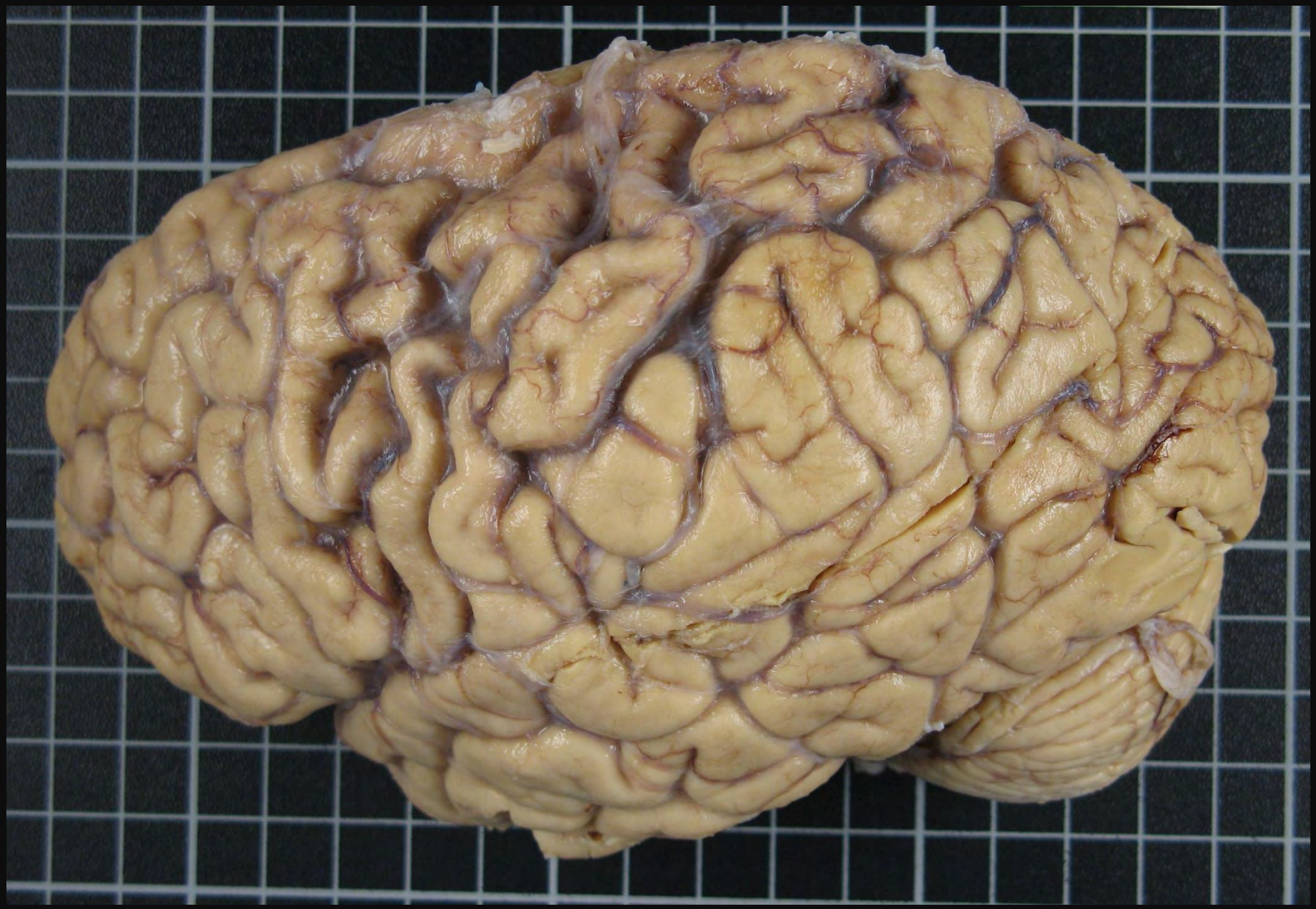

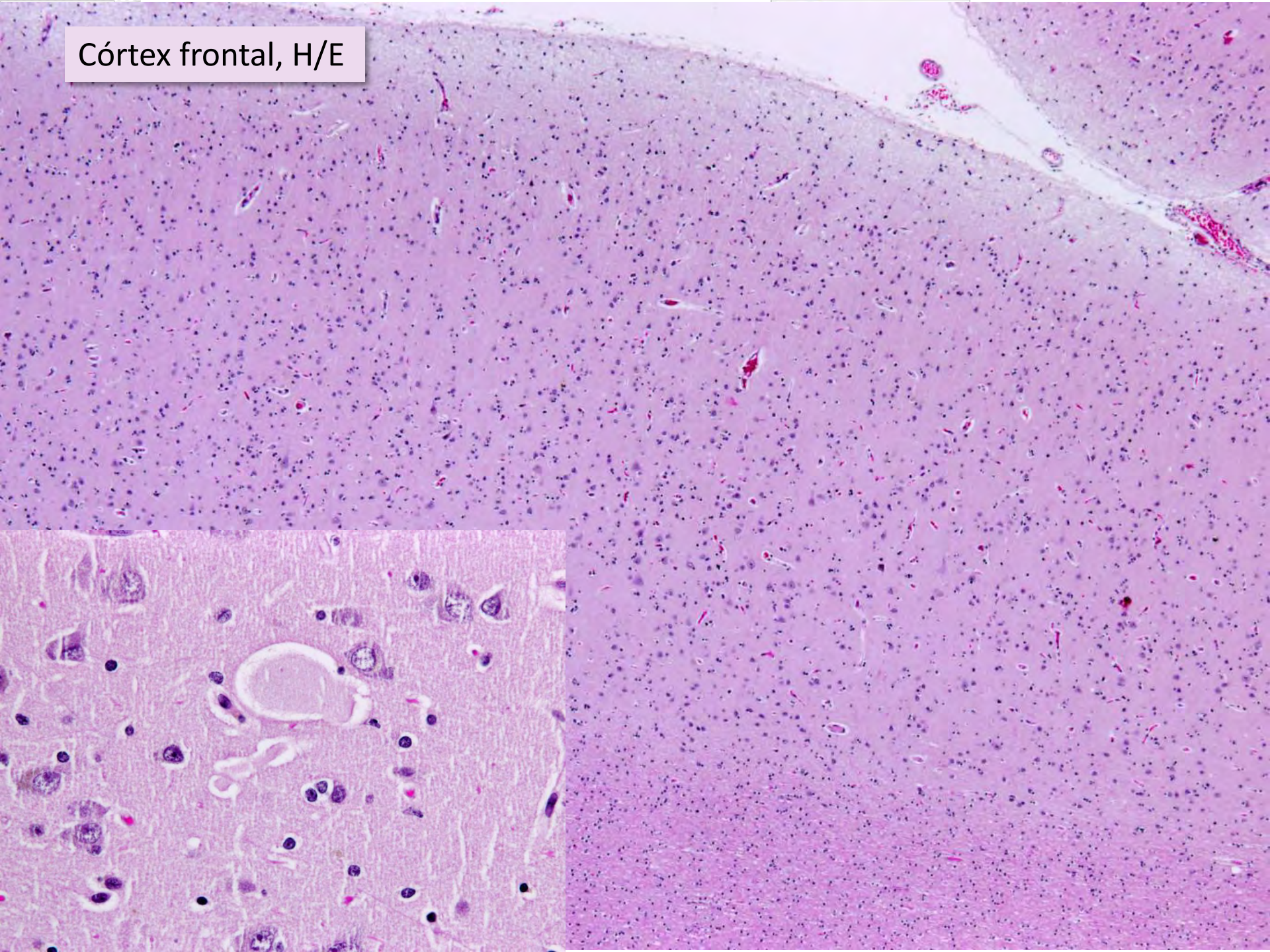
Córtex frontal, H/E

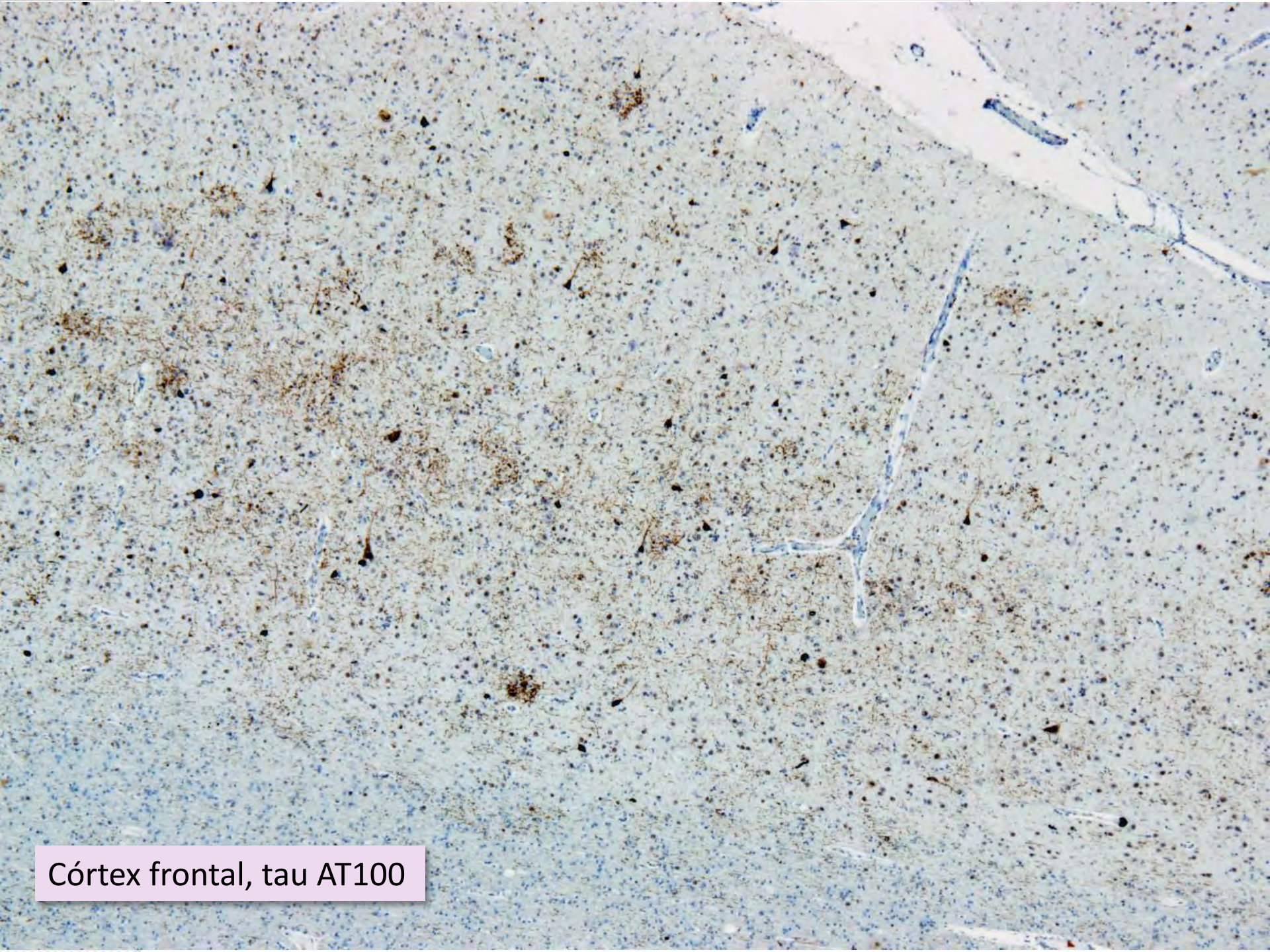
Córtex frontal, tau AT100

Córtex frontal, tau AT100

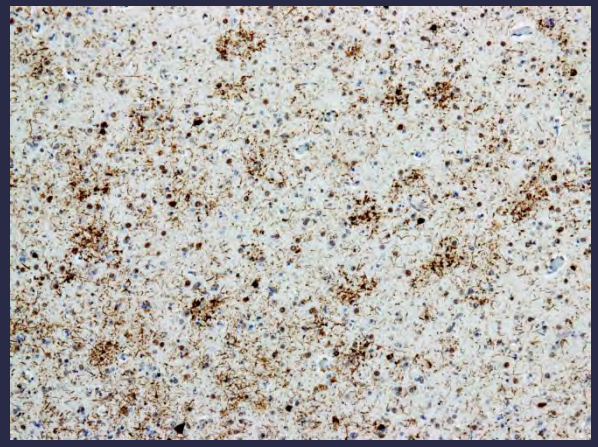

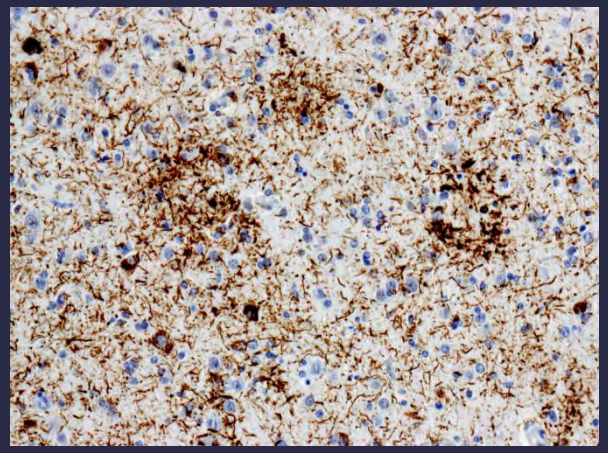

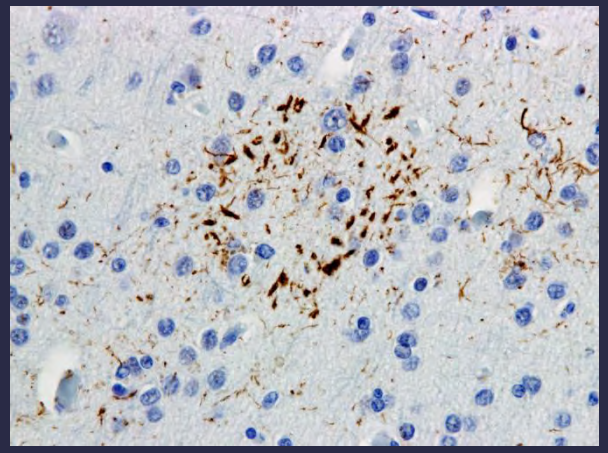

Degeneración córticobasal

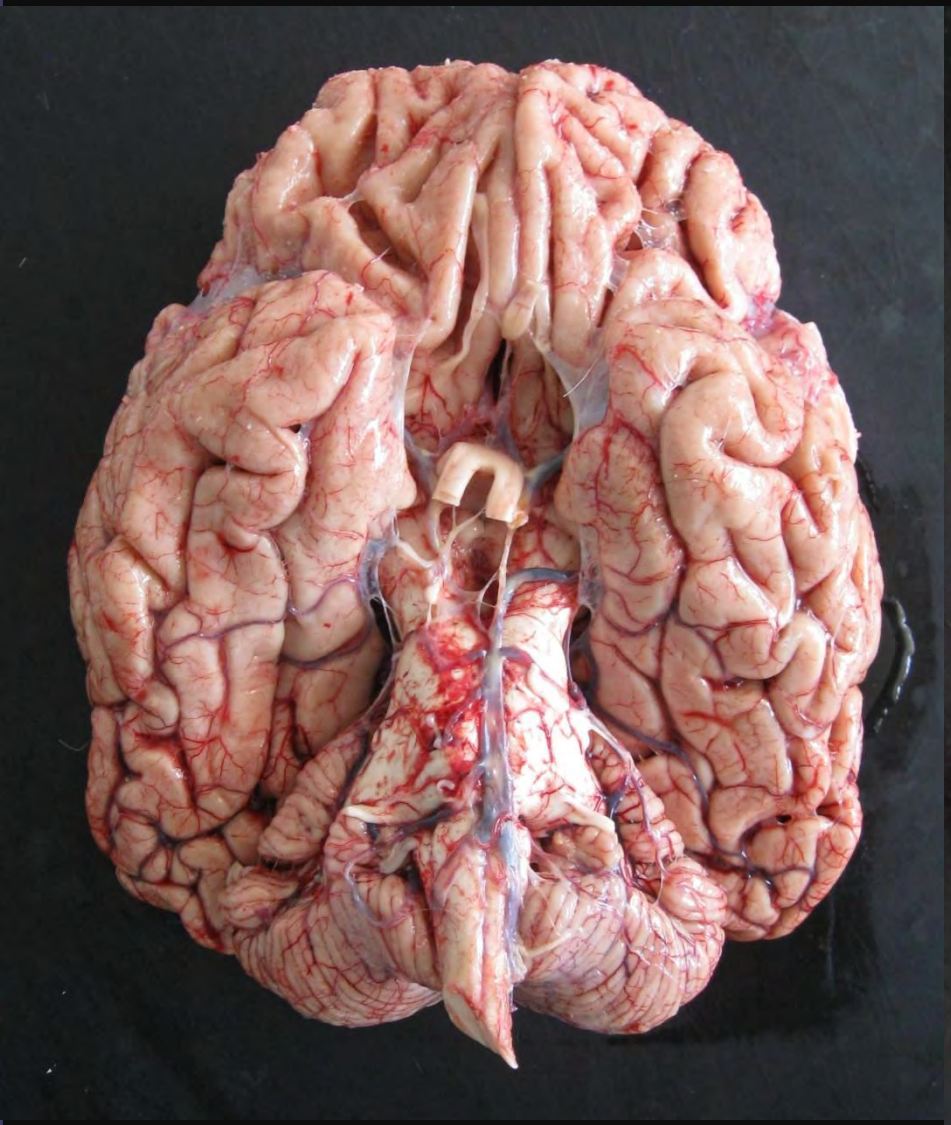

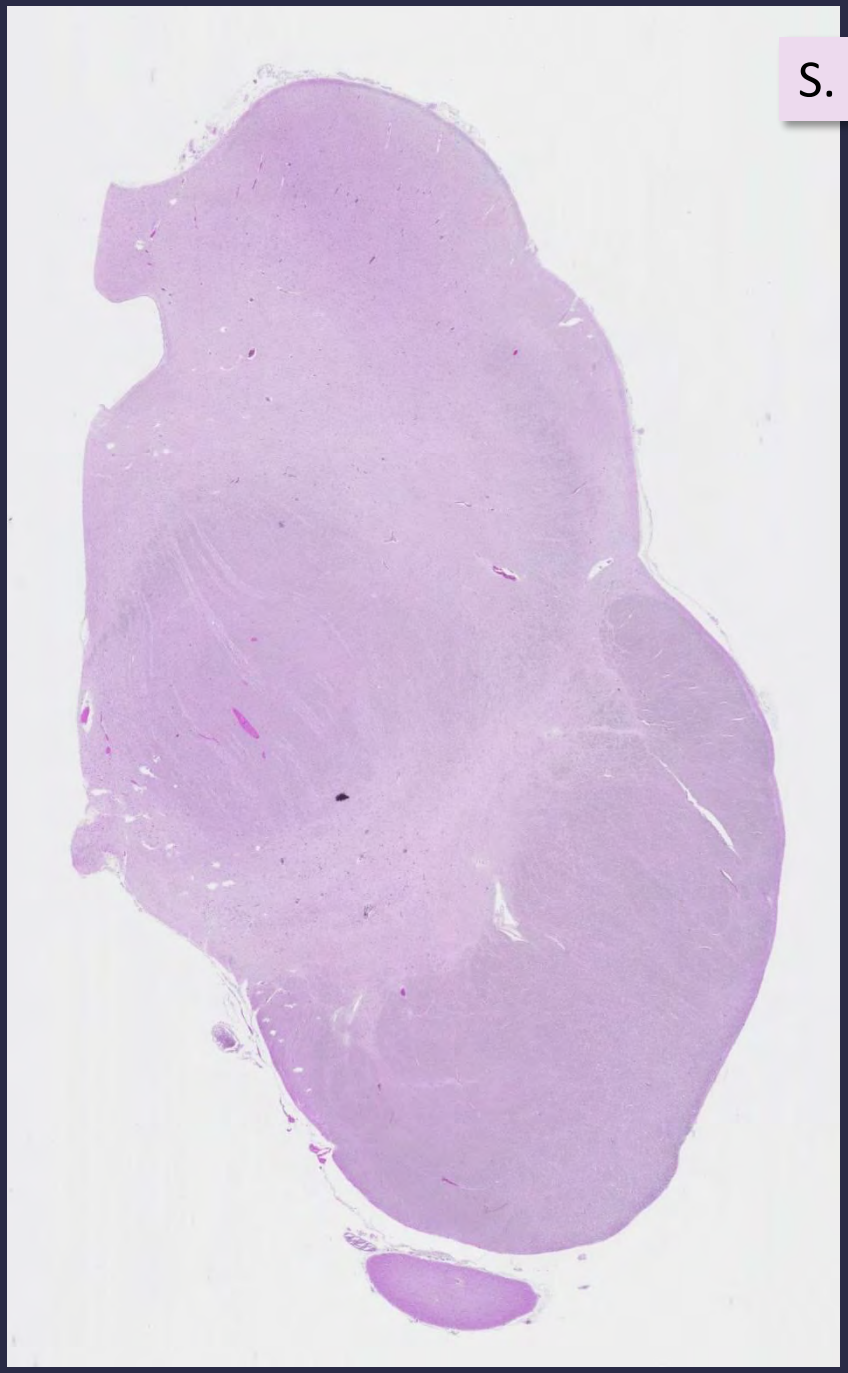

S. nigra, H/E

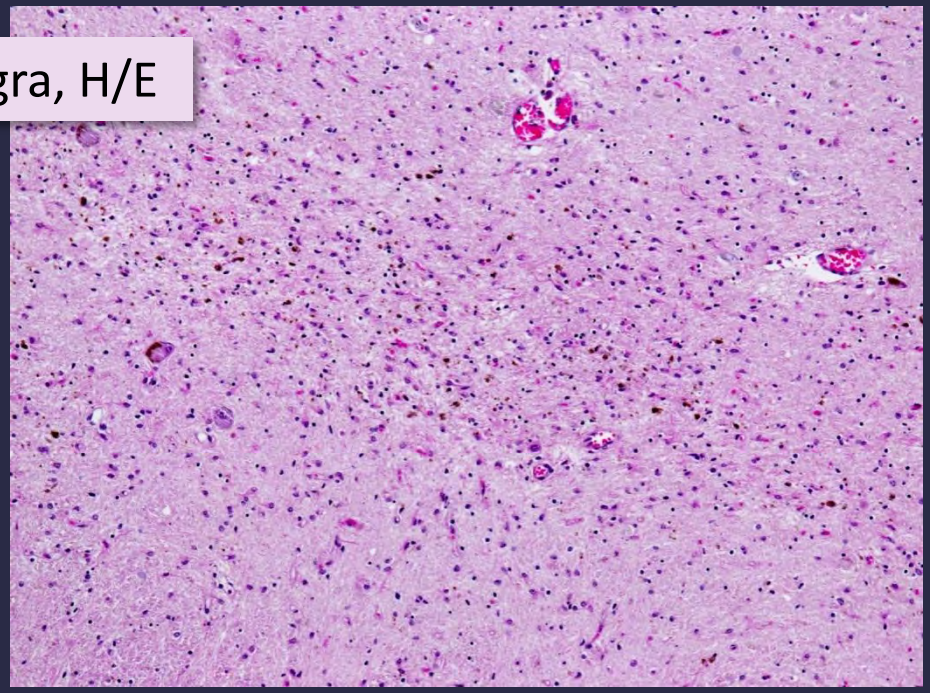

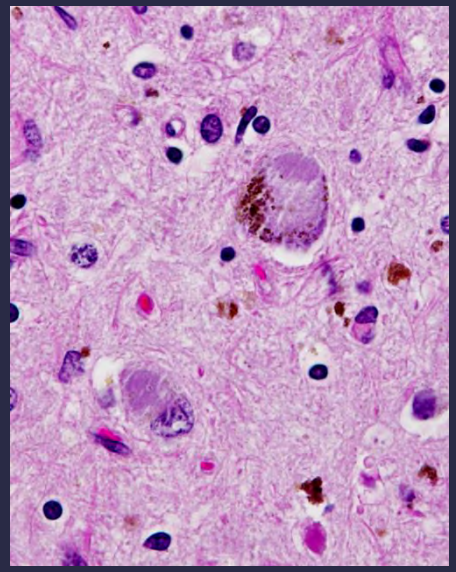

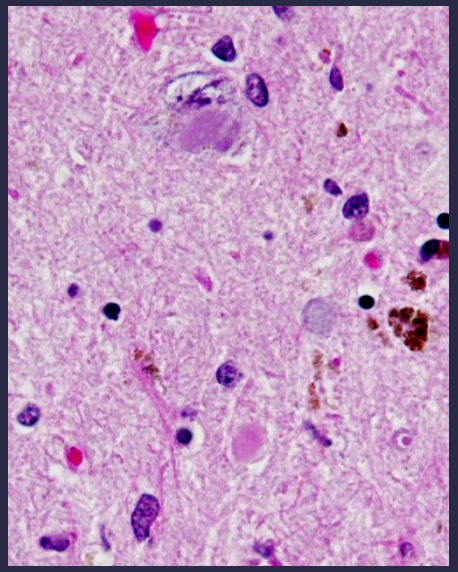

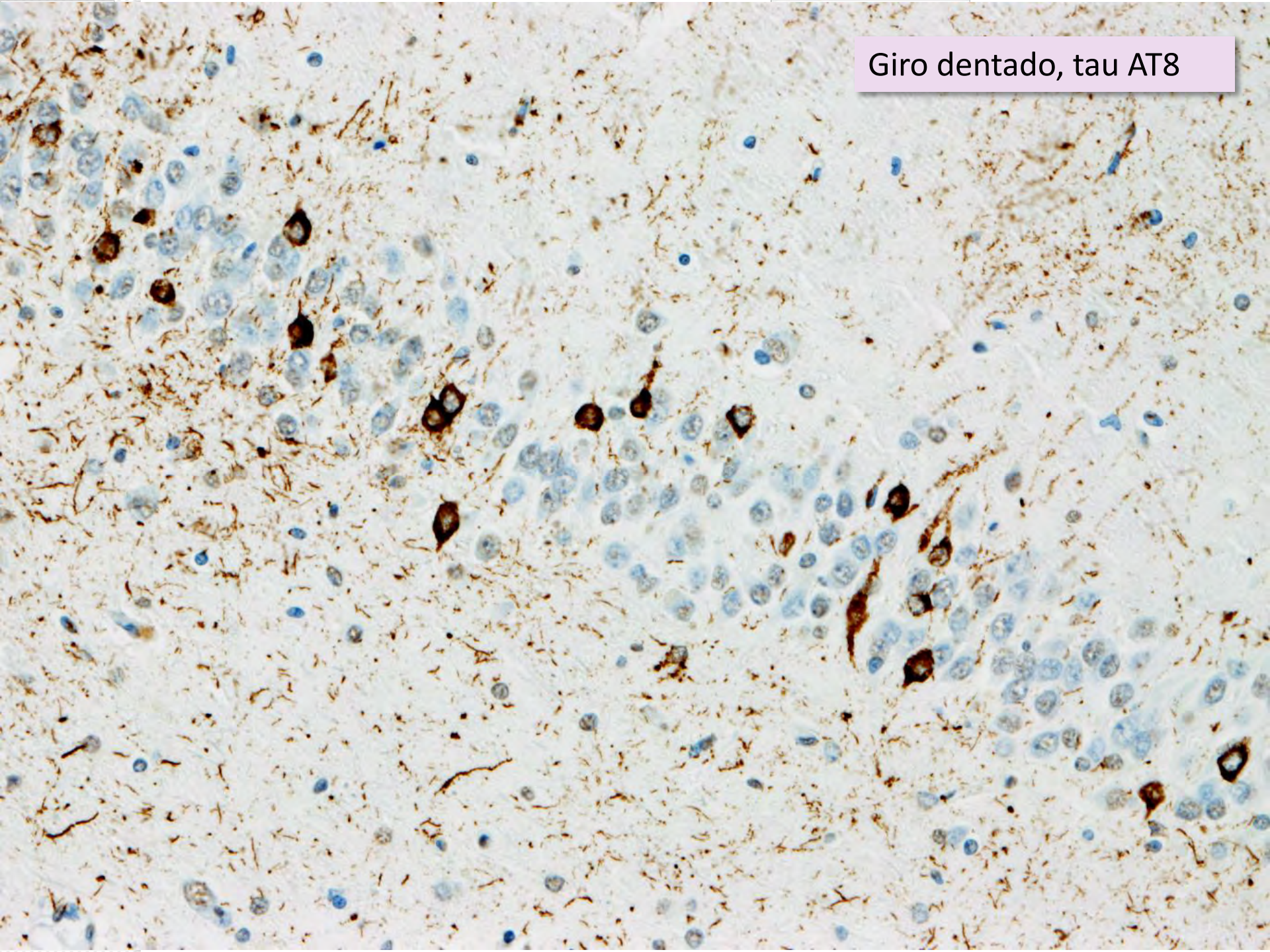
Giro dentado, tau AT8

Perfil lesional

Región cerebral	P. neuronal/ Gliosis	Neuronas balonizadas	Patología tau (+)	Patología alfa-sin (+)
Córtex frontal (CERAD)				
Córtex órbito-frontal				
Córtex cingular				
Córtex motor primario				
Córtex parietal (CERAD)				
Córtex temporal (CERAD)				
Córtex temporal inferior				
Córtex insular				
Córtex occipital lateral				
Córtex visual primario				
Amígdala				
Córtex entorrinal				
Hipocampo CA				
Hipocampo GD				
Caudado-putamen				
Globus pallidus				
N. basalis de Meynert				
Hipotálamo				
Tálamo				
Subtalámico				
Núcleo rojo				
S. gris periacueductal				
S. nigra compacta				
Tegmento pontino				
Base pontina				
Bulbo				
Córtex cerebeloso				
N. dentado				

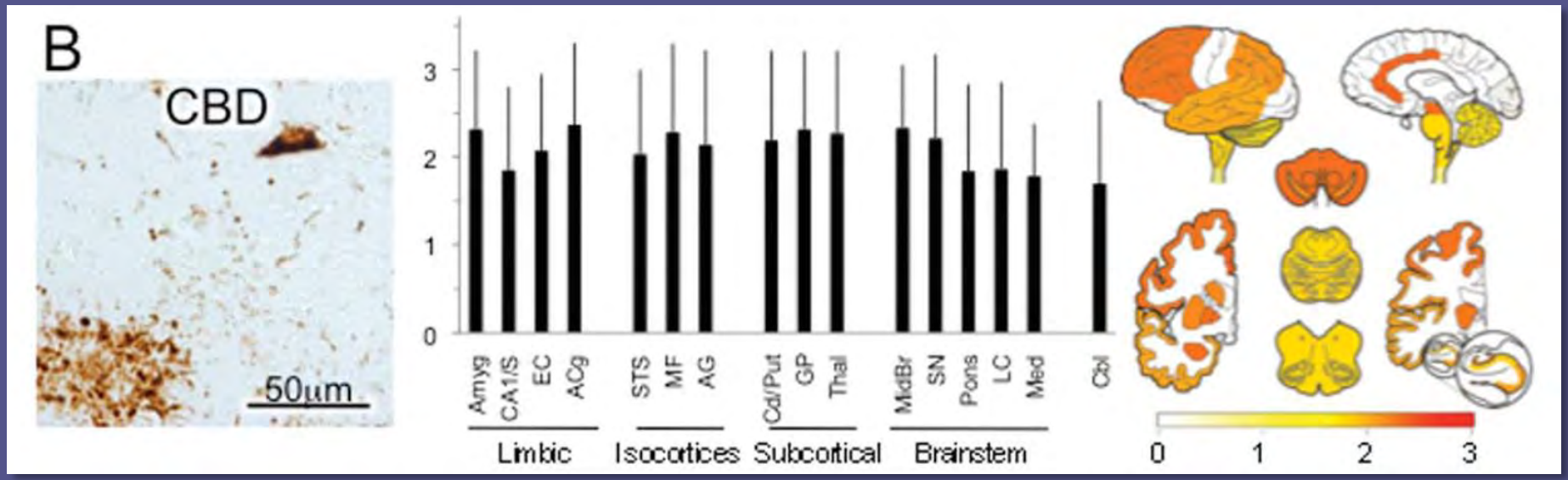
B
CBD
50μm
3
2
1
0
Amyg
CA1/S
EC
ACg
STS
MF
AG
Cd/Put
GP
Thal
MidBr
SN
Pons
LC
Med
Cbl
Limbic
Isocortices
Subcortical
Brainstem
0
1
2
3

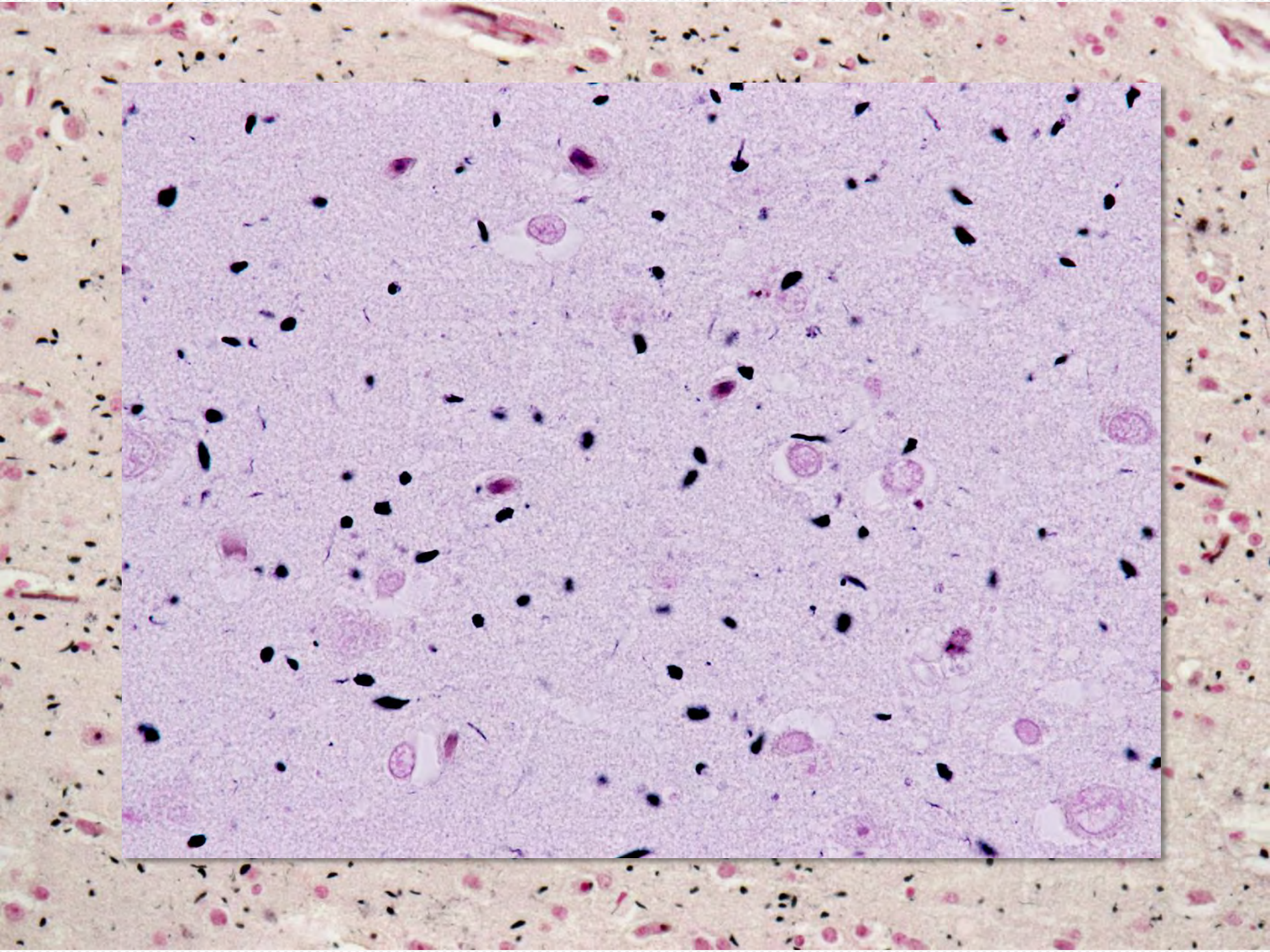

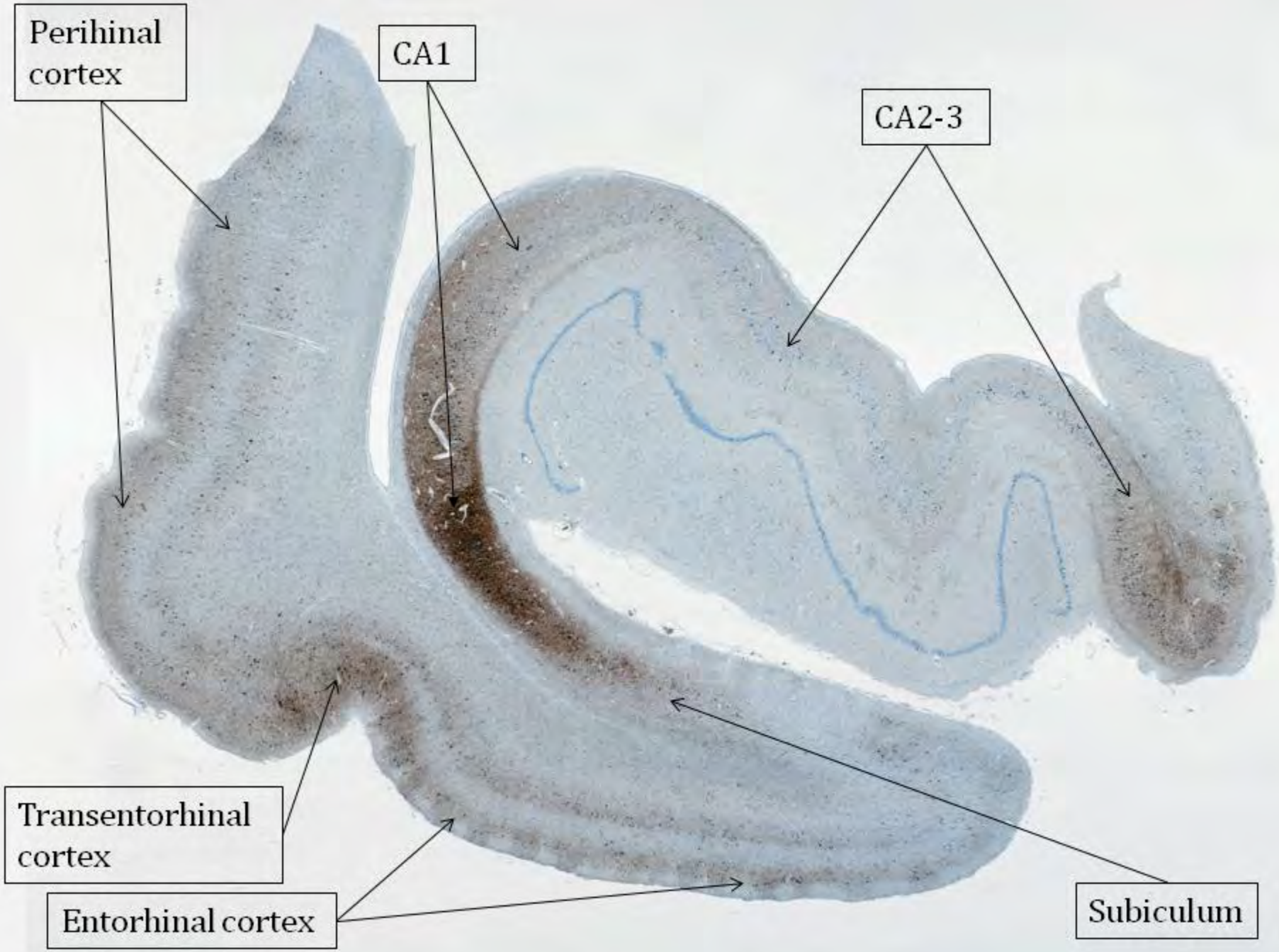
Perihinal cortex
CA1
CA2-3
Transentorhinal cortex
Entorhinal cortex
Subiculum

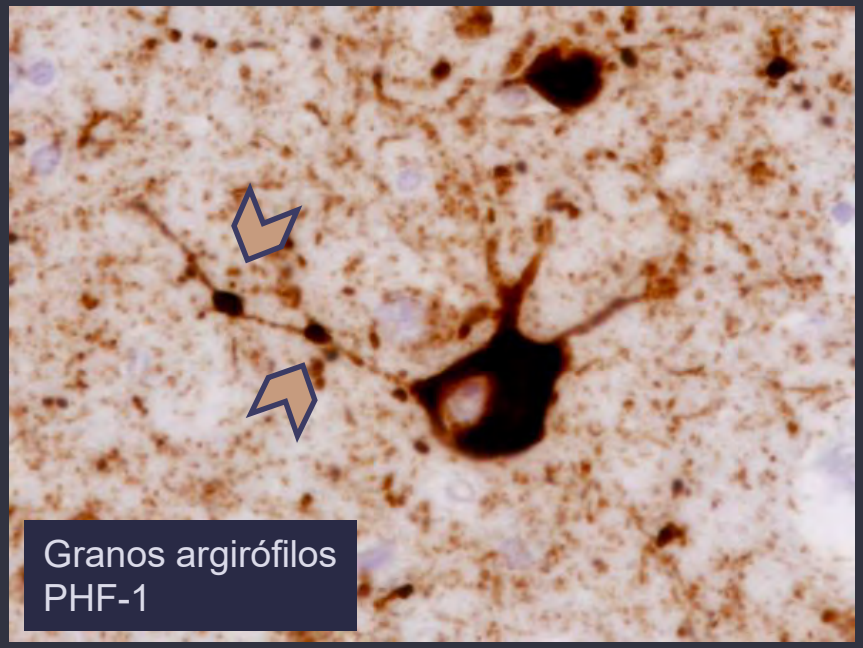
Granos argirófilos
PHF-1

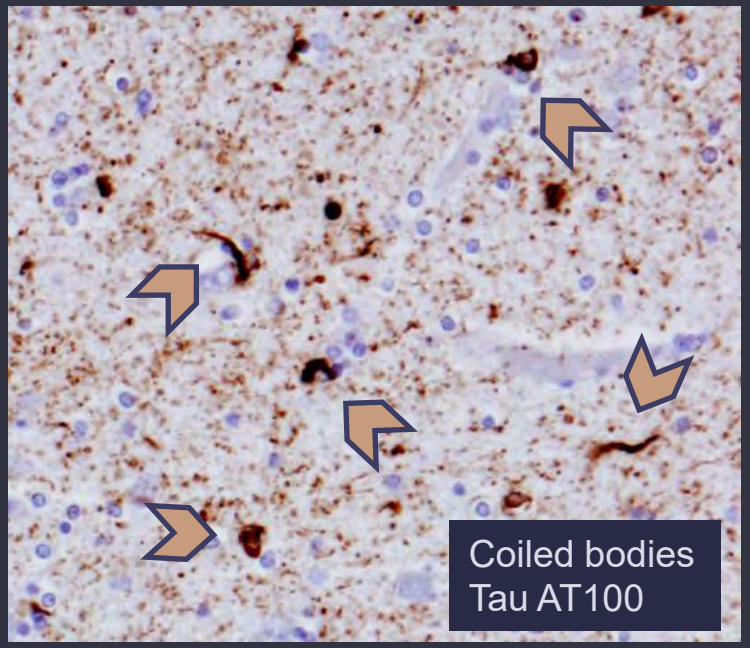
Coiled bodies
Tau AT100

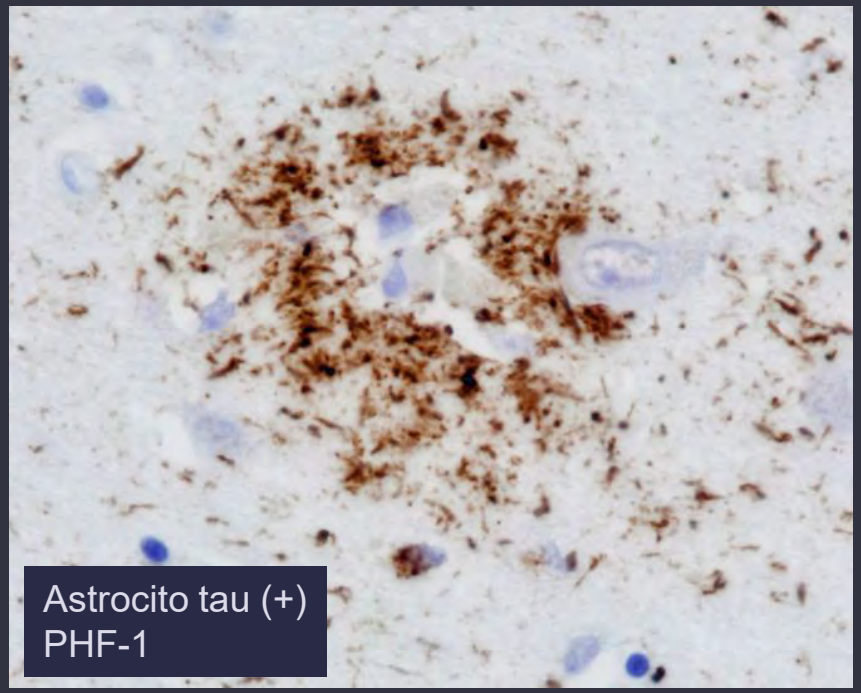
Astrocito tau (+)
PHF-1

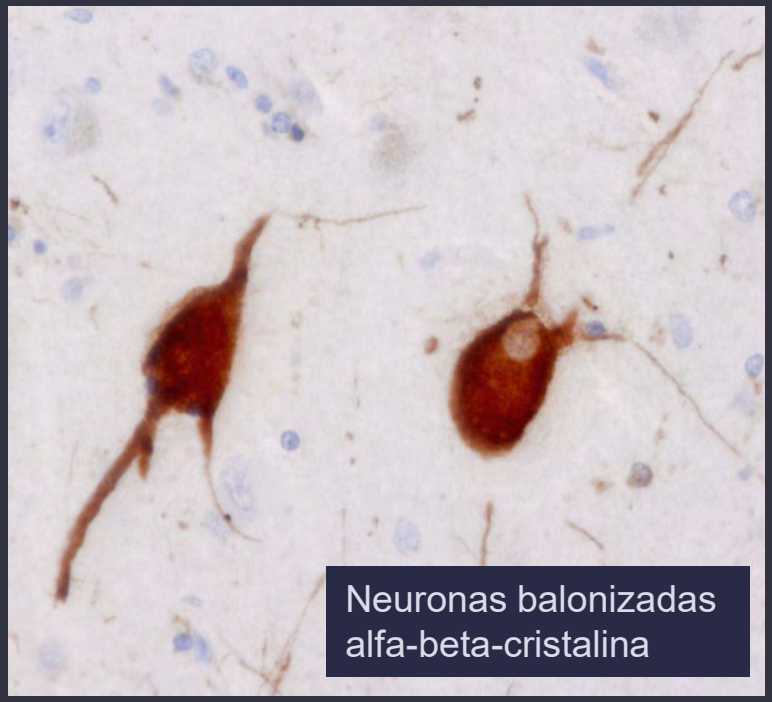
Neuronas balonizadas
alfa-beta-cristalina

A
B
C
*
*
*

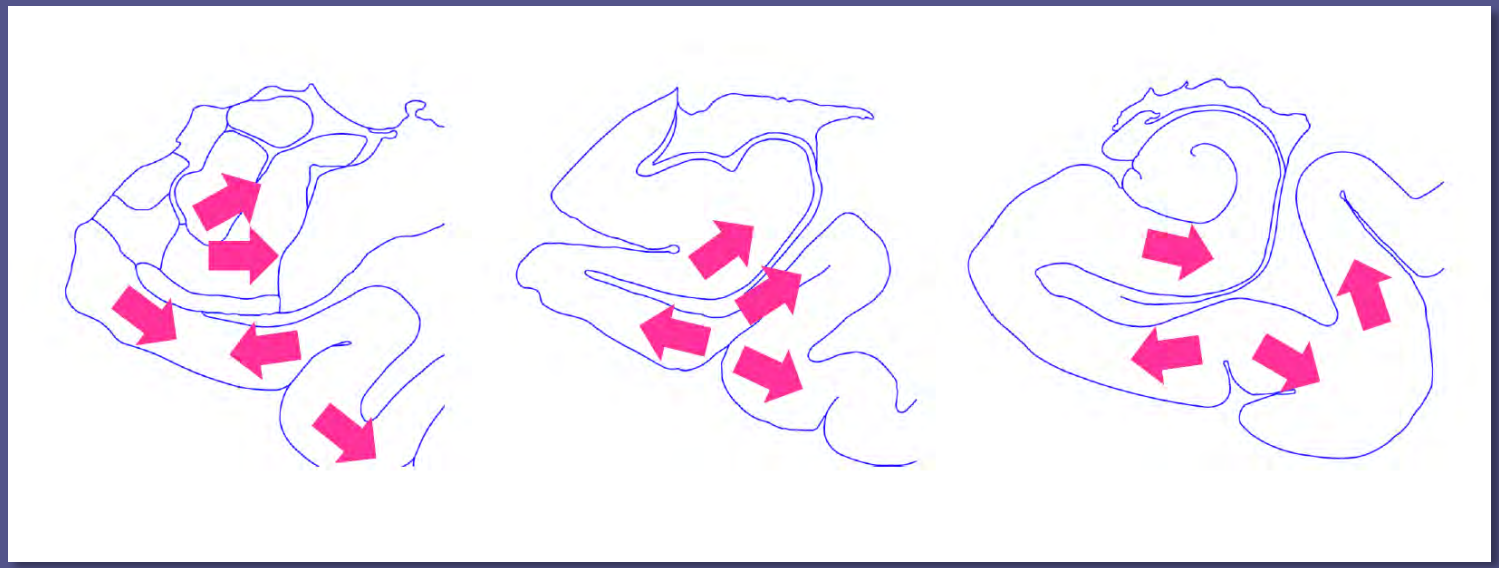

Enfermedad de Pick

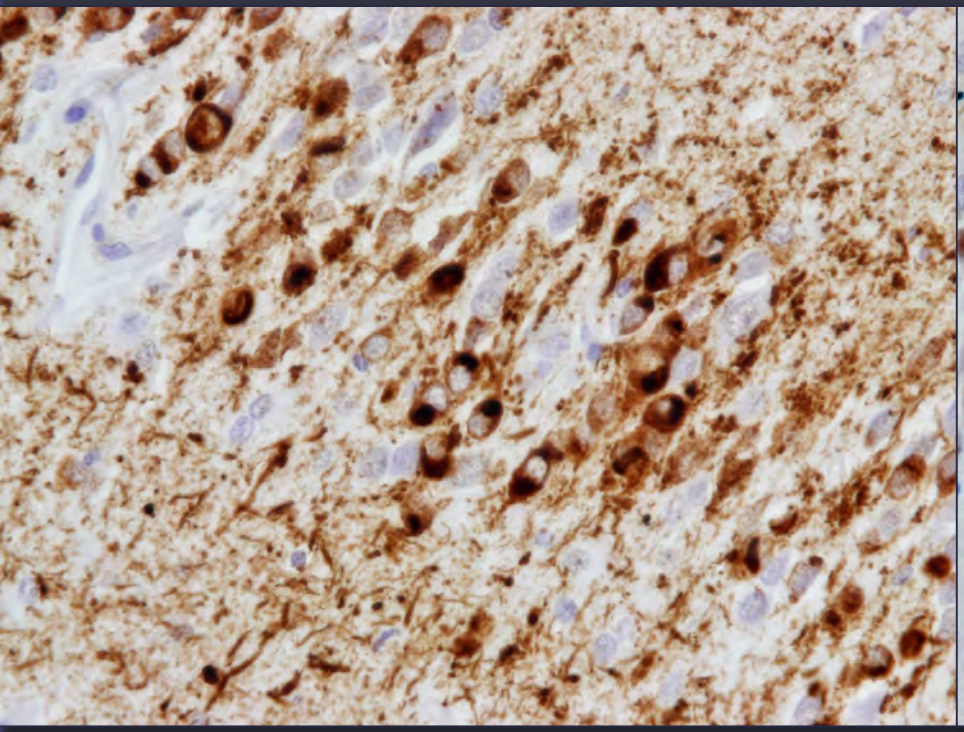

Tau

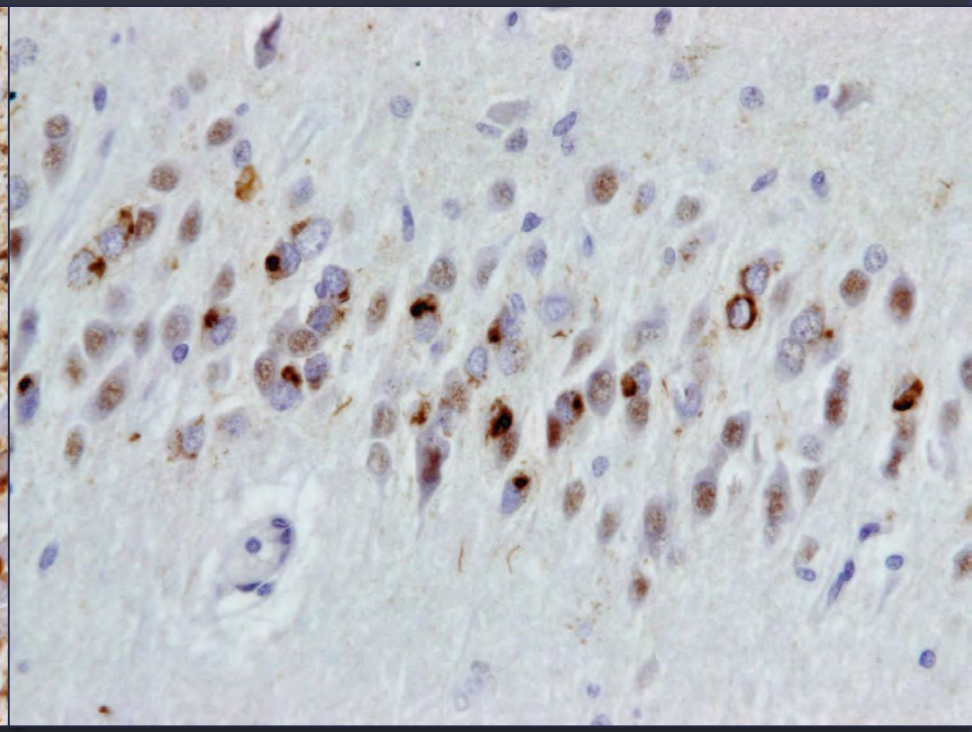

TDP-43

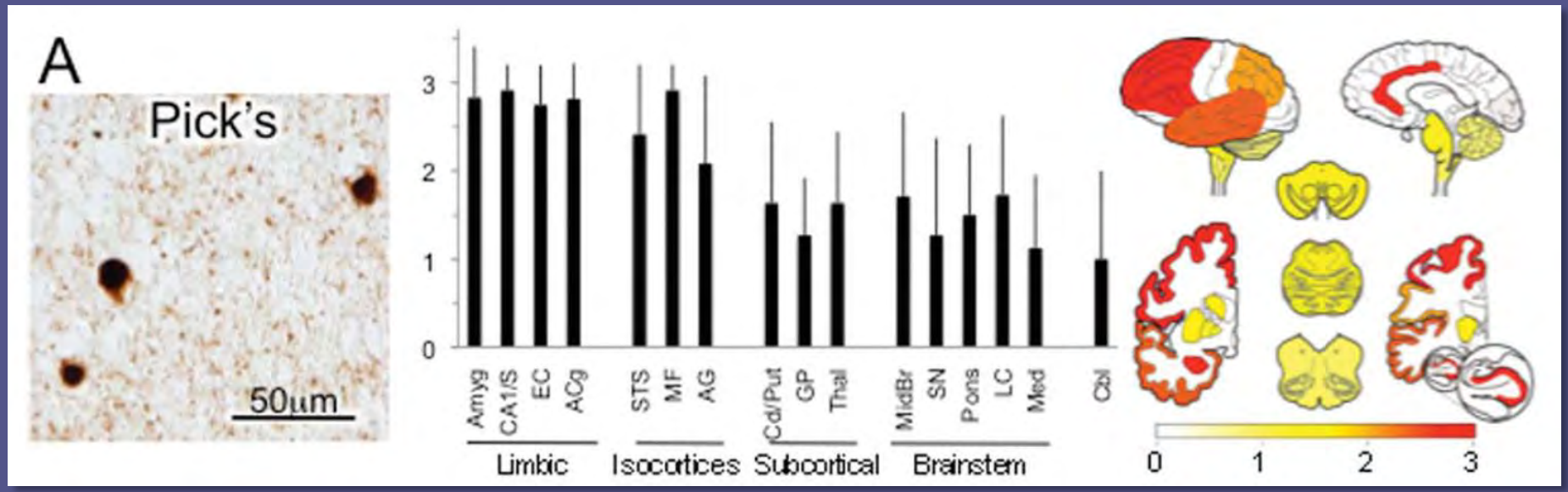
A
Pick's
50µm
3
2
1
0
Amyg
CA1/S
EC
ACg
STS
MF
AG
Cd/Put
GP
Thal
MidBr
SN
Pons
LC
Med
Cbl
Limbic
Isocortices
Subcortical
Brainstem
0
1
2
3

Patología TDP

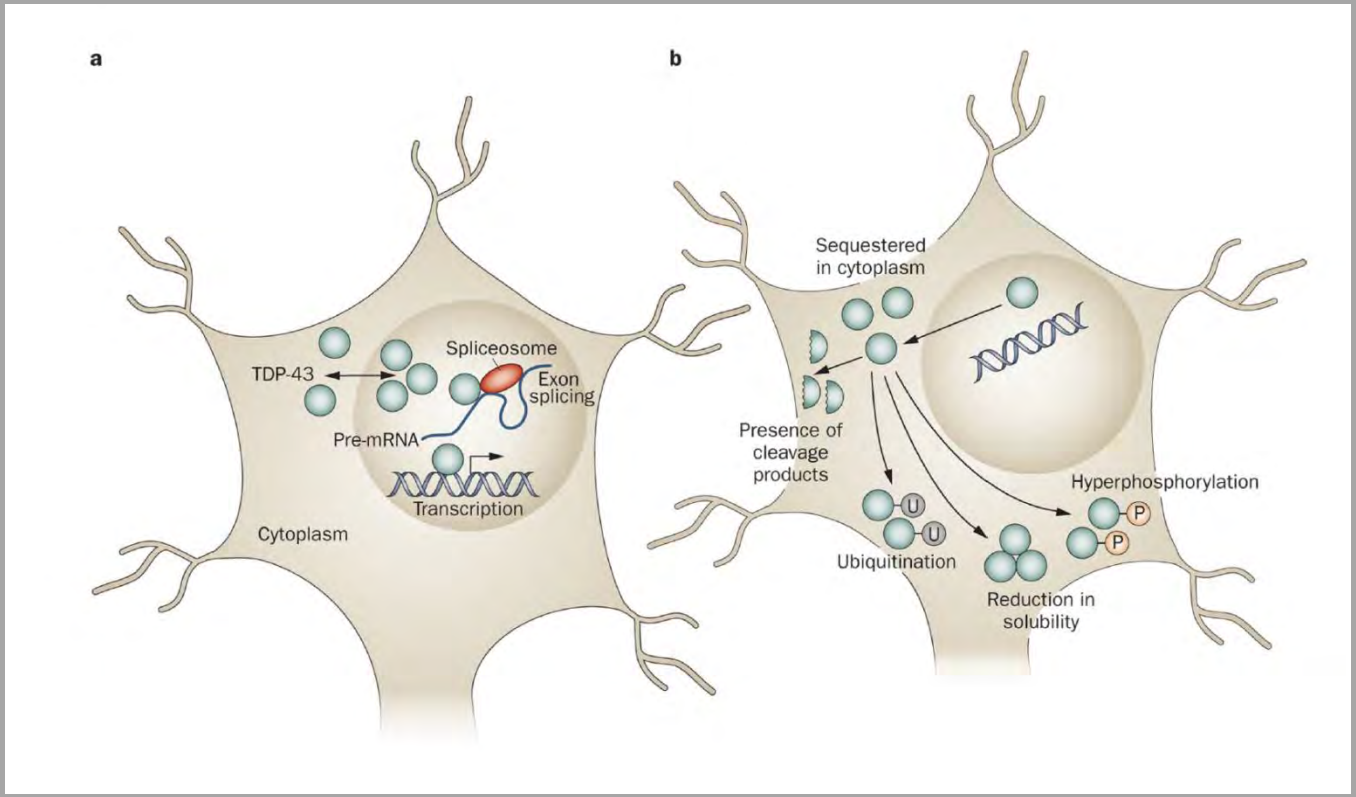

Degeneración lobar frontotemporal TDP

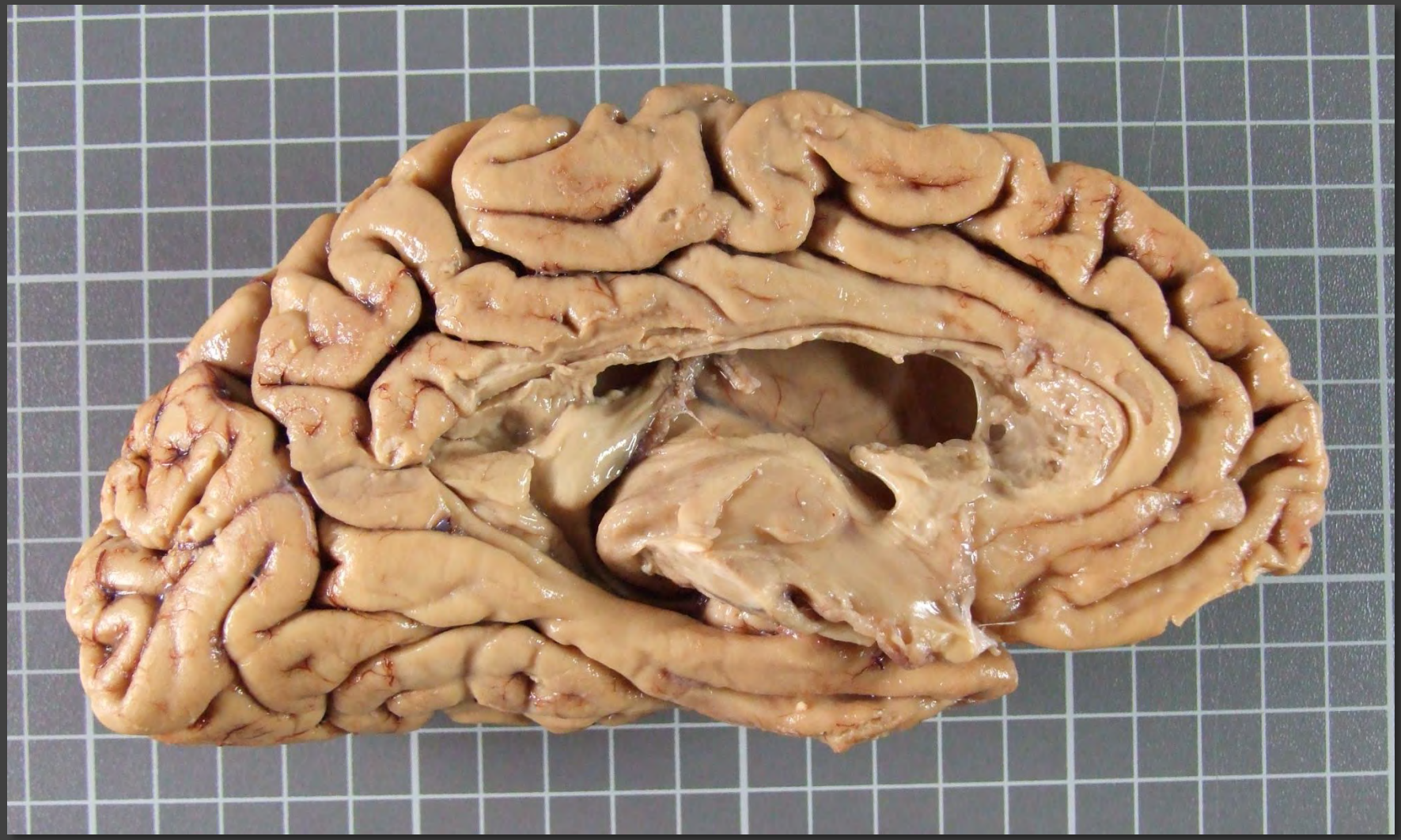

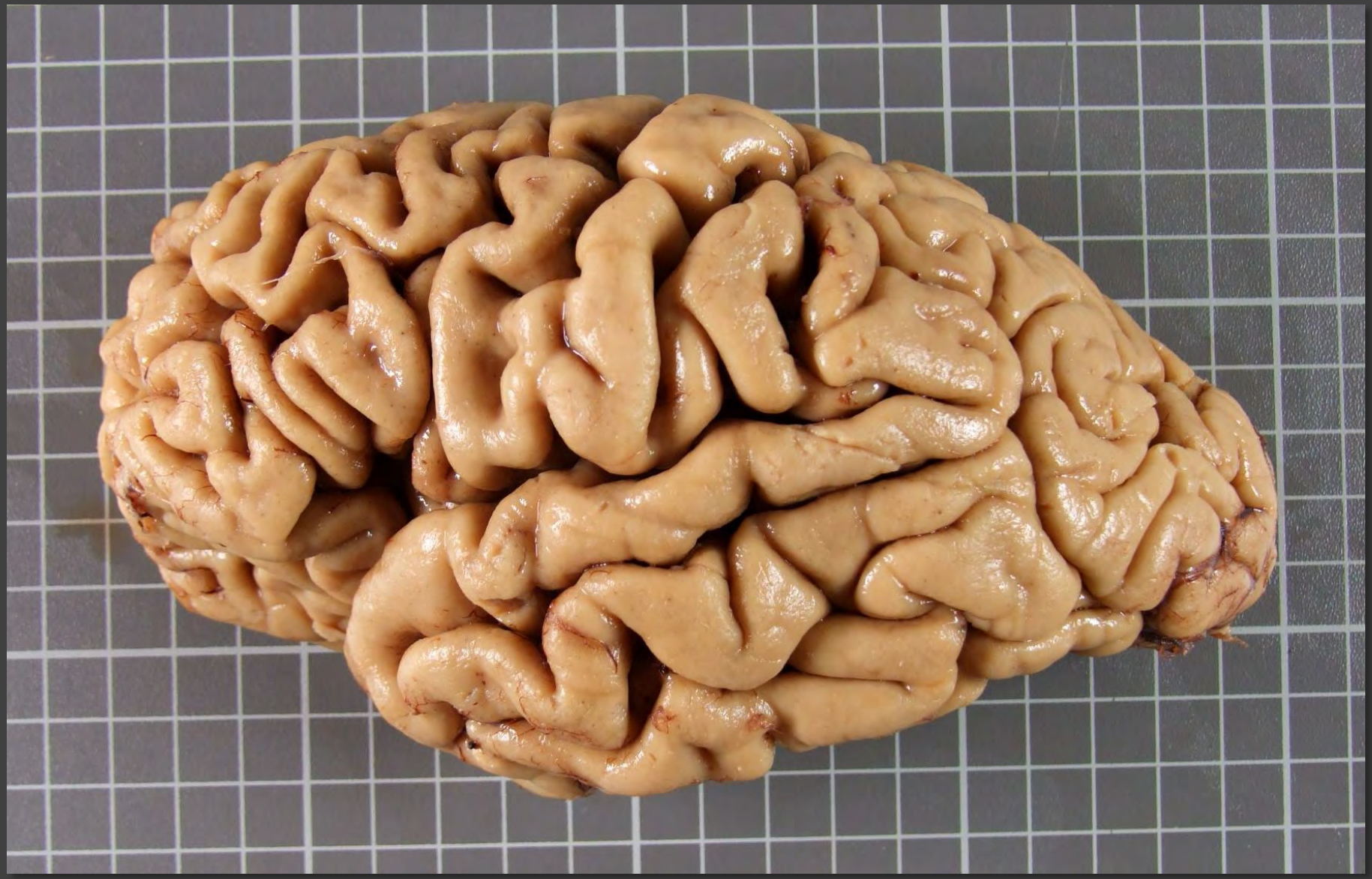

Degeneración lobar frontotemporal

Inmunohx.: TDP-43

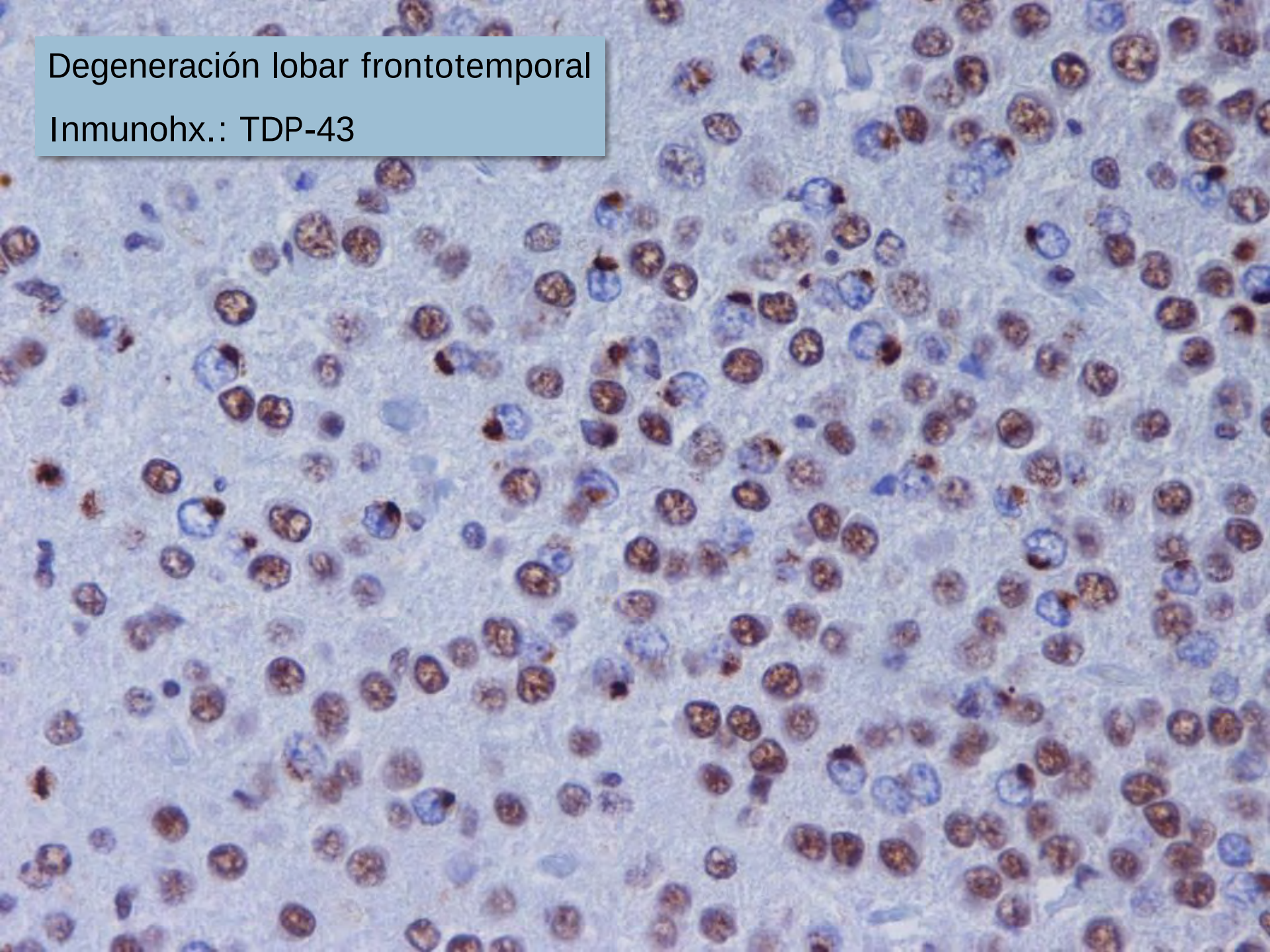

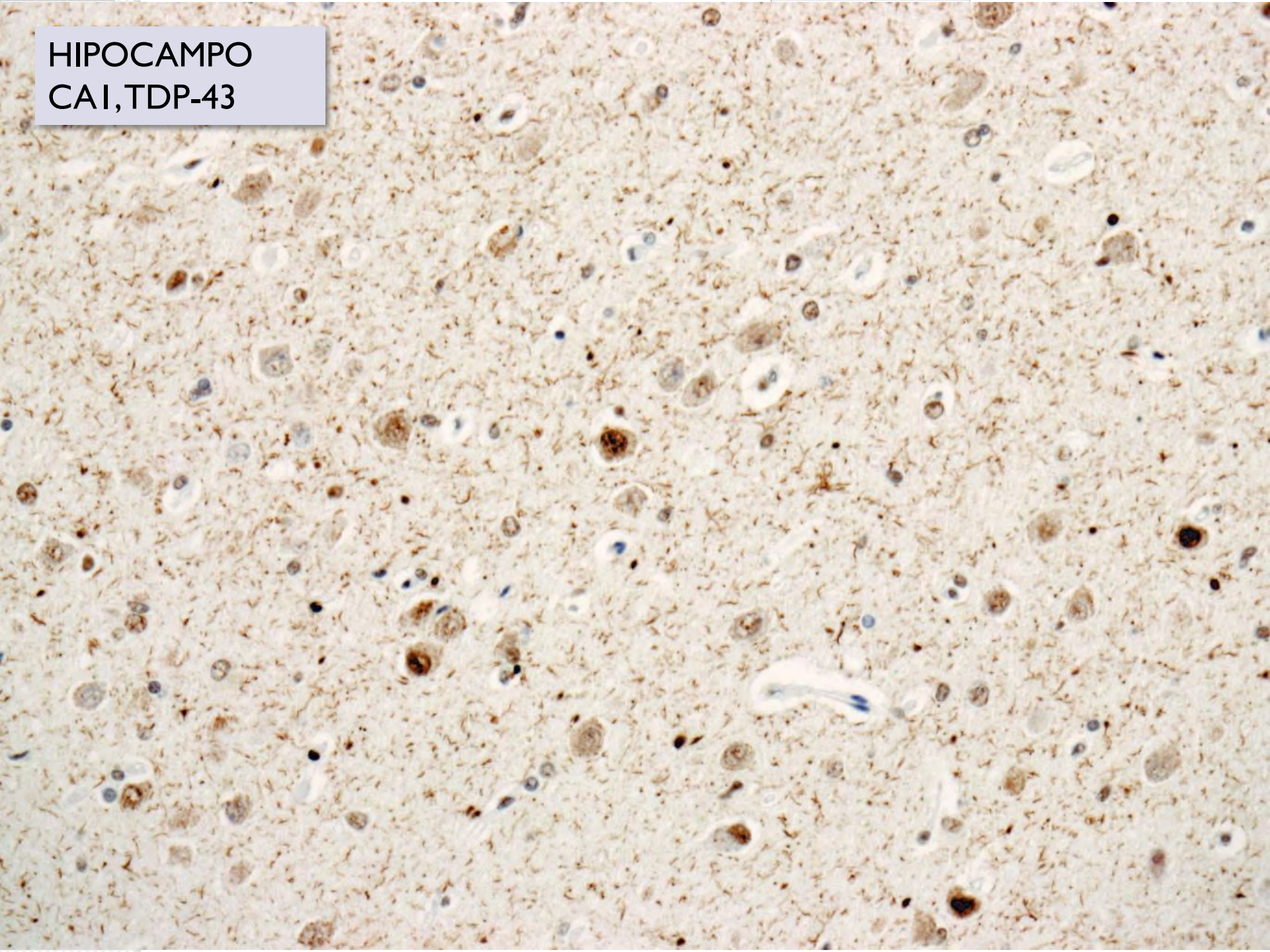
HIPOCAMPO
CA1, TDP-43

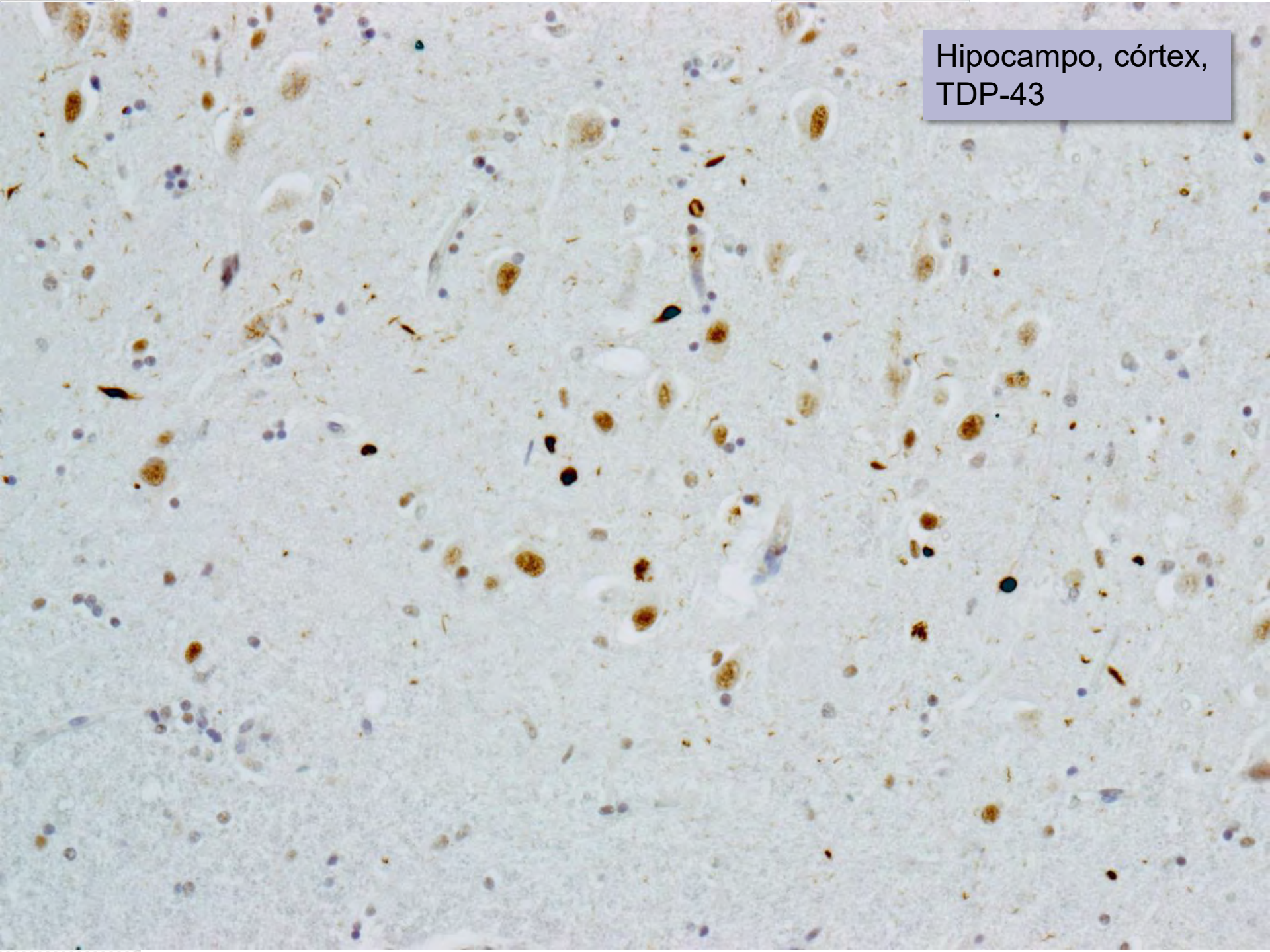
Hipocampo, córtex,
TDP-43

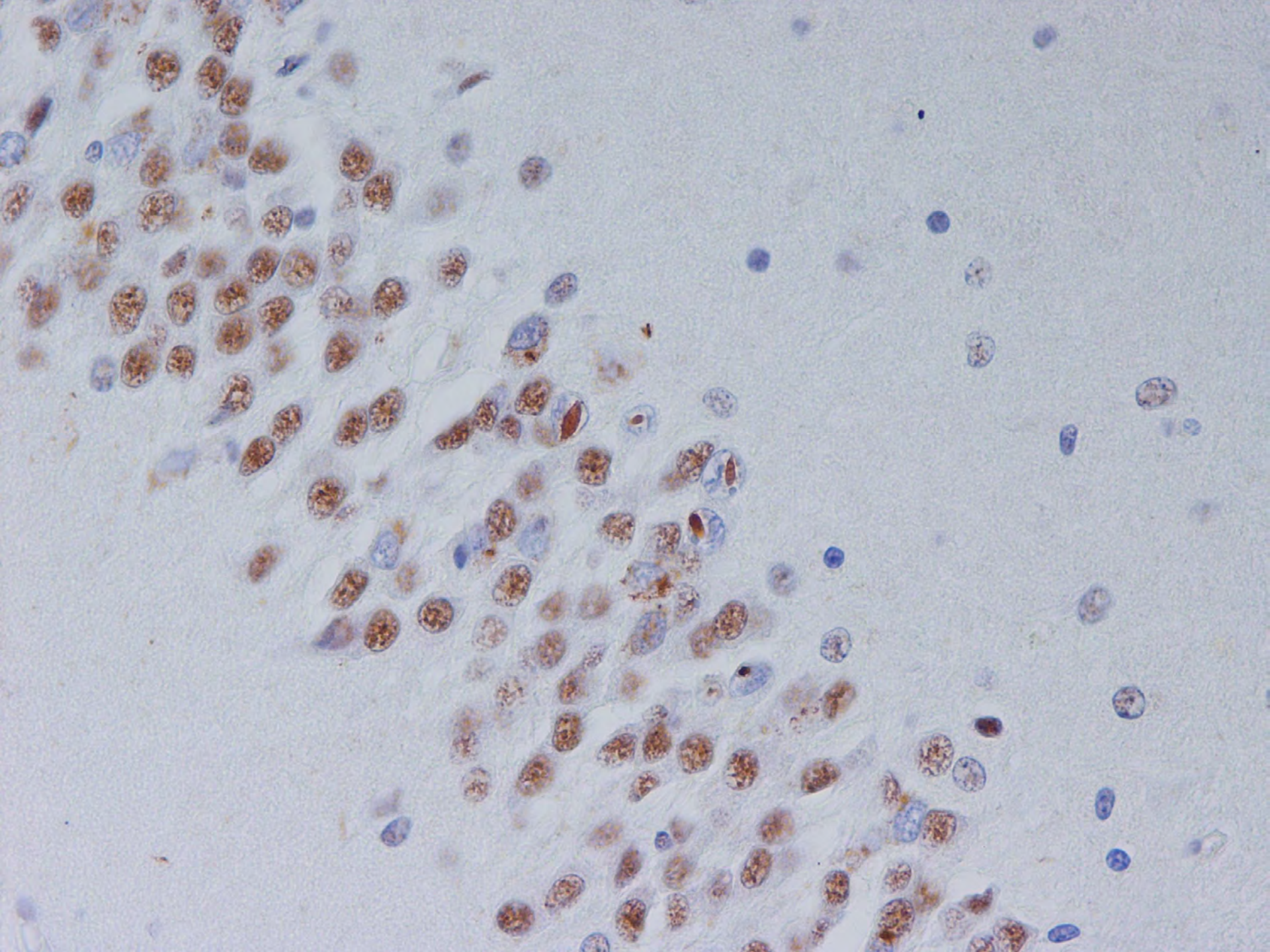

Table 1 Proposed new classification system for FTLD-TDP pathology, compared with existing systems

New system	Mackenzie et al. [7]	Sampathu et al. [11]	Cortical pathology	Common phenotype	Associated genetic defects
Type A	Type 1	Type 3	Many NCI Many short DN Predominantly layer 2	bvFTD PNFA	*GRN* mutations
Type B	Type 3	Type 2	Moderate NCI Few DN All layers	bvFTD MND with FTD	Linkage to chromosome 9p
Type C	Type 2	Type 1	Many long DN Few NCI Predominantly layer 2	SD bvFTD	
Type D	Type 4[a]	Type 4[a]	Many short DN Many lentiform NII Few NCI All layers	Familial IBMPFD	*VCP* mutations

bvFTD behavioural variant frontotemporal dementia, *DN* dystrophic neurites, *GRN* progranulin gene, *IBMPFD* inclusion body myopathy with Paget's disease of bone and frontotemporal dementia, *MND* motor neuron disease, *NCI* neuronal cytoplasmic inclusions, *NII* neuronal intranuclear inclusions, *PNFA* progressive non-fluent aphasia, *SD* semantic dementia, *VCP* valosin-containing protein gene

[a] Described subsequently by Forman et al. [4]

Acta Neuropathol (2011) 122:111–113

Rohrer JD et al. *Neurology*® 2010;75:2204-2211

Sampathu

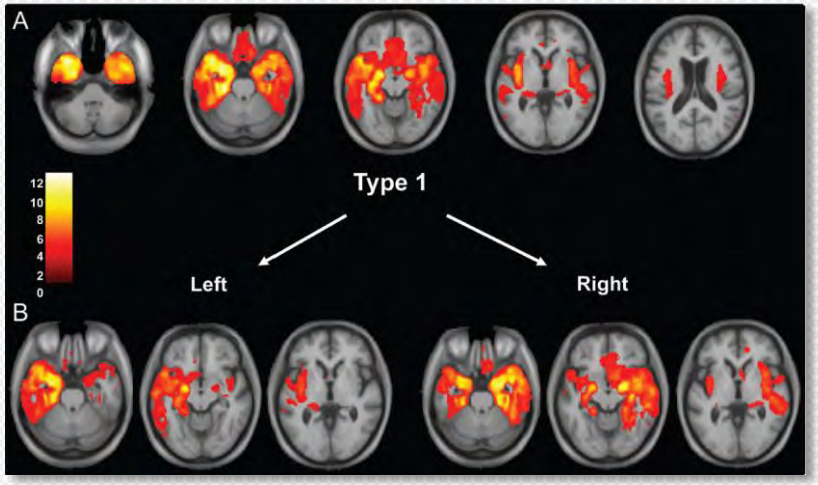

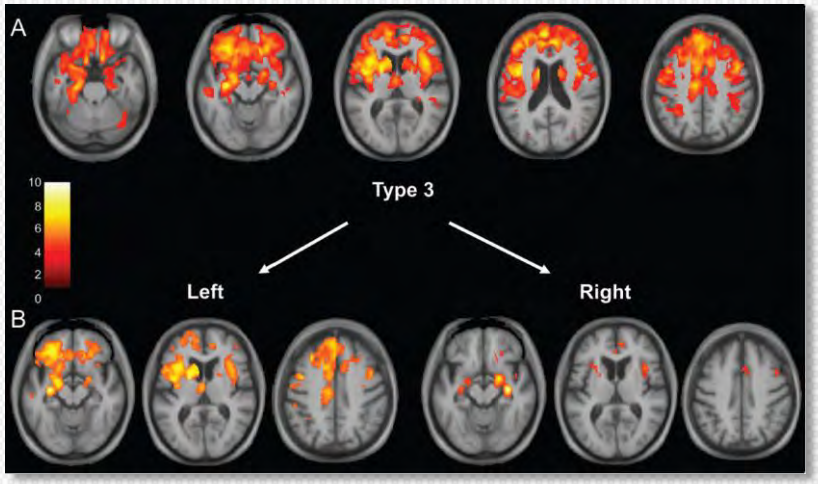

Tipo 1: 9/9 SD
Atrofia asimétrica del lóbulo temporal anterior (predominio I o D), con afectación de córtex órbitofrontal e insular.

Tipo 2: no APP
Atrofia relativamente simétrica del córtex temporal medial, prefrontal medial, órbitofrontal e insular

Tipo 3: 3/10 PNFA
Atrofia asimétrica de áreas dorsales de córtex frontal, temporal y parietal.

Whitwell JL et al. Neurology® 2010;75:2212-2220

Sampathu

Mackenzie

Tipo 3

Tipo 1

Tipo 2

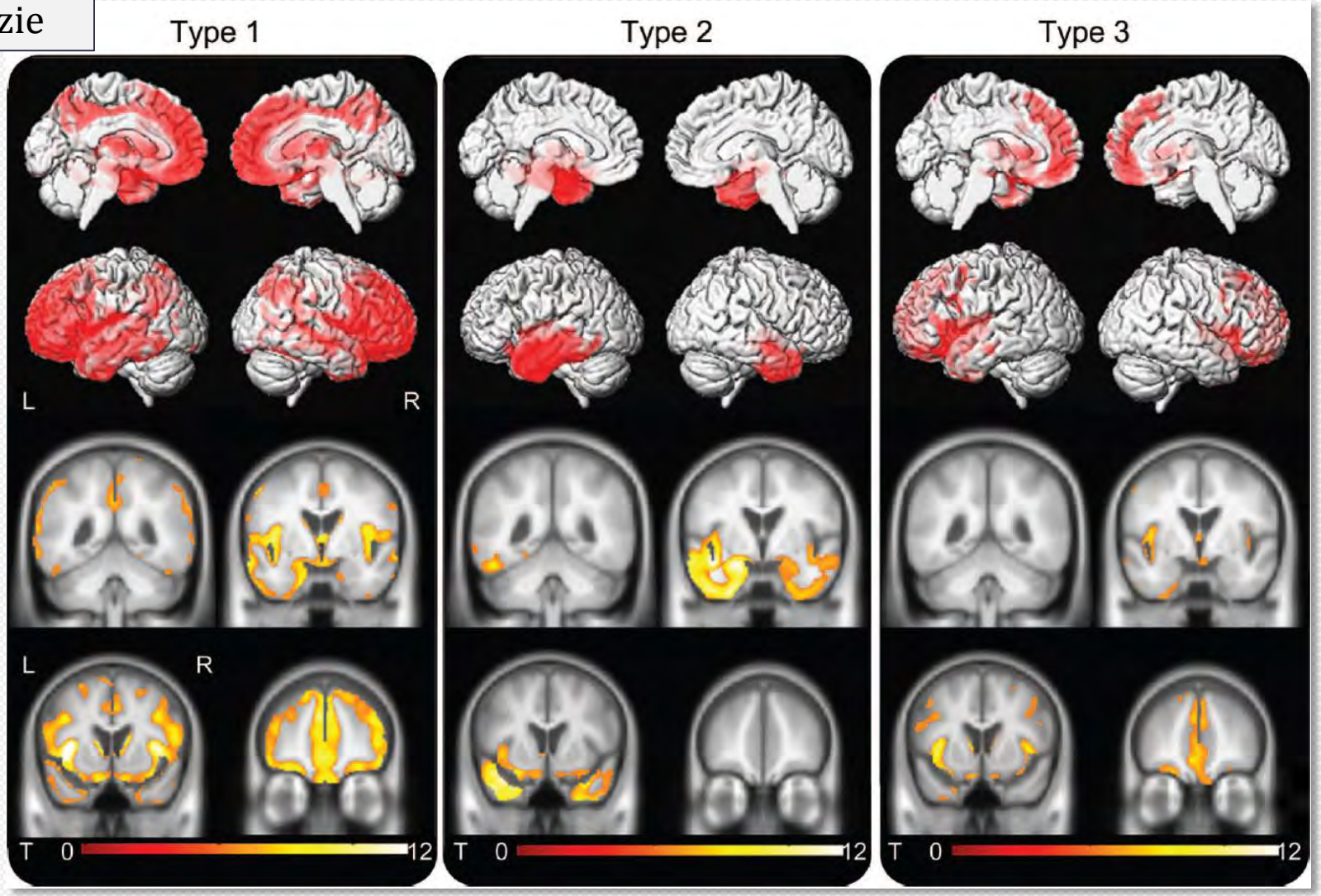

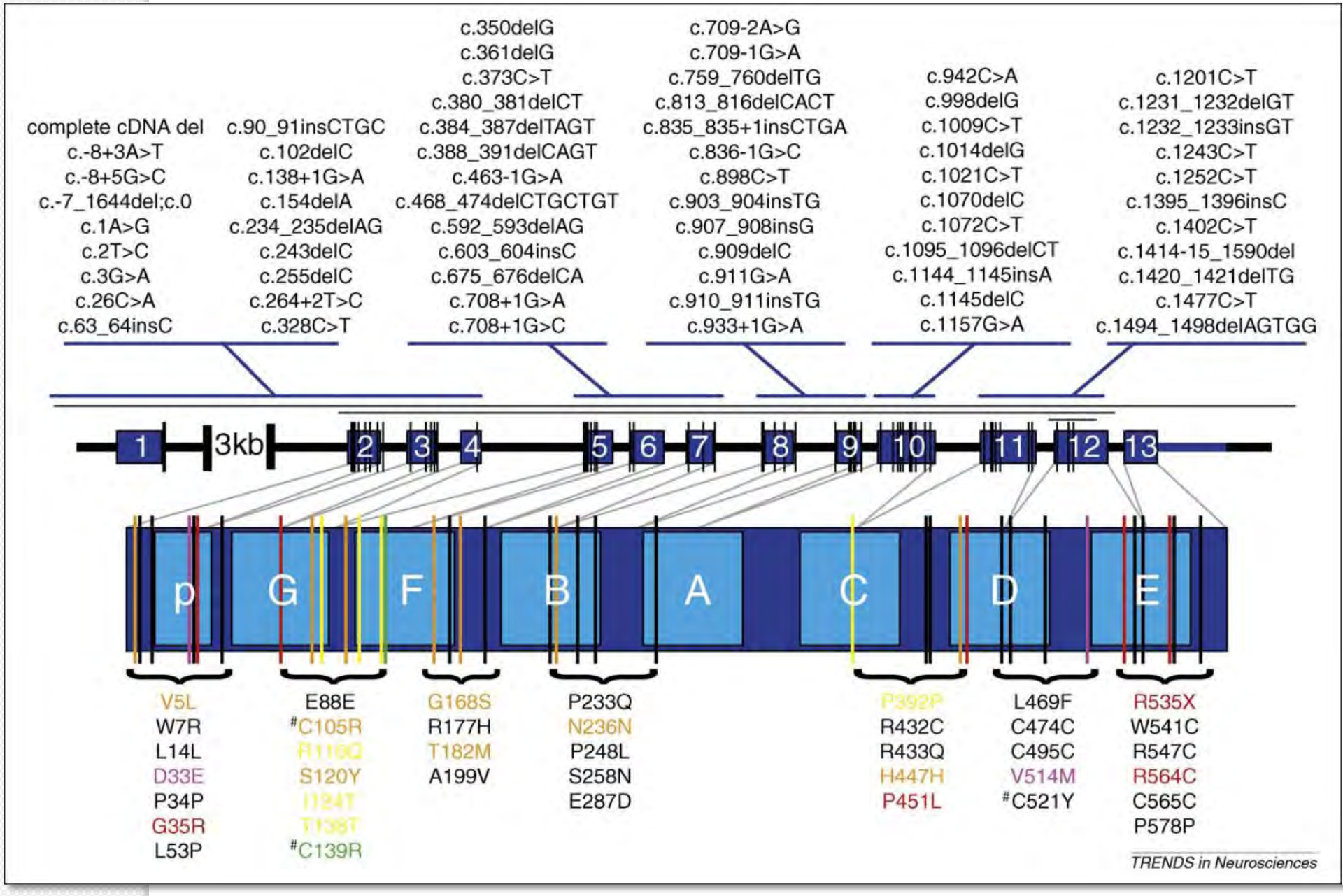
complete cDNA del
c.-8+3A>T
c.-8+5G>C
c.-7_1644del;c.0
c.1A>G
c.2T>C
c.3G>A
c.26C>A
c.63_64insC
c.90_91insCTGC
c.102delC
c.138+1G>A
c.154delA
c.234_235delAG
c.243delC
c.255delC
c.264+2T>C
c.328C>T
c.350delG
c.361delG
c.373C>T
c.380_381delCT
c.384_387delTAGT
c.388_391delCAGT
c.463-1G>A
c.468_474delCTGCTGT
c.592_593delAG
c.603_604insC
c.675_676delCA
c.708+1G>A
c.708+1G>C
c.709-2A>G
c.709-1G>A
c.759_760delTG
c.813_816delCACT
c.835_835+1insCTGA
c.836-1G>C
c.898C>T
c.903_904insTG
c.907_908insG
c.909delC
c.911G>A
c.910_911insTG
c.933+1G>A
c.942C>A
c.998delG
c.1009C>T
c.1014delG
c.1021C>T
c.1070delC
c.1072C>T
c.1095_1096delCT
c.1144_1145insA
c.1145delC
c.1157G>A
c.1201C>T
c.1231_1232delGT
c.1232_1233insGT
c.1243C>T
c.1252C>T
c.1395_1396insC
c.1402C>T
c.1414-15_1590del
c.1420_1421delTG
c.1477C>T
c.1494_1498delAGTGG
1
3kb
2
3
4
5
6
7
8
9
10
11
12
13
p
G
F
B
A
C
D
E
V5L
W7R
L14L
D33E
P34P
G35R
L53P
E88E
#C105R
R110Q
S120Y
I124T
T138T
#C139R
G168S
R177H
T182M
A199V
P233Q
N236N
P248L
S258N
E287D
P392P
R432C
R433Q
H447H
P451L
L469F
C474C
C495C
V514M
#C521Y
R535X
W541C
R547C
R564C
C565C
P578P
TRENDS in Neurosciences

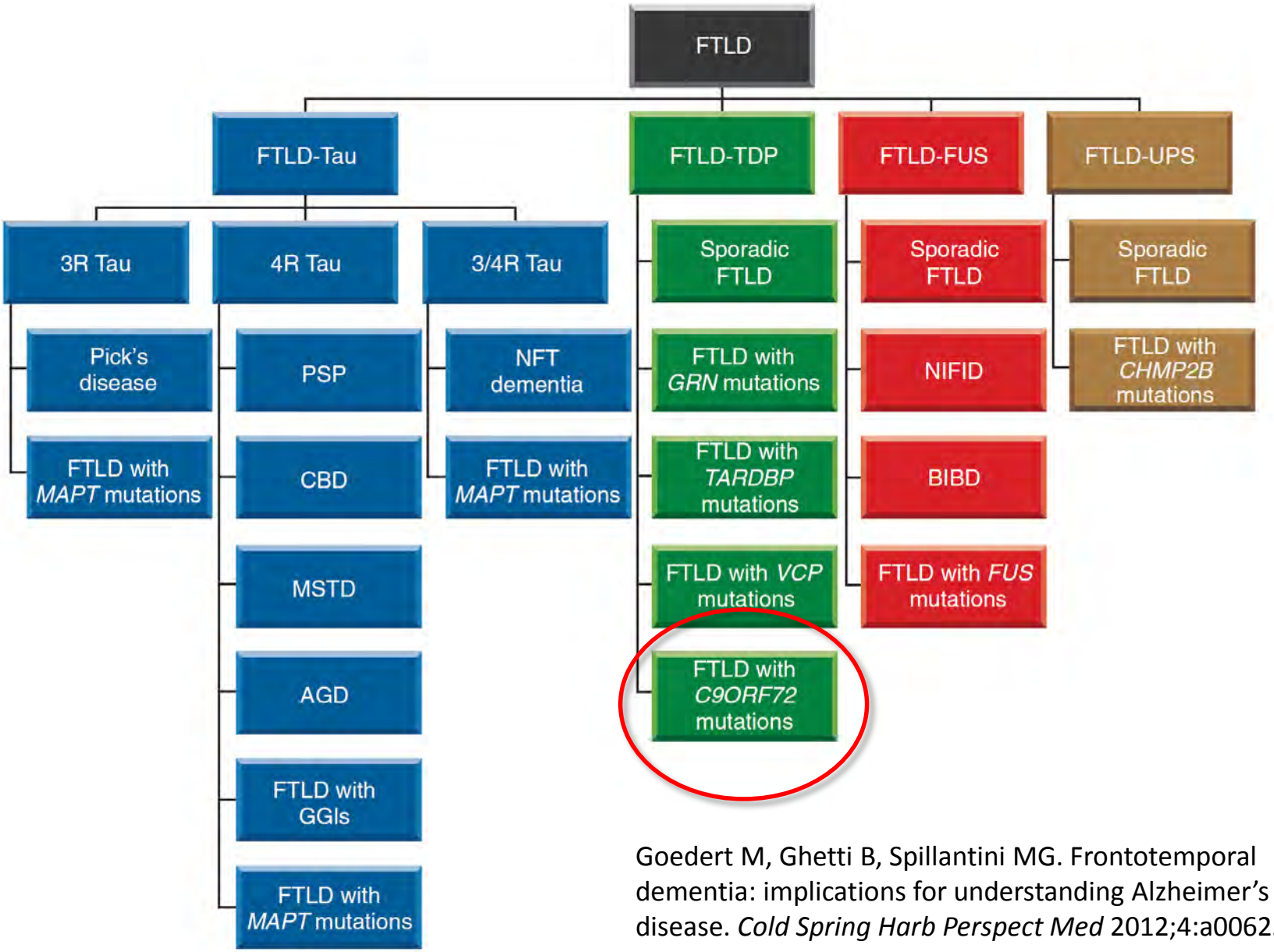

Goedert M, Ghetti B, Spillantini MG. Frontotemporal dementia: implications for understanding Alzheimer's disease. *Cold Spring Harb Perspect Med* 2012;4:a006254

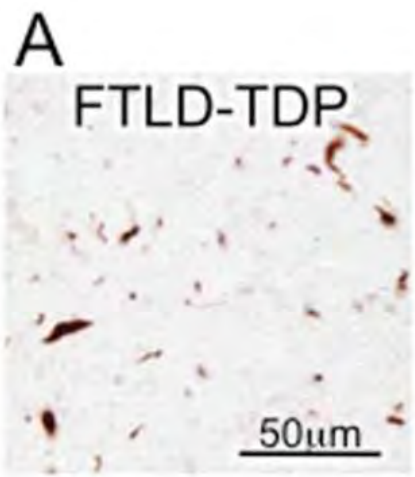
A
FTLD-TDP
50µm

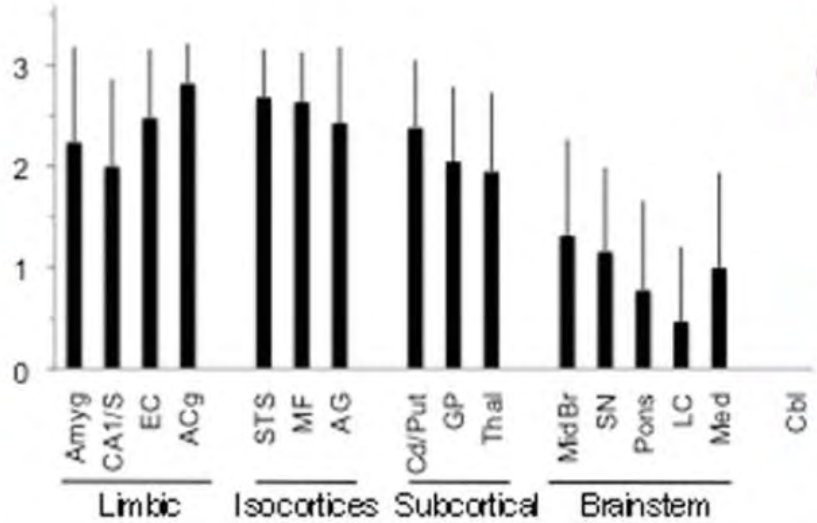
3
2
1
0
Amyg
CA1/S
EC
ACg
STS
MF
AG
Cd/Put
GP
Thal
MidBr
SN
Pons
LC
Med
Cbl
Limbic
Isocortices
Subcortical
Brainstem

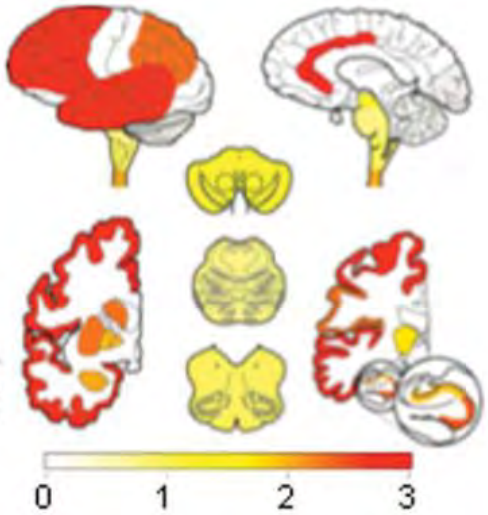
0
1
2
3

ALS motor phenotype heterogeneity, focality, and spread

Deconstructing motor neuron degeneration

Neurology® 2009;73:805-811

John M. Ravits, MD, FAAN
Albert R. La Spada, MD, PhD

Figure An idealized model of the natural history of amyotrophic lateral sclerosis (ALS) based upon focality and contiguous spread

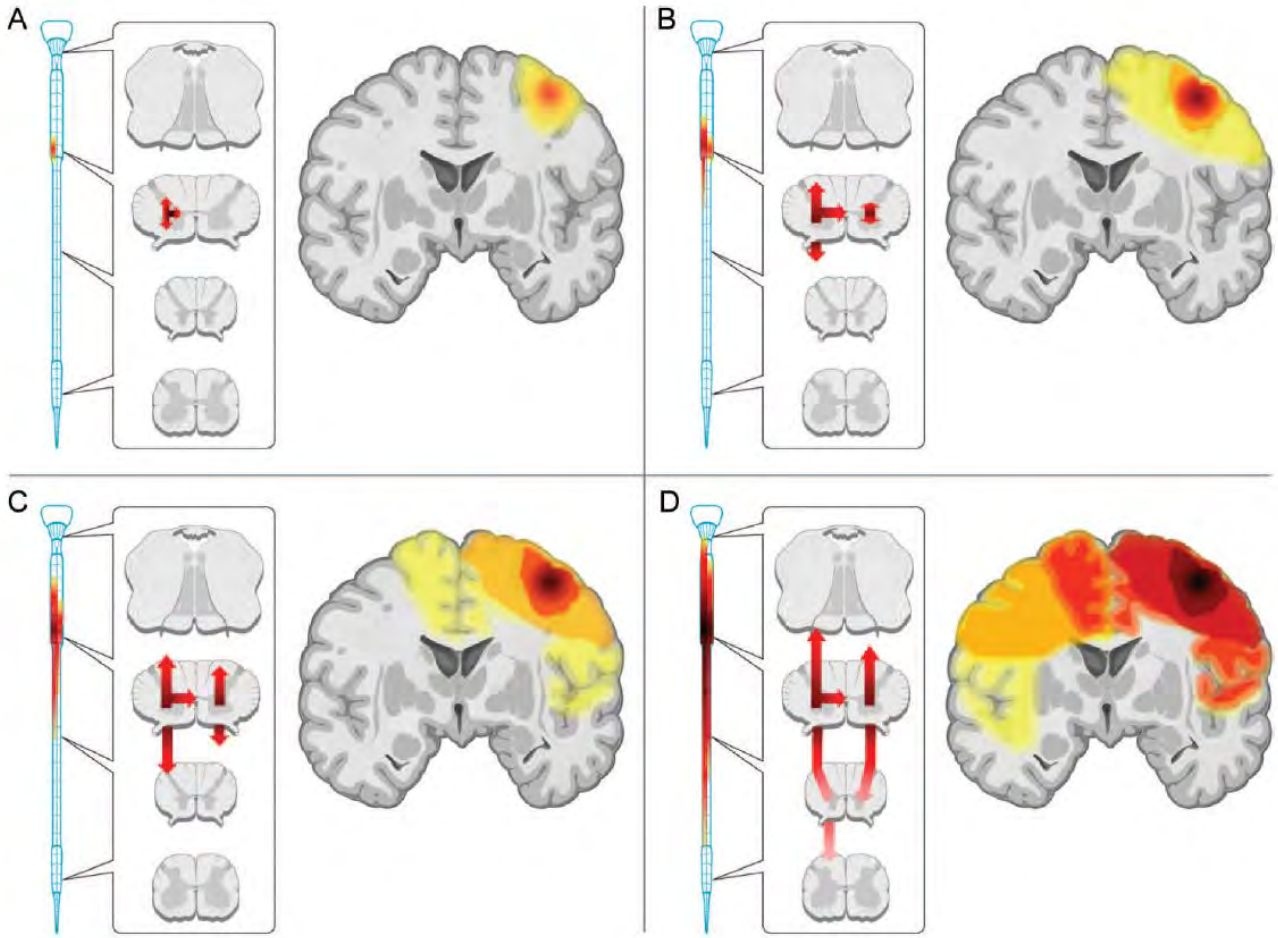

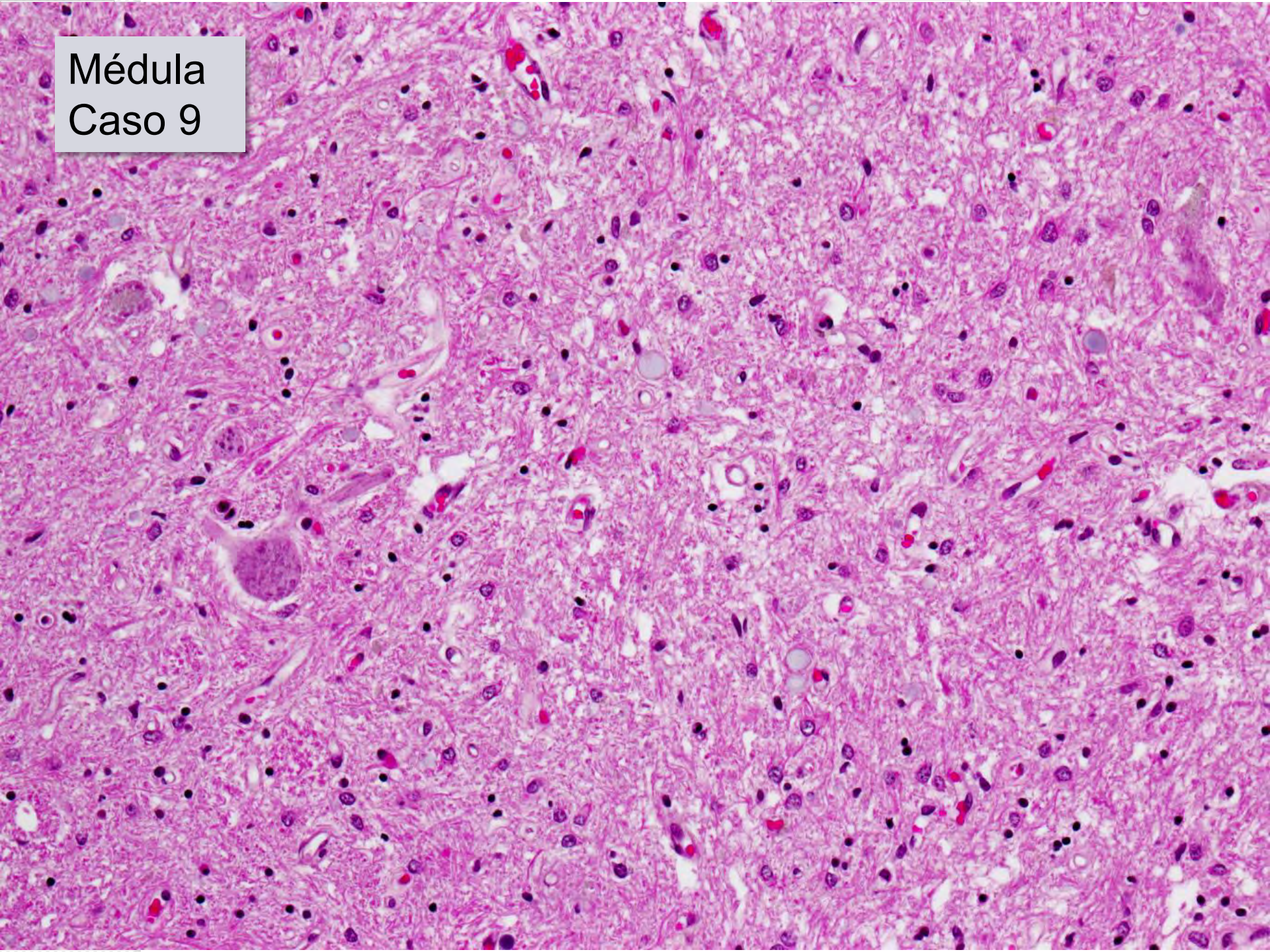
Médula
Caso 9

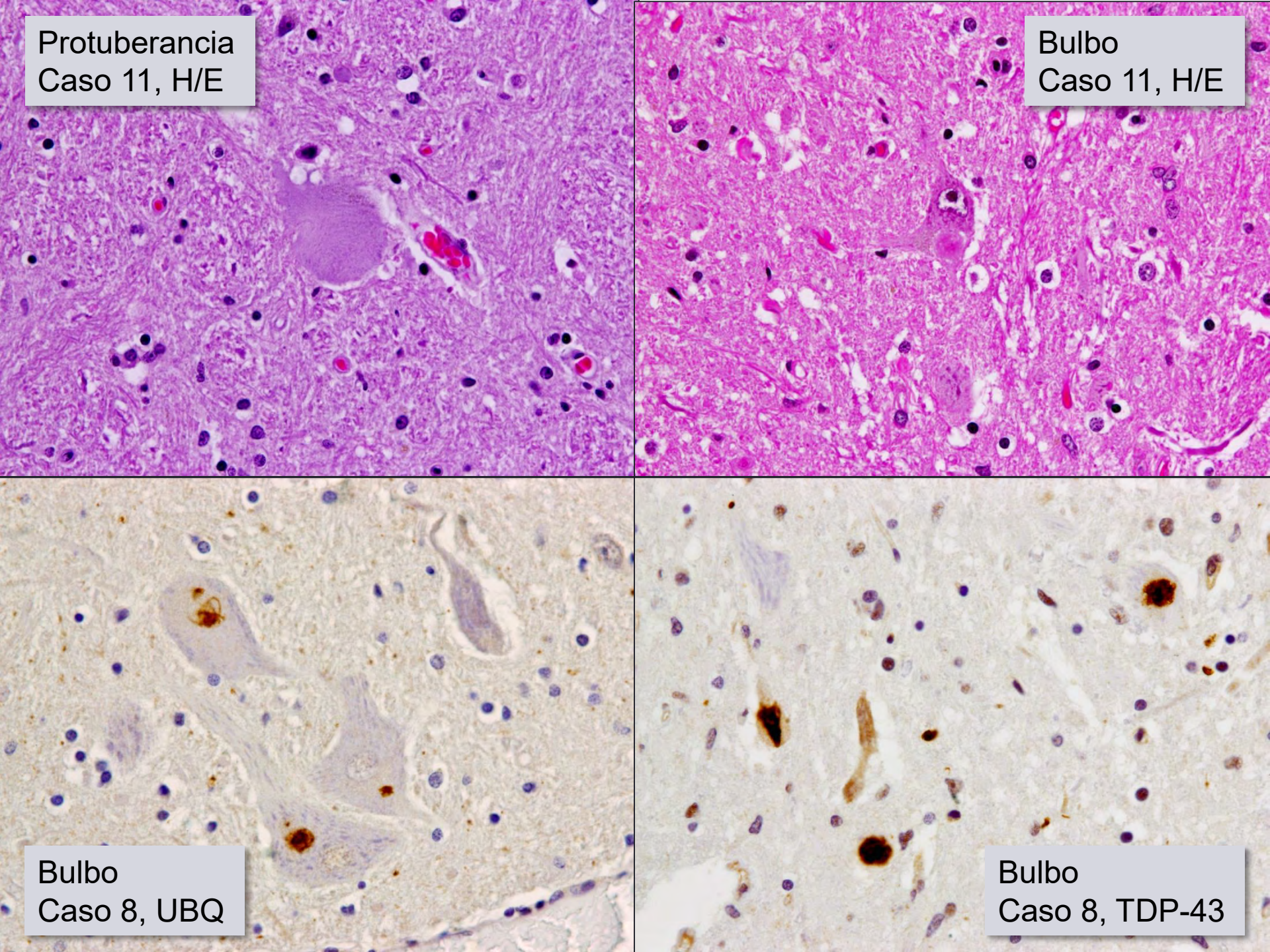
Protuberancia
Caso 11, H/E
Bulbo
Caso 11, H/E
Bulbo
Caso 8, UBQ
Bulbo
Caso 8, TDP-43

TDP-43

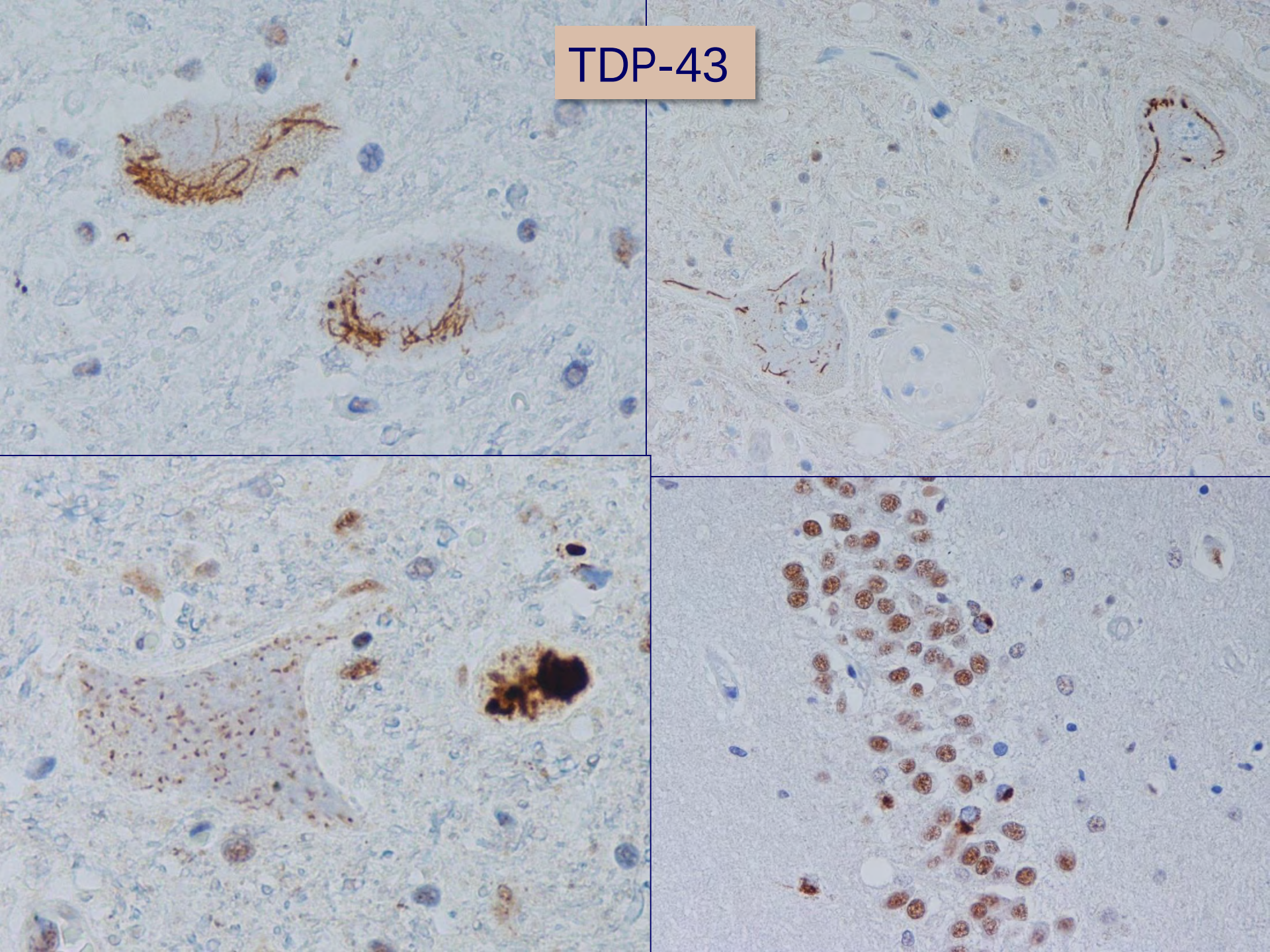

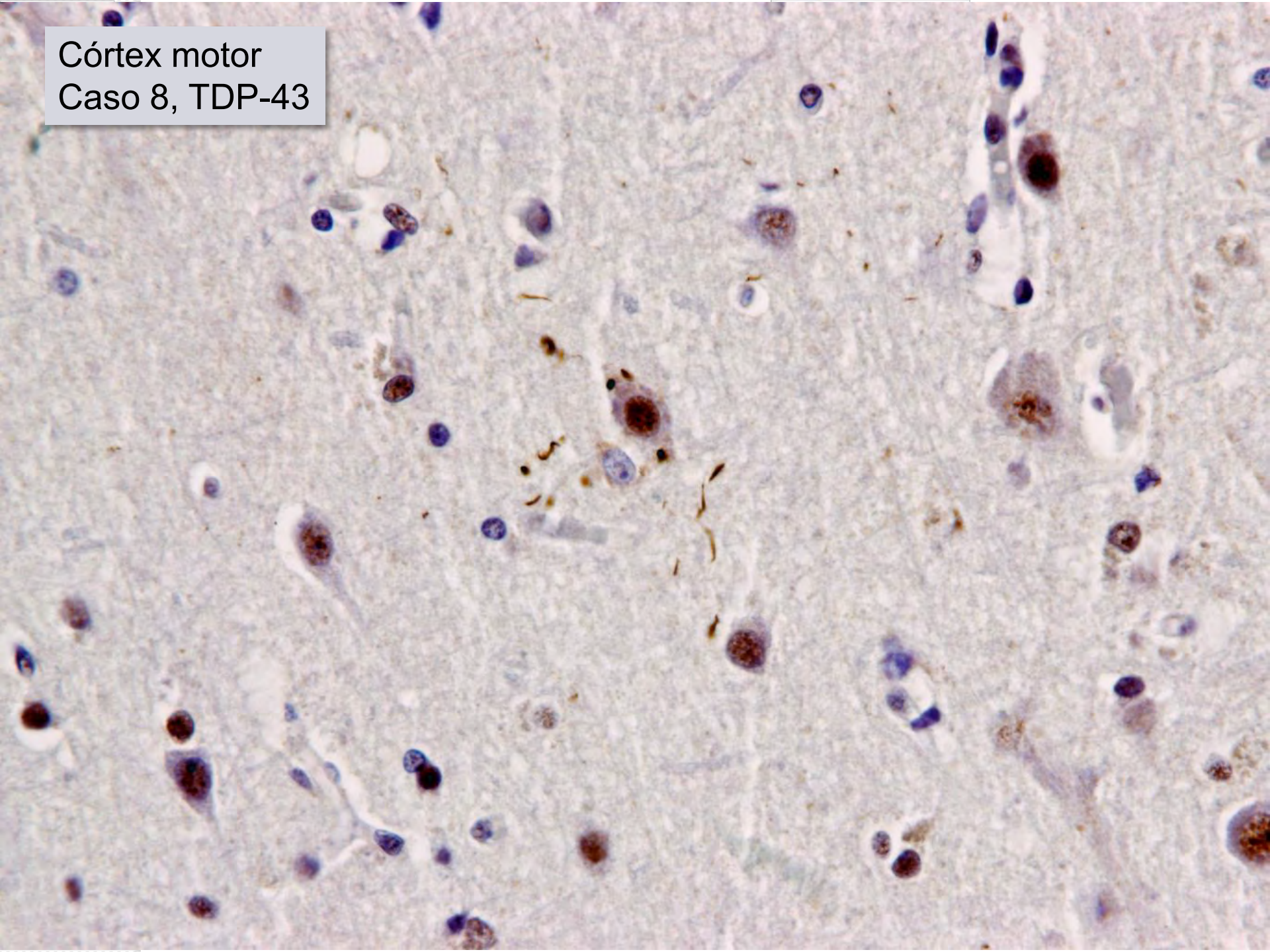
Córtex motor
Caso 8, TDP-43

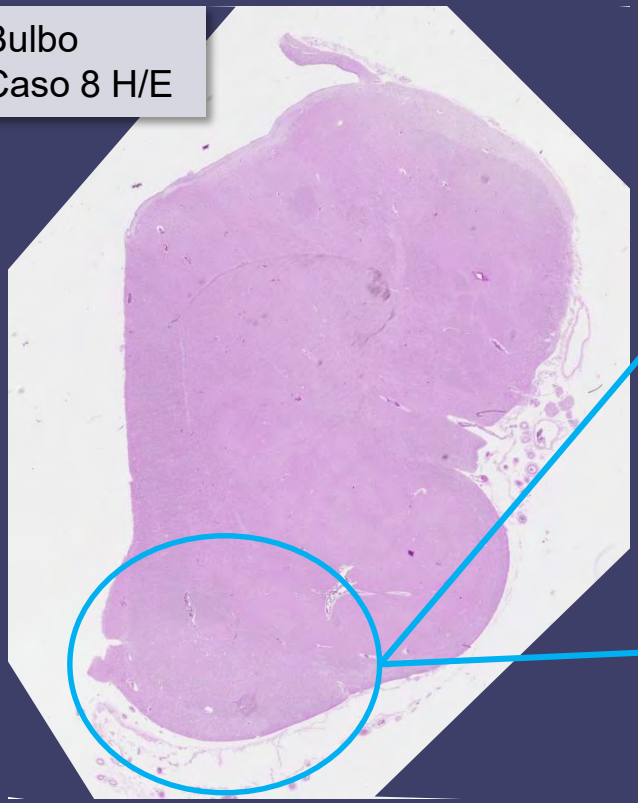
Bulbo
Caso 8 H/E

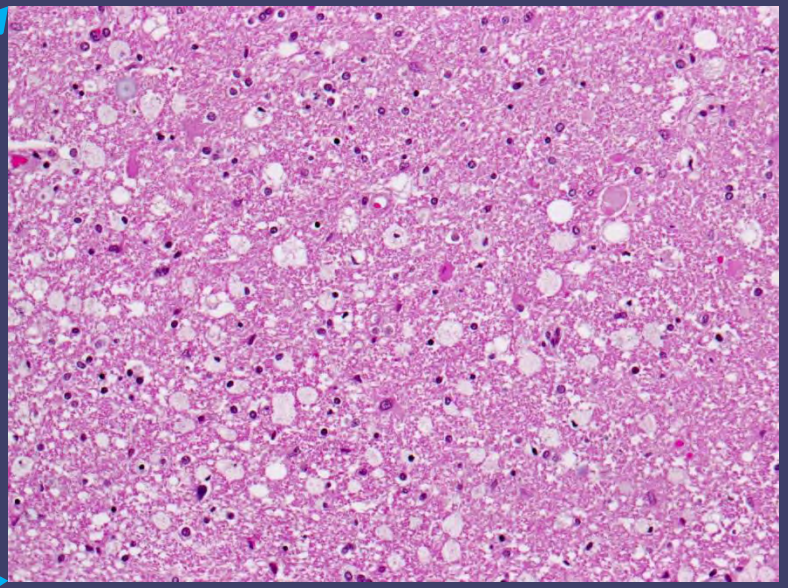

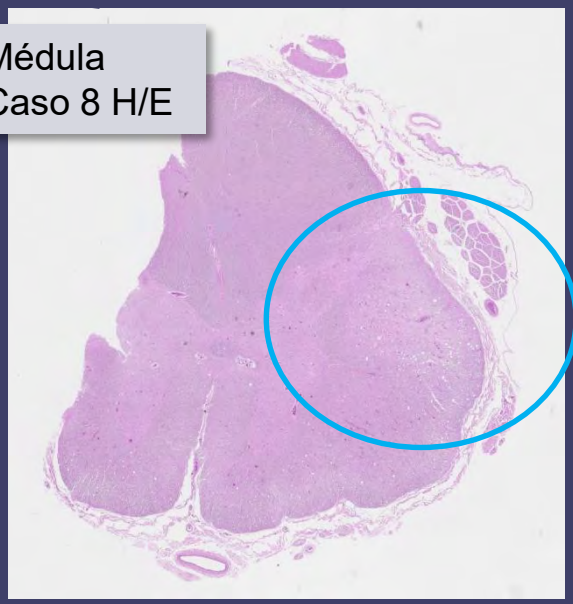
Médula
Caso 8 H/E

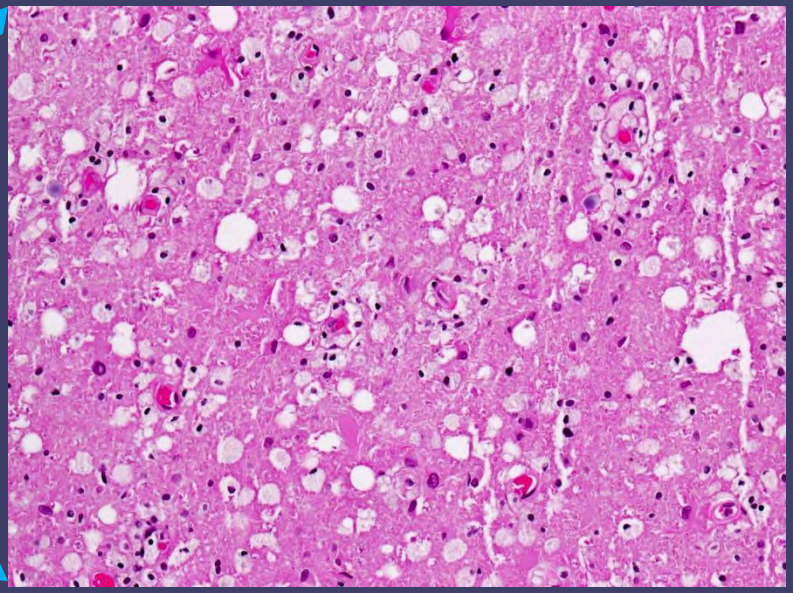

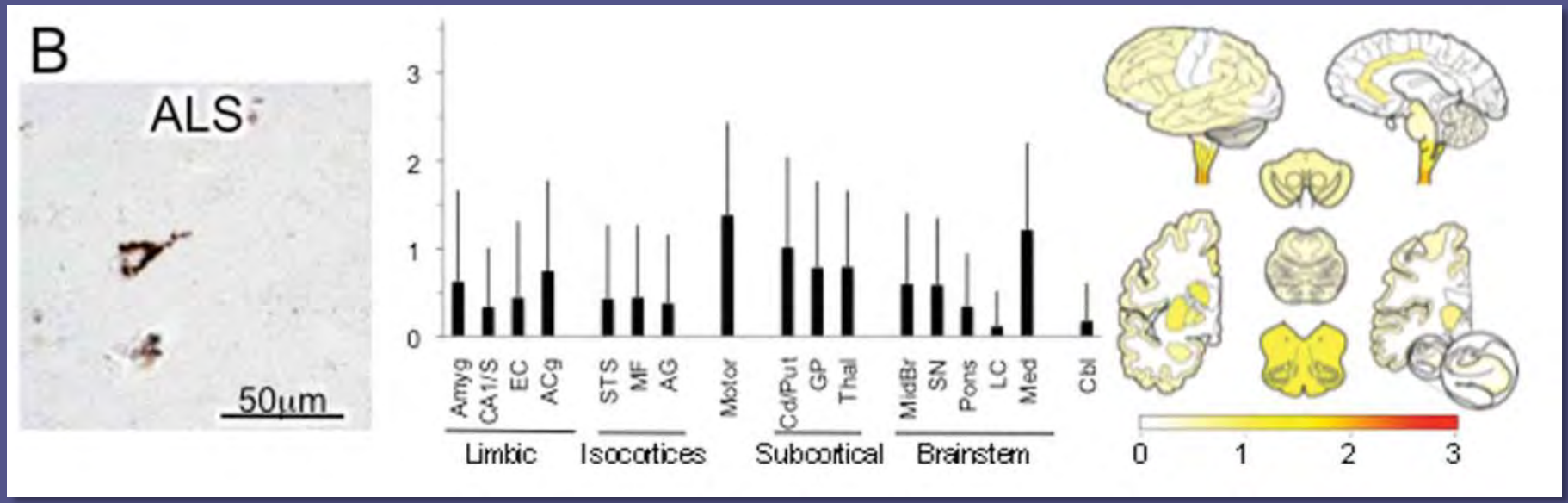
B
ALS
50µm
3
2
1
0
Amyg
CA1/S
EC
ACg
STS
MF
AG
Motor
Cd/Put
GP
Thal
MidBr
SN
Pons
LC
Med
Cbl
Limbic
Isocortices
Subcortical
Brainstem
0
1
2
3

Degeneración lobar frontotemporal FUS

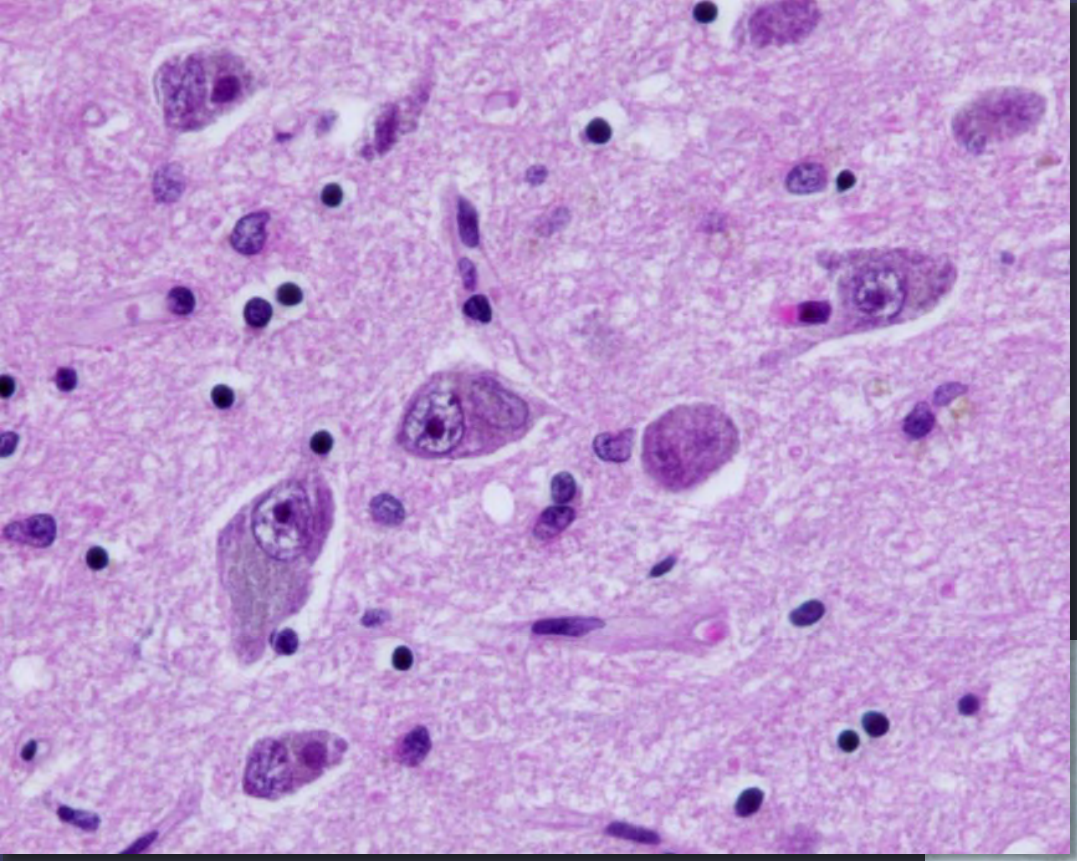

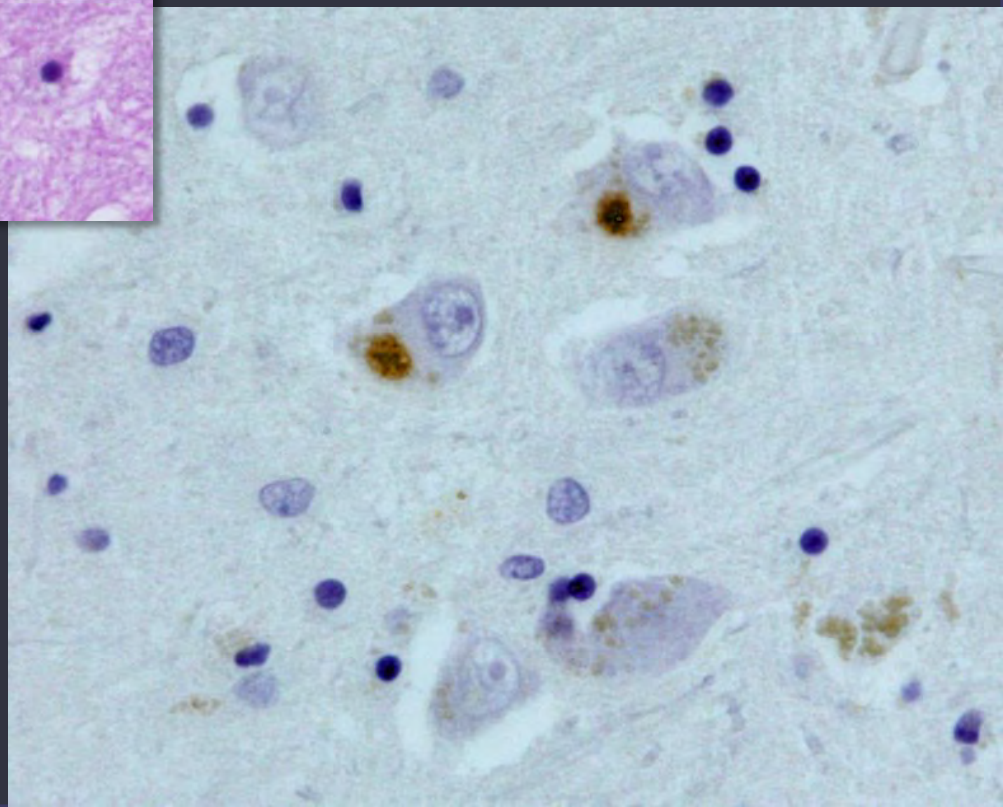

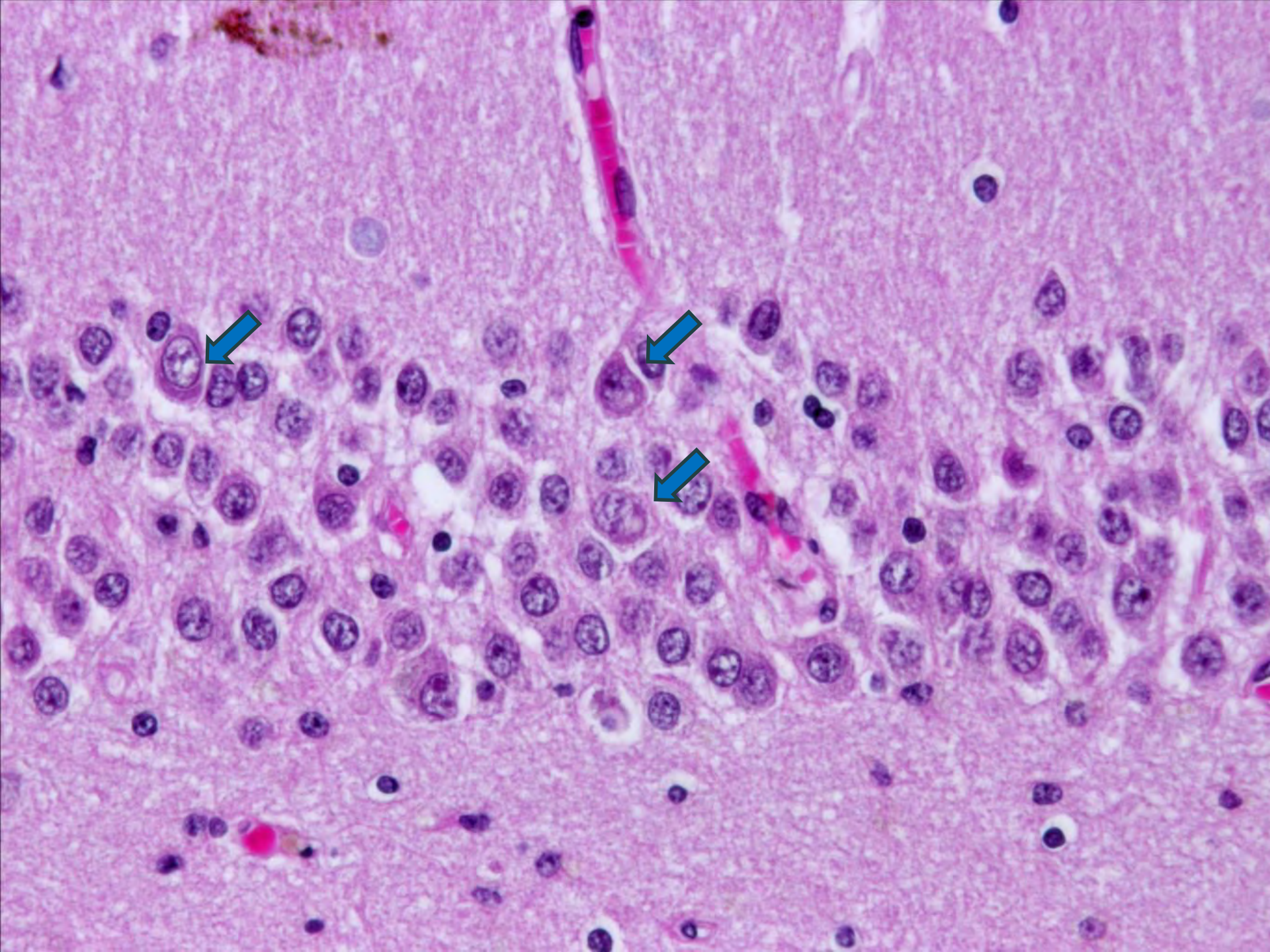

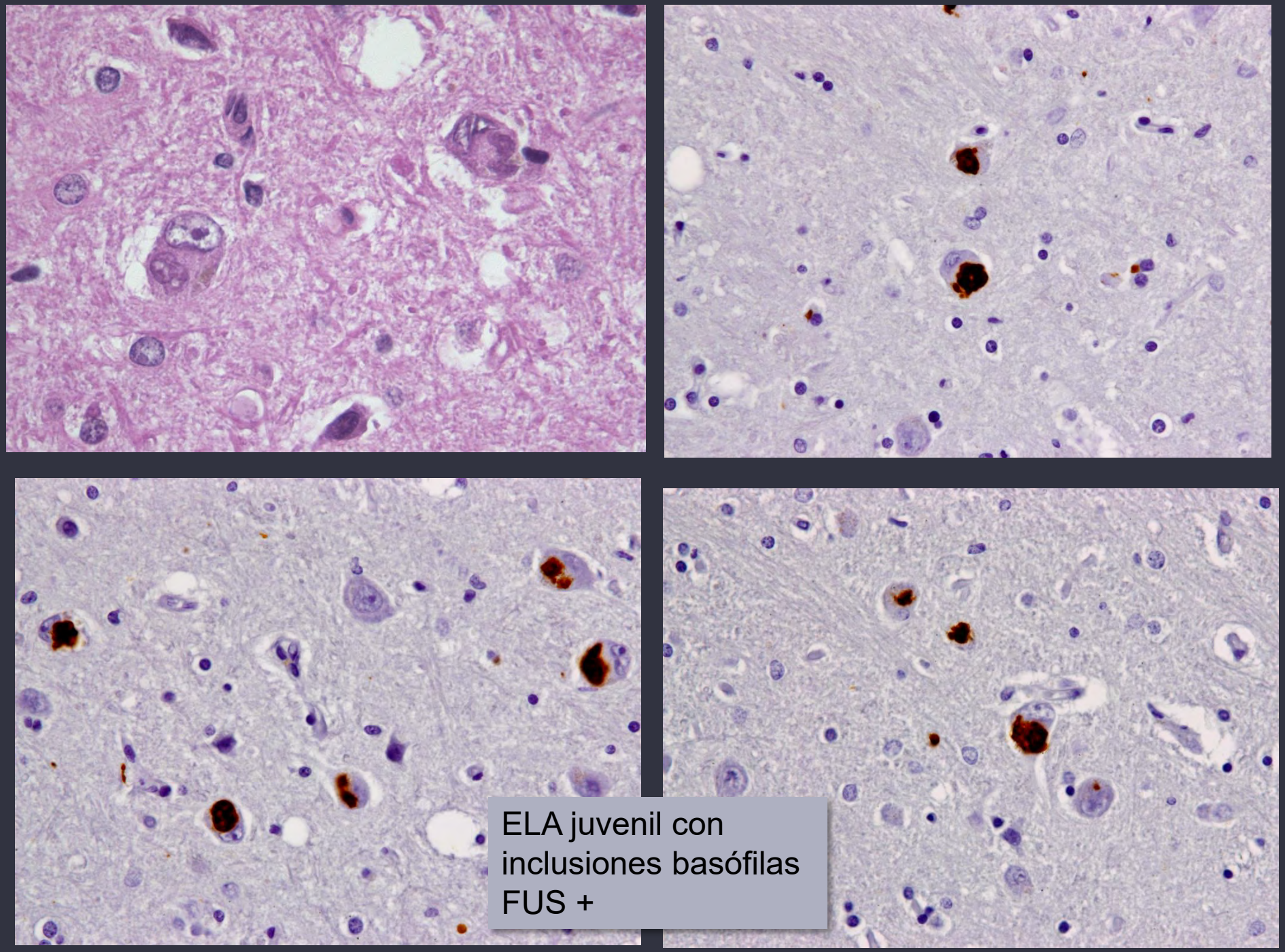

ELA juvenil con inclusiones basófilas FUS +

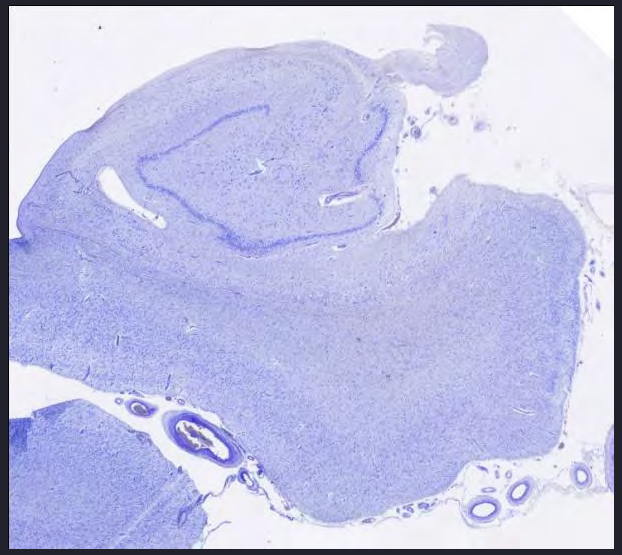

ESCLEROSIS DEL HIPOCAMPO

Pérdida neuronal y gliosis en sector CA1 del hipocampo y en subículum.

Prevalencia en pacientes con demencia: 2.8 – 13%.

En la mayoría de los casos asociada a otras patologías: DLFT-TDP, Alzheimer, taupatías, etc. Raramente se presenta aislada como demencia por esclerosis del hipocampo.

Inmunorreactividad neuronal a TDP-43 en >70% de los casos.

El alelo rs5848 T de *GRN* confiere riesgo para esclerosis del hipocampo in pacientes con Alzheimer.

Cuestiones previas:

- ¿Enfermedad o patología?
- ¿Probabilidad o certeza?
- ¿Lesiones específicas o inespecíficas?

TANTOS ESFUERZOS
Y LA CLAVE
Alzheimer Soria
cien
PUEDES
SER TÚ

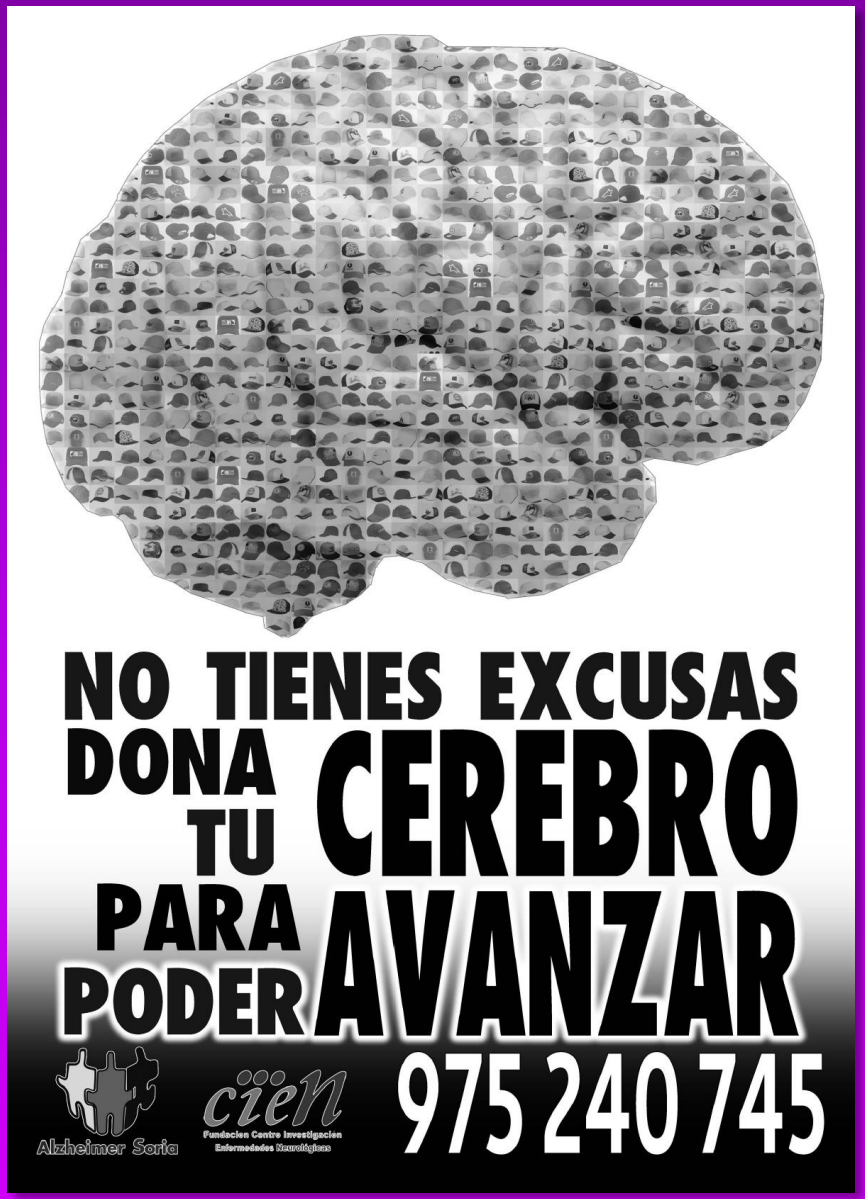
NO TIENES EXCUSAS
DONA TU CEREBRO
PARA PODER AVANZAR
Alzheimer Soria
cien
Fundacion Centro Investigacion
Enfermedades Neurologicas
975 240 745

Alzheimer Soria
cien
Fundacion Centro Investigacion
Enfermedades Neurologicas

¡Gracias!